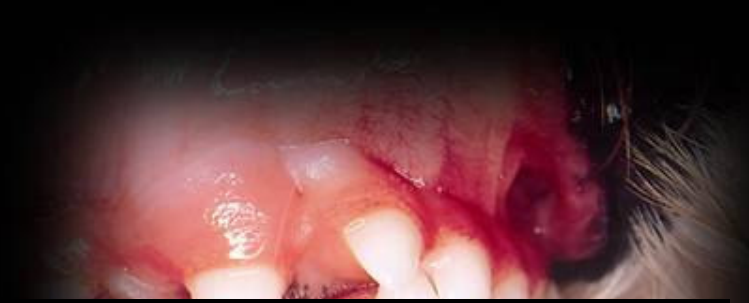
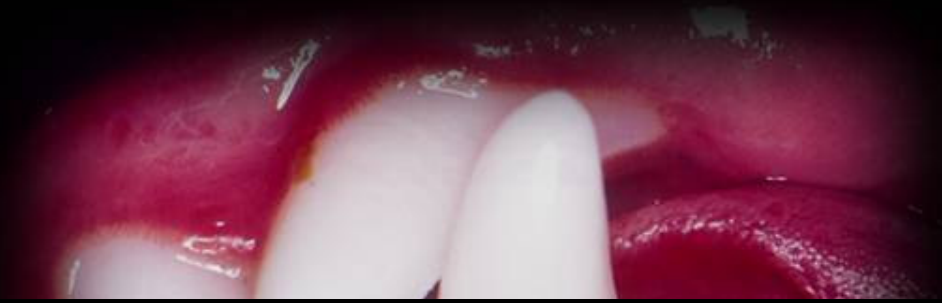


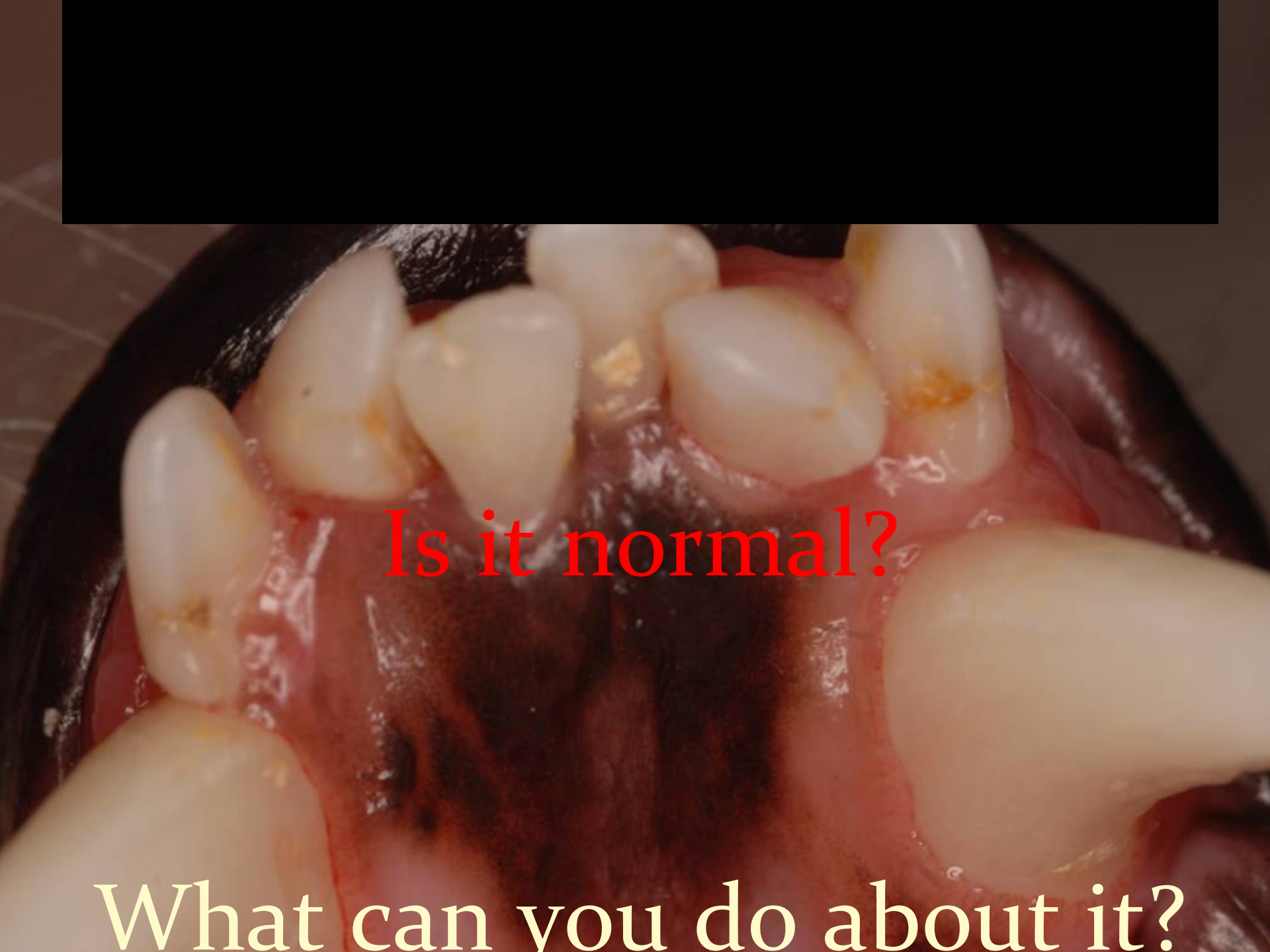5/8 N° R_S L F N_L € 7/8 R_S € —[®]

ORTHODONTICS



Jan Bellows DVM
Hometown Animal Hospital and Dental Clinic
Weston, Florida



Is it normal?

What can you do about it?

OCCLUSION

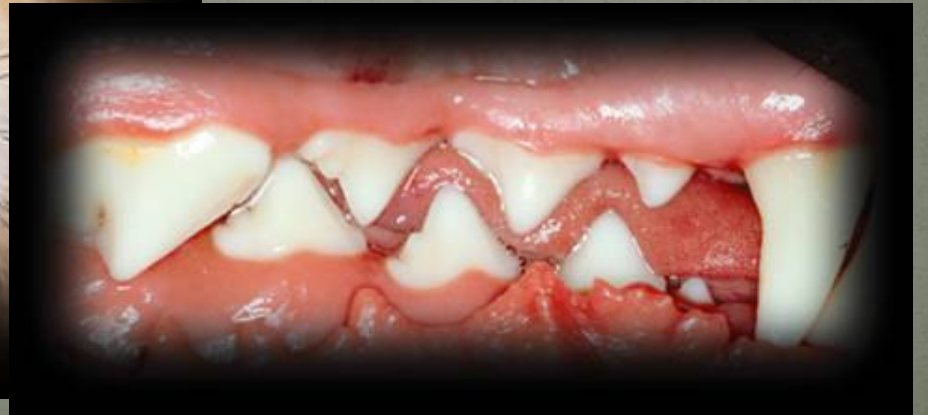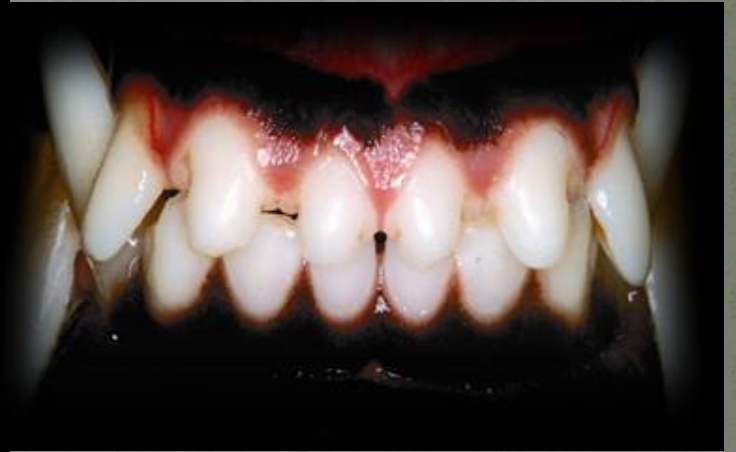VS.

MALOCCLUSION

OCCLUSION

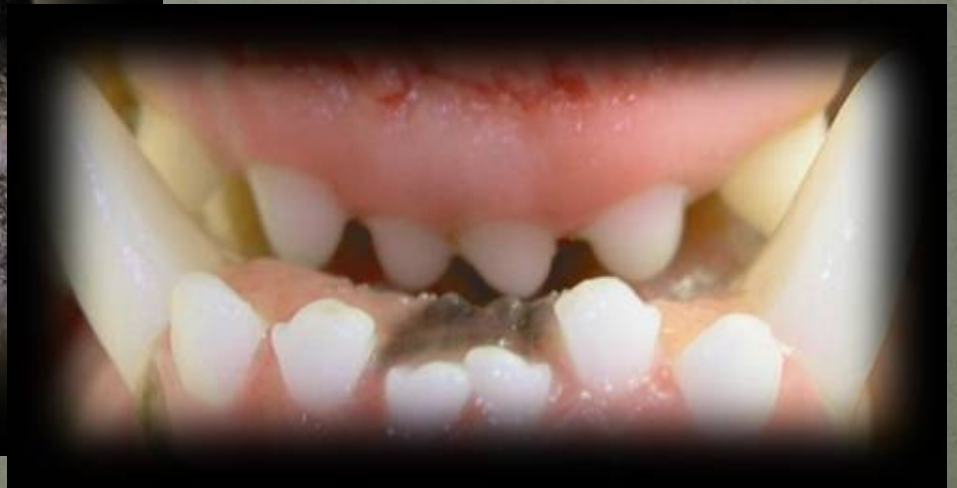
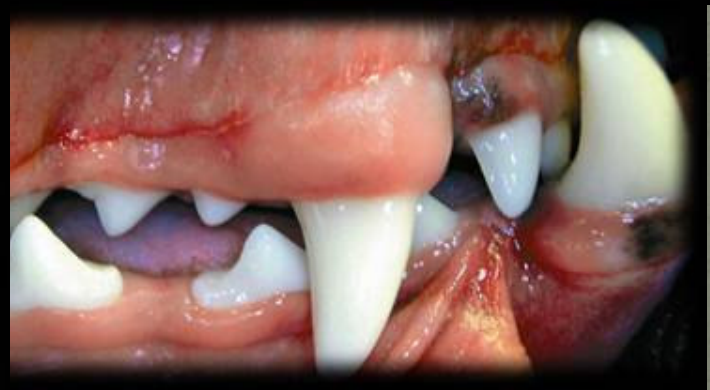
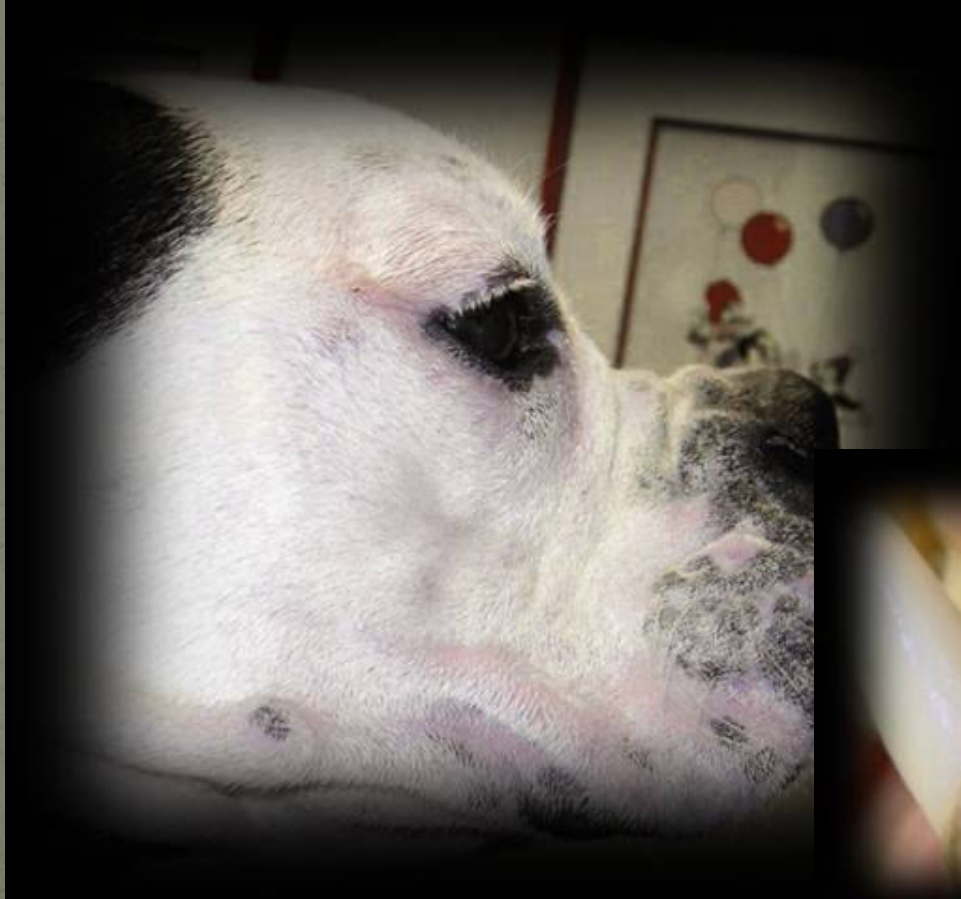Mesio/mesaticephalic Orthoclusion

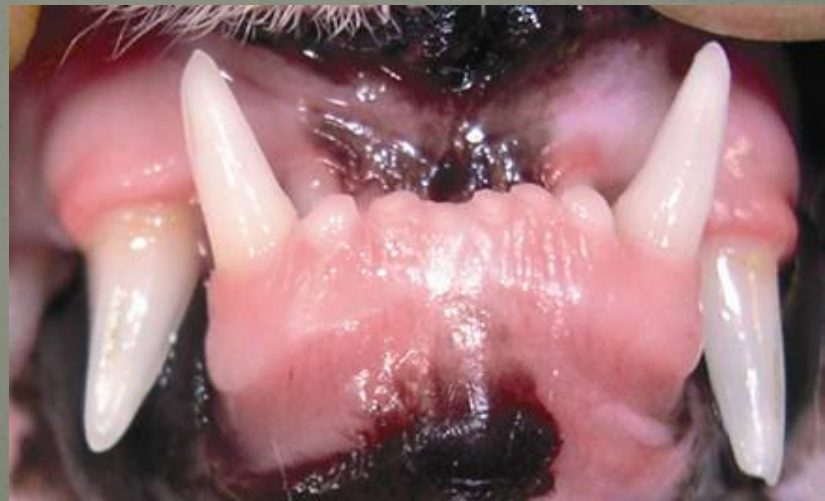
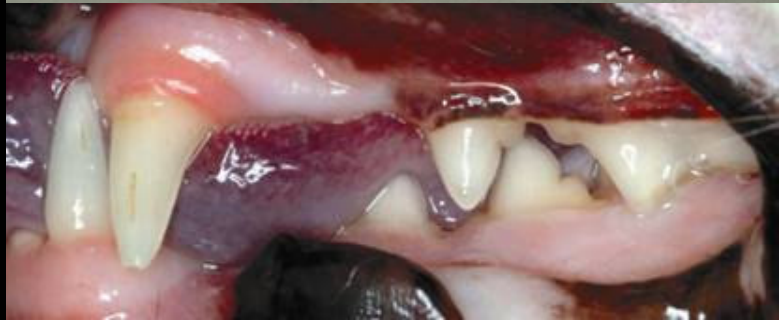

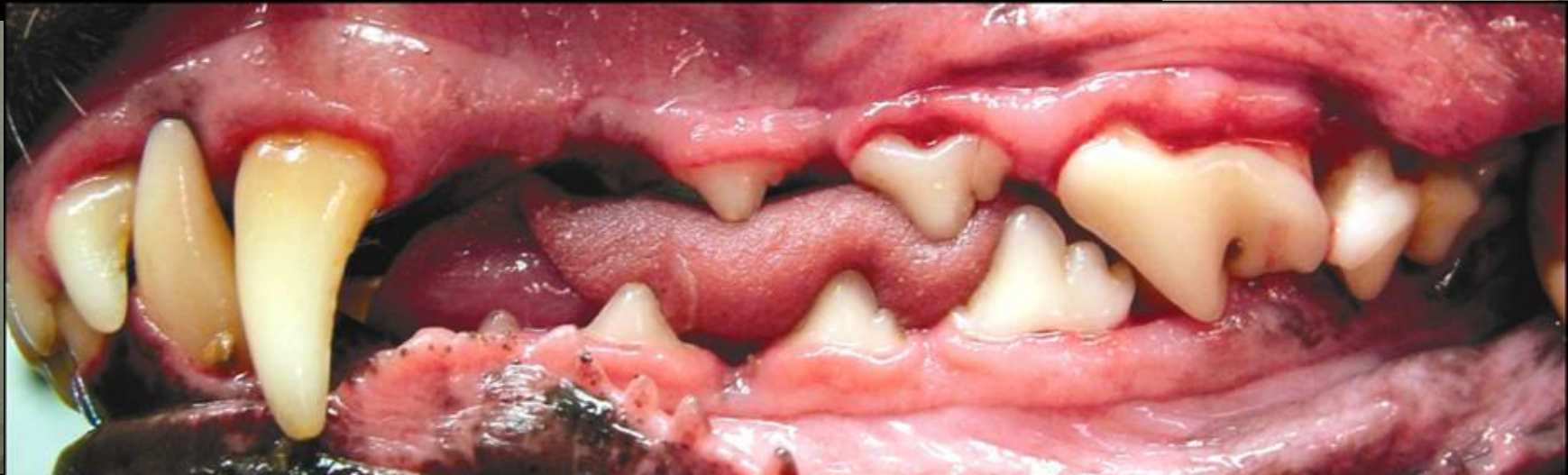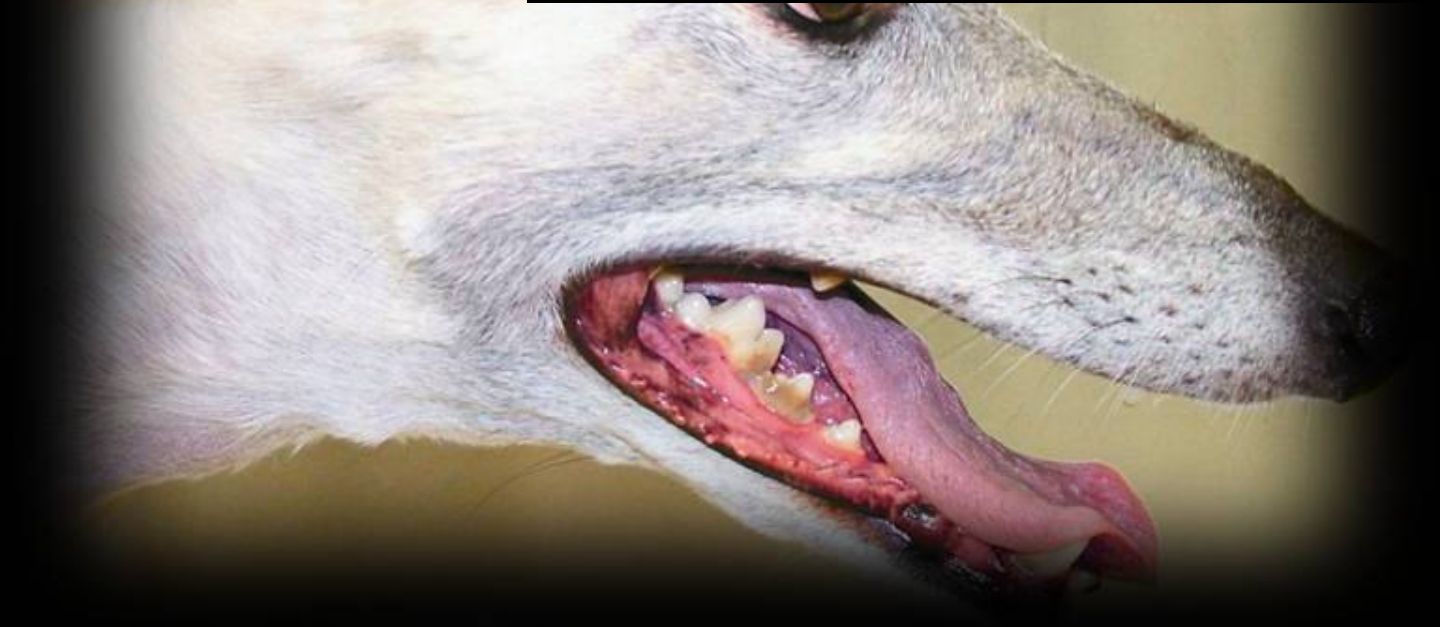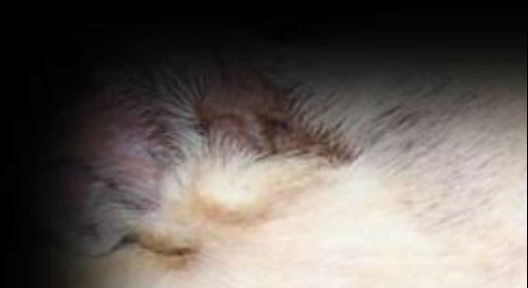Brachycephalic

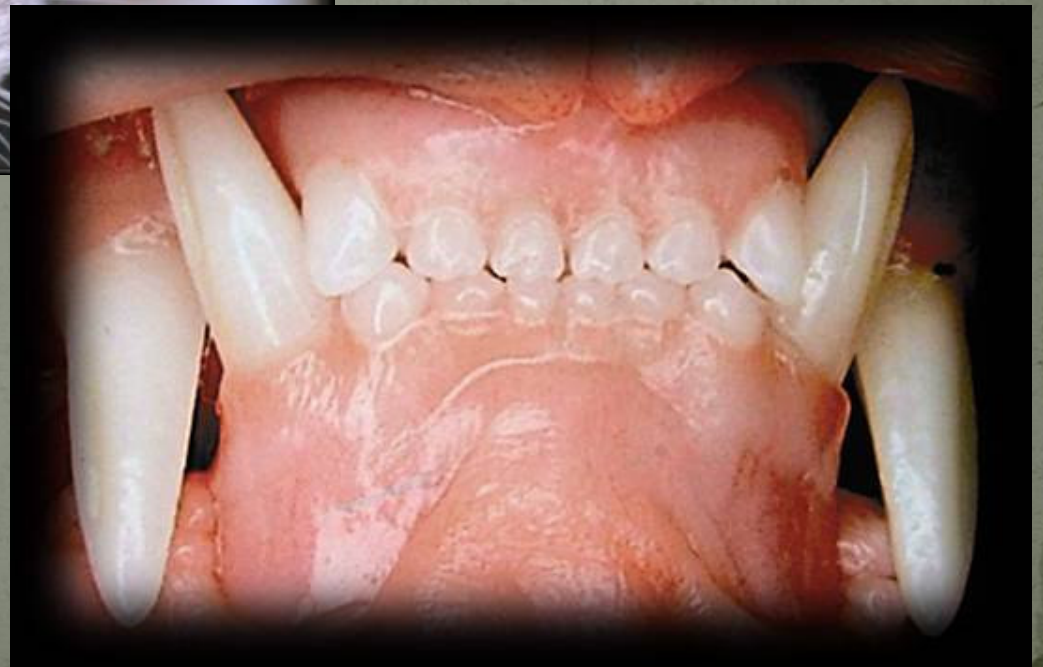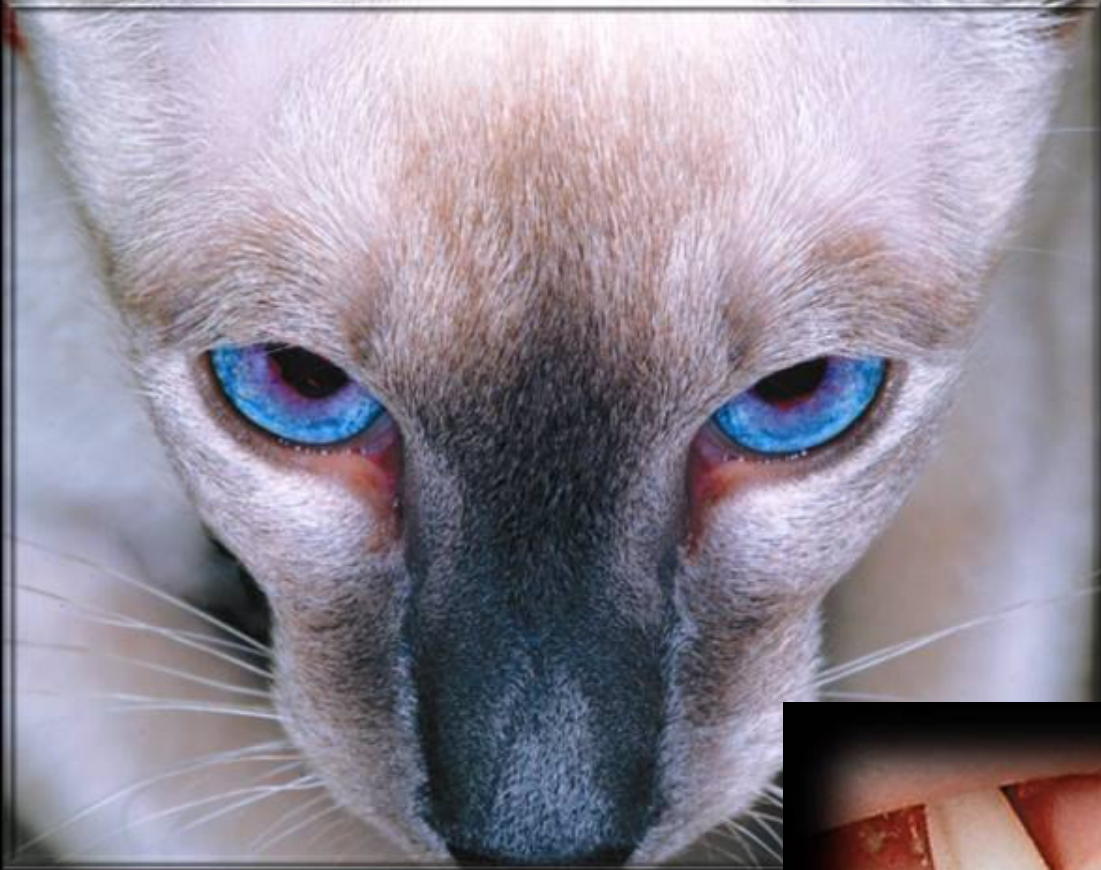(mandibular) **mesioclusion**



Mandibular mesioclusion







MALOCCLUSION

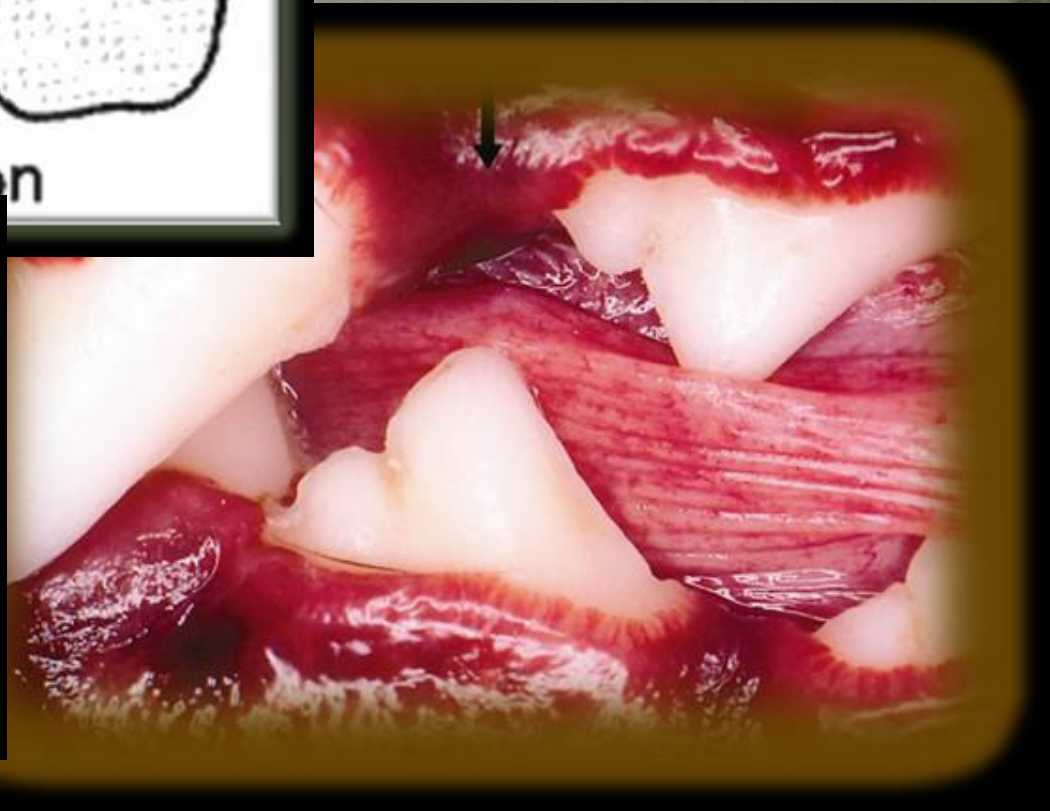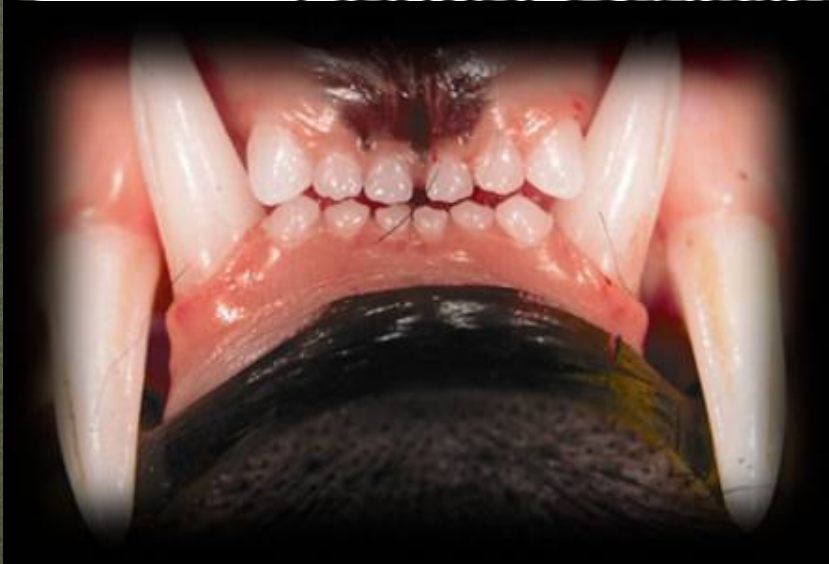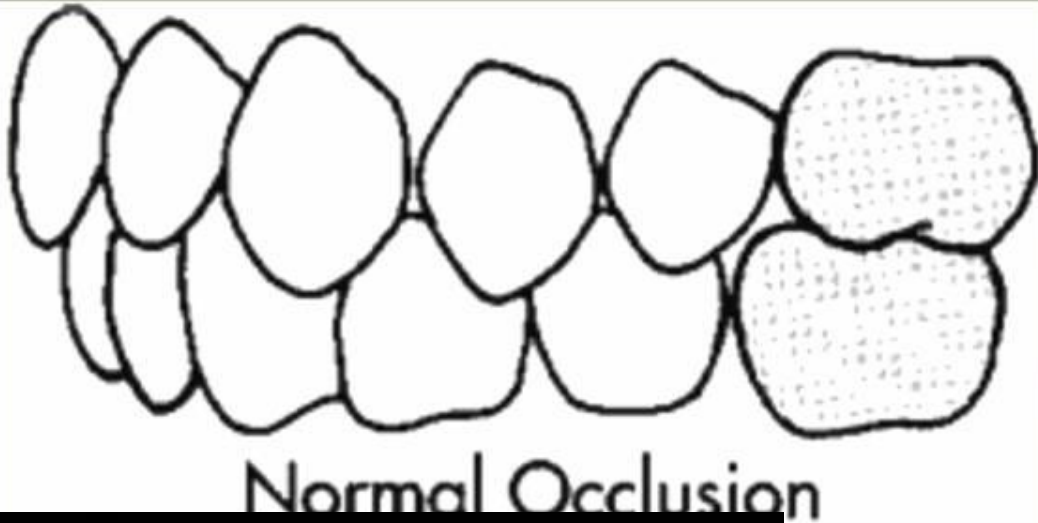
ANGLE CLASSIFICATION

SKELETAL

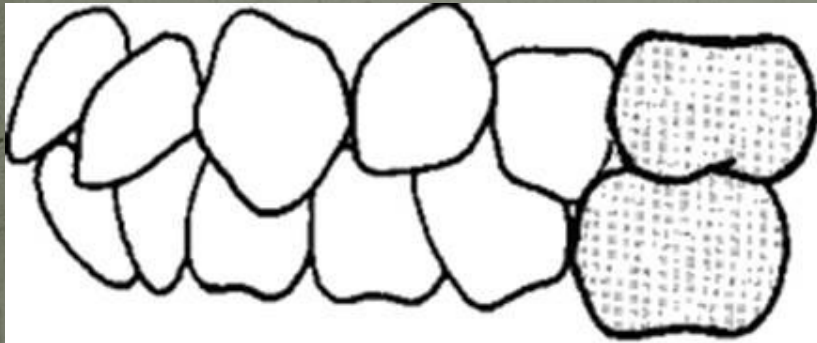
VS.

DENTAL

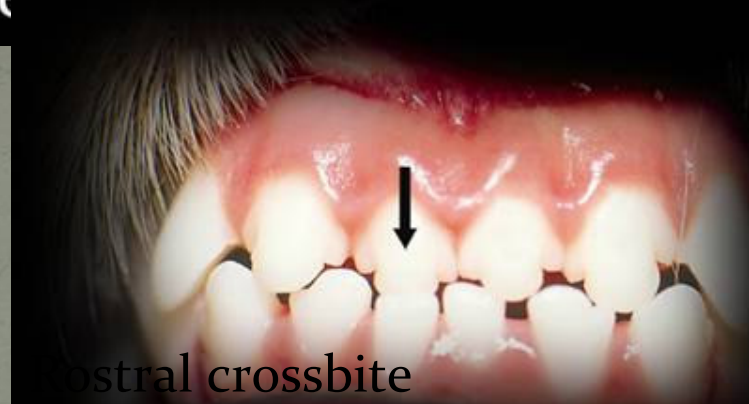Angle's Classification of Malocclusion



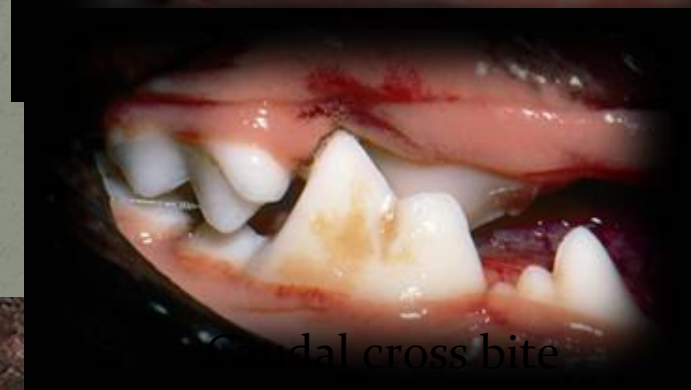Class I Dental malocclusion normal molar relationship but one or more



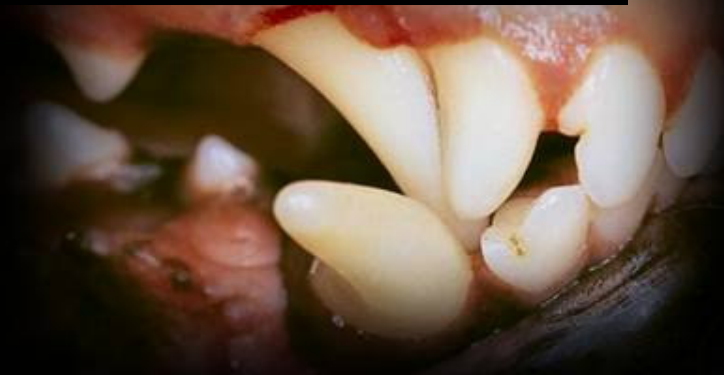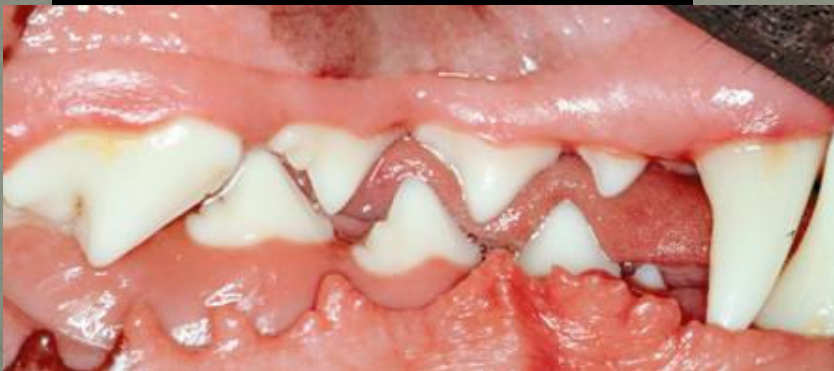Class I Malocclusion



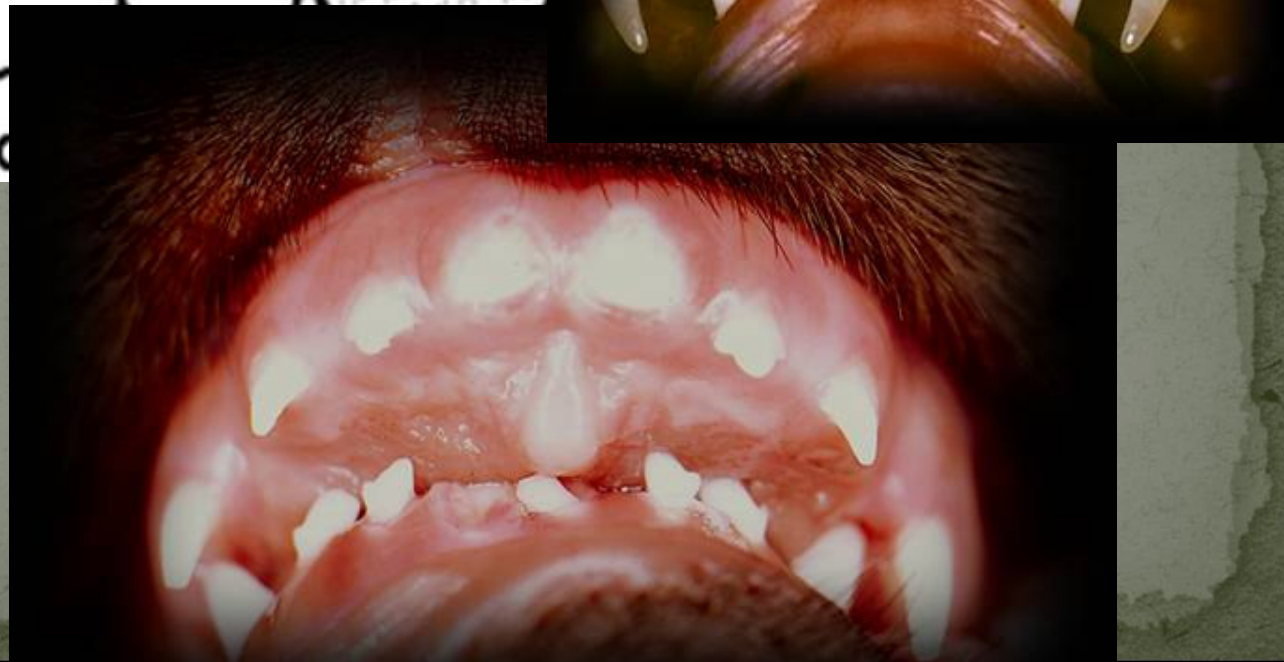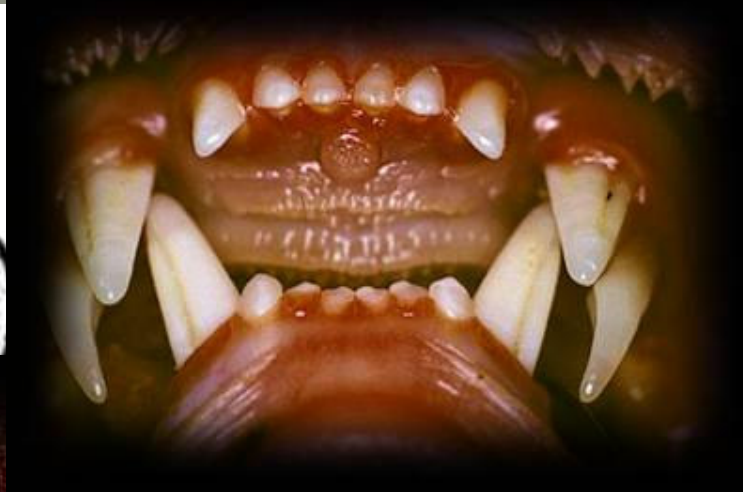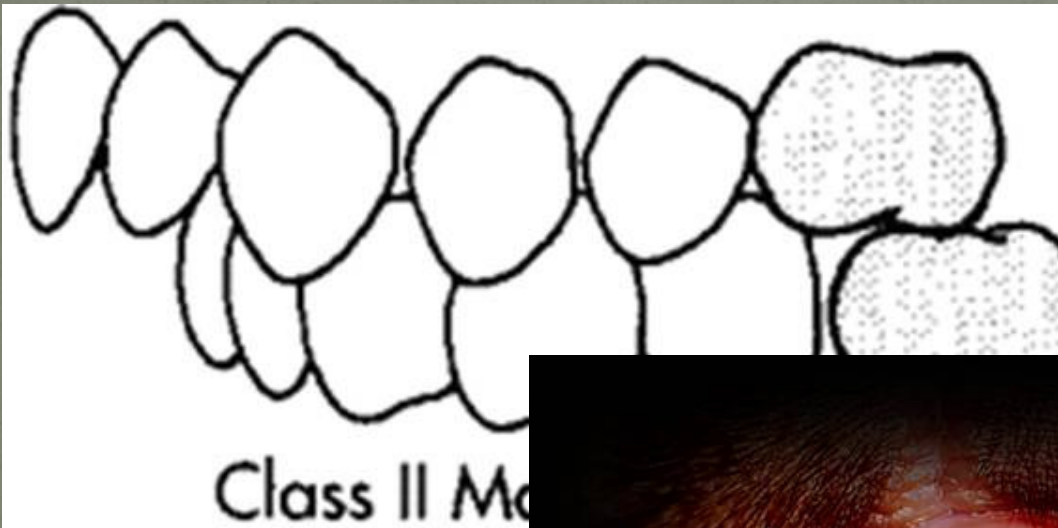
Anterior crossbite



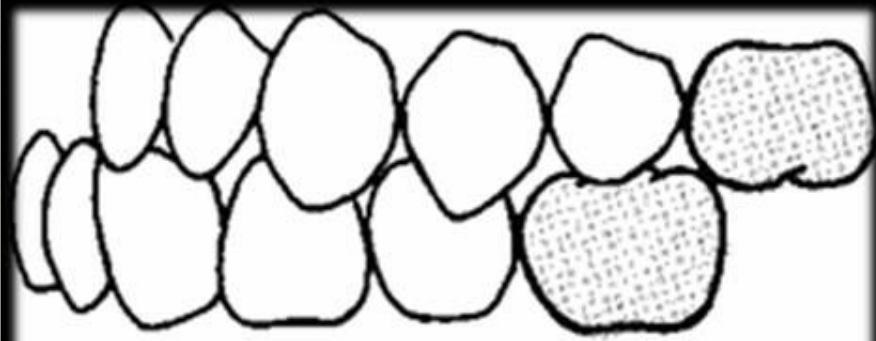Buccal cross bite



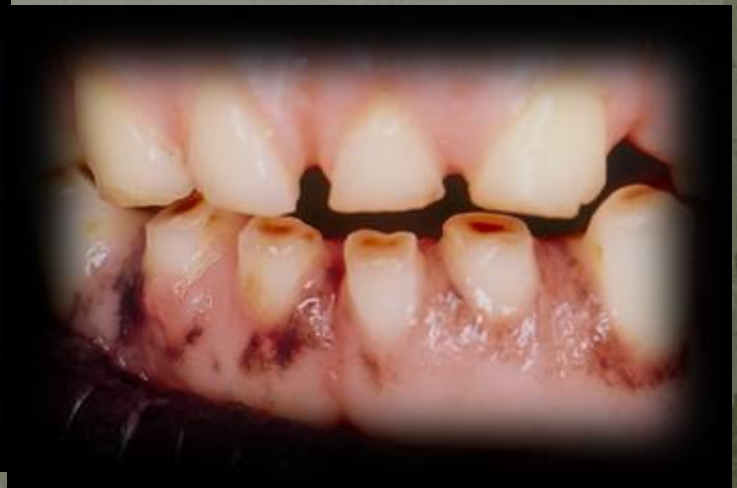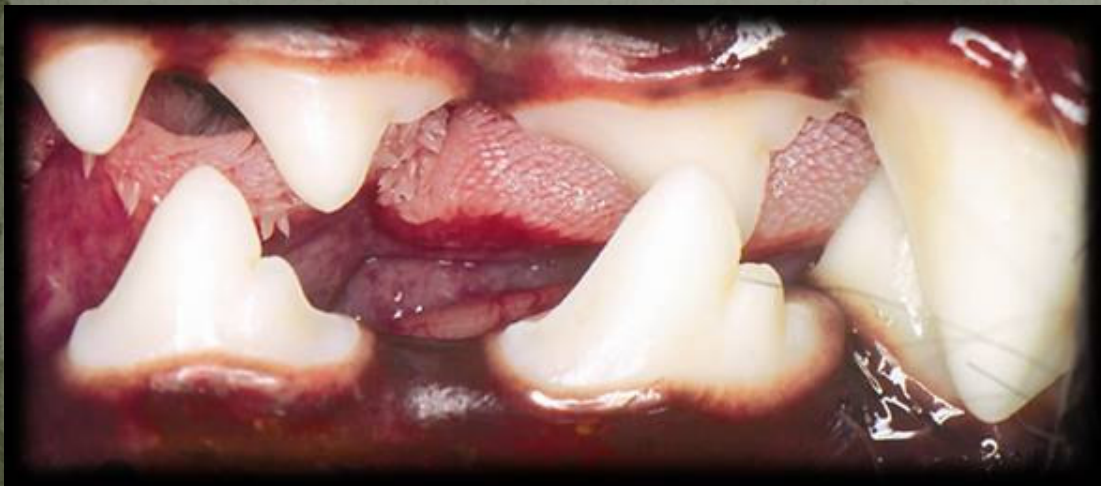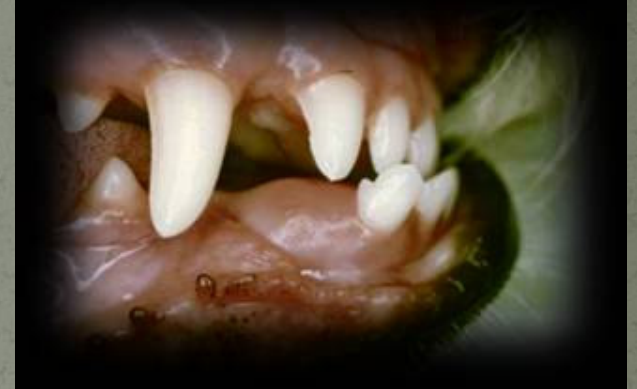Class II Skeletal malocclusion-lower molar placed behind the upper molar.
Mandibular brachygnathism



Class III Skeletal malocclusion lower molar placed forward to the upper molar.
mandibular mesioclusion

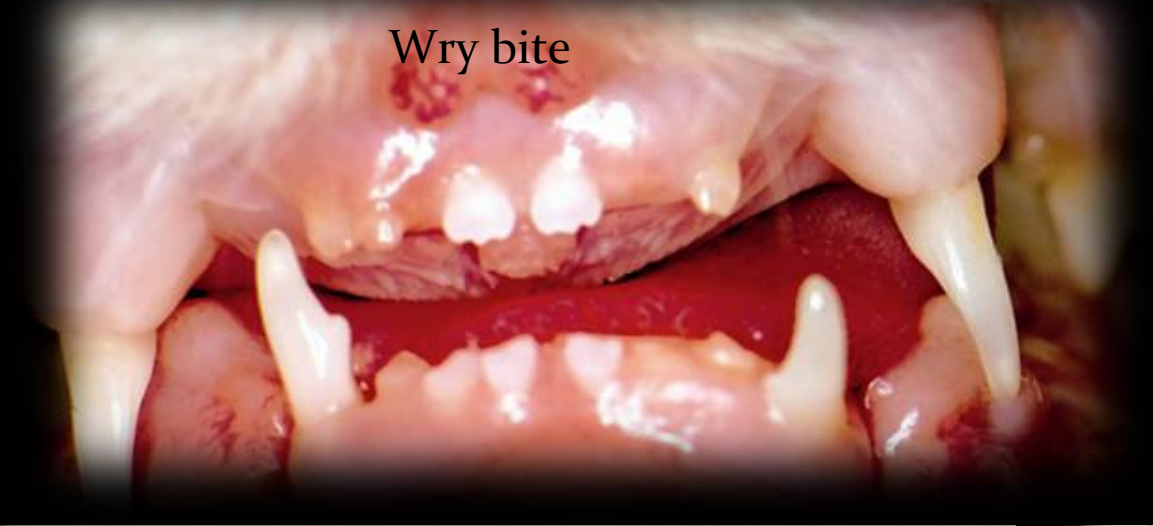

Class III Malocclusion

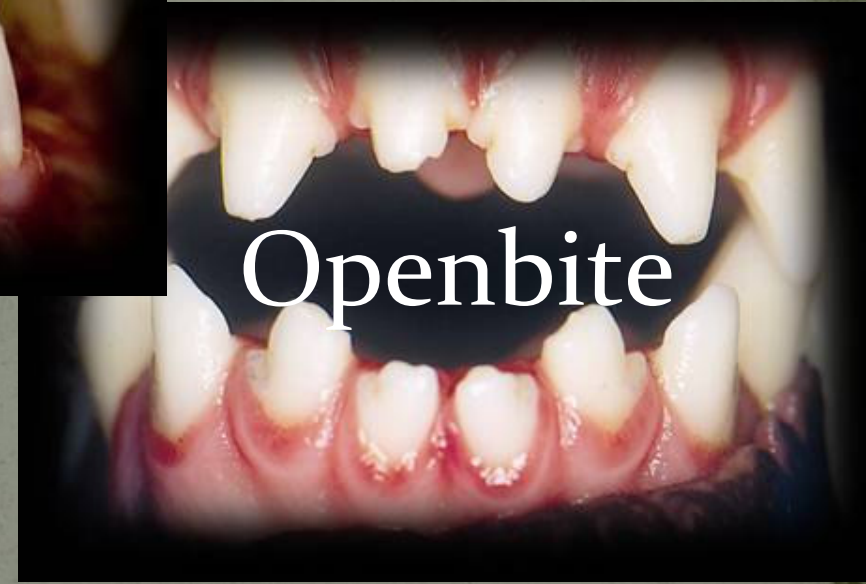

Skeletal Malocclusion

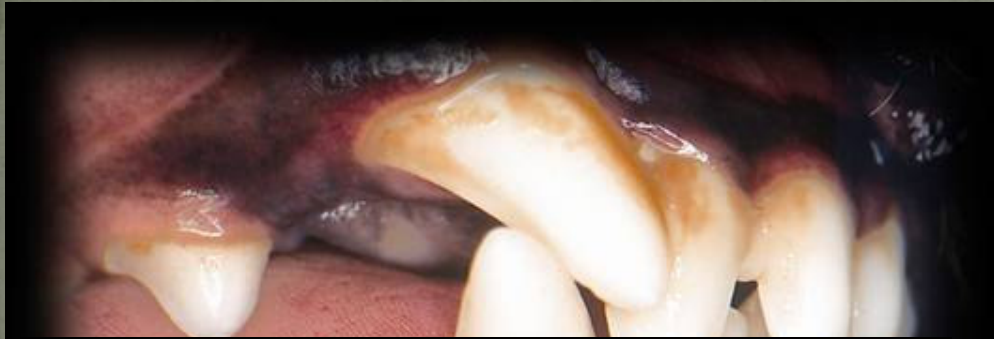Wry bite



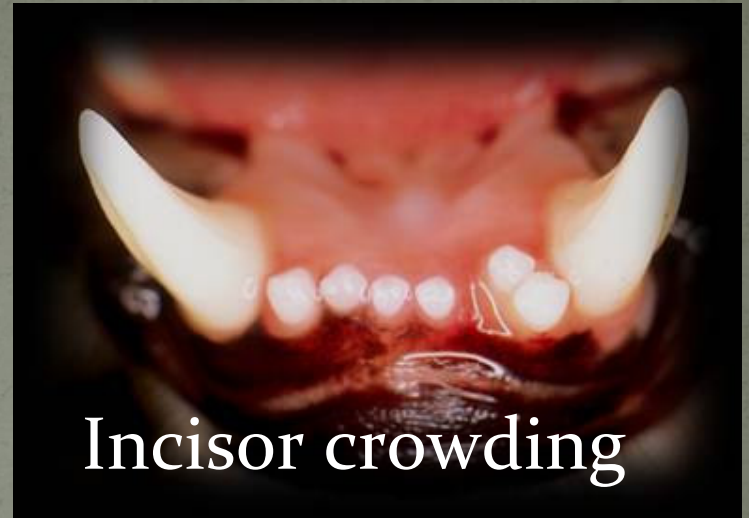Openbite



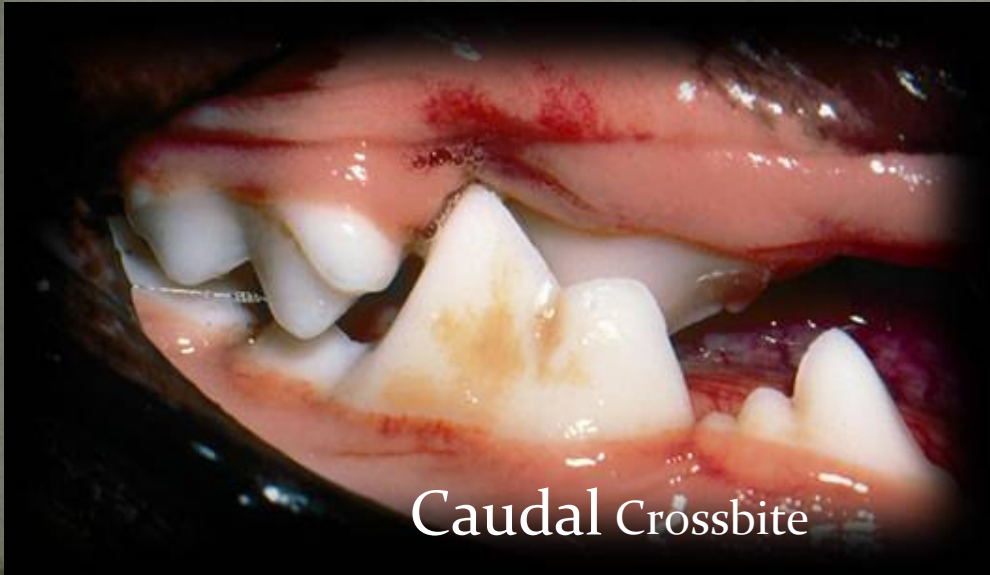
Dental malocclusion



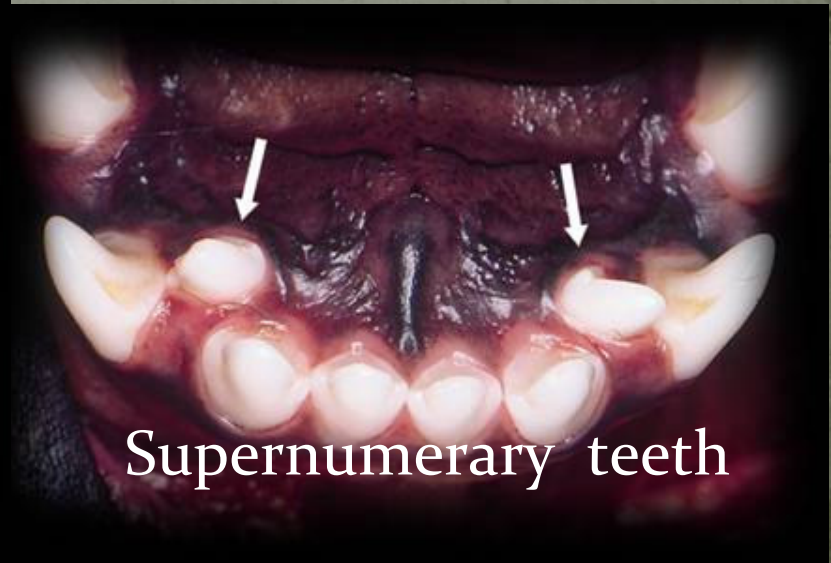Mesioverted maxillary) canine



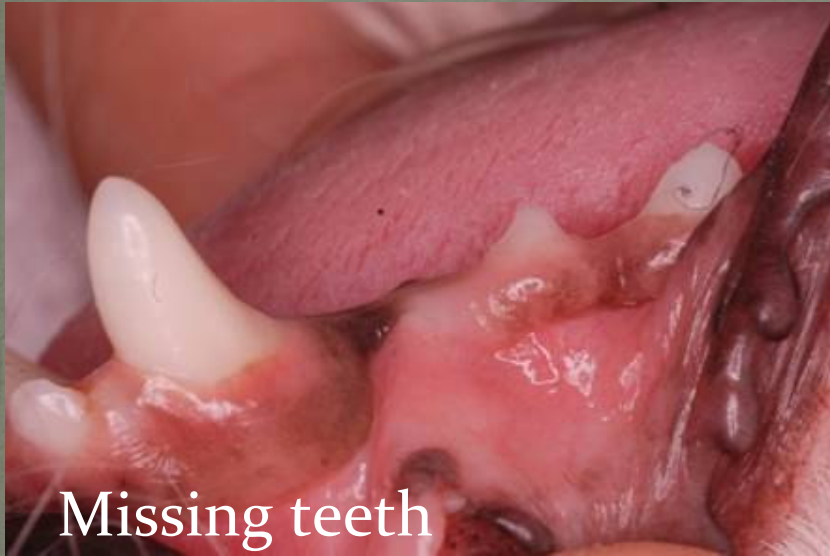Incisor crowding



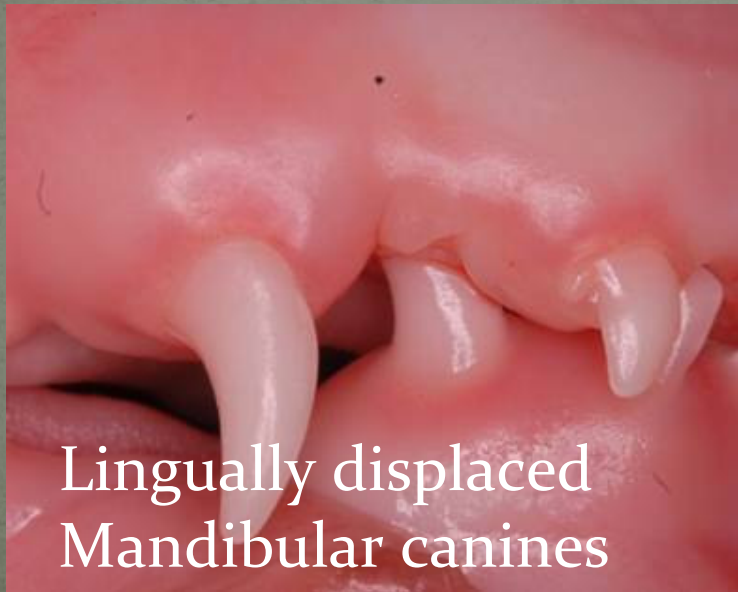Caudal Crossbite



Supernumerary teeth

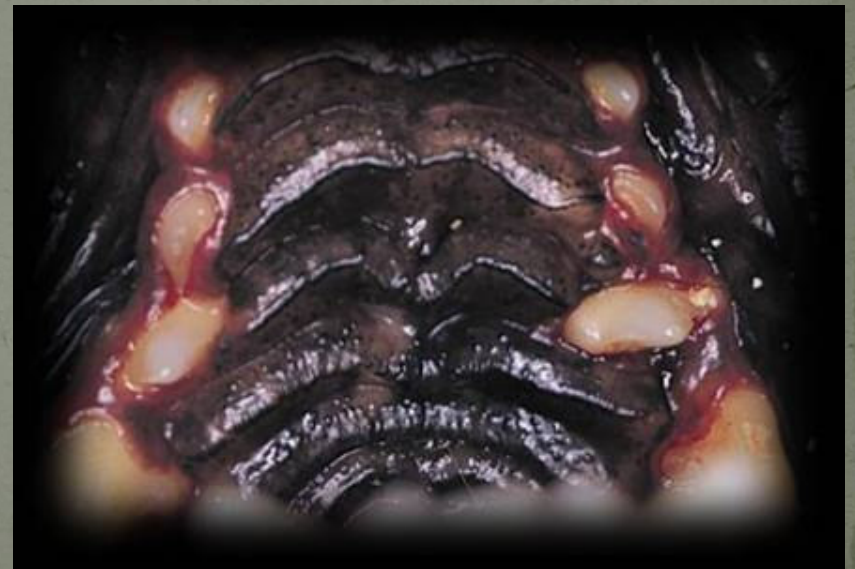

Missing teeth

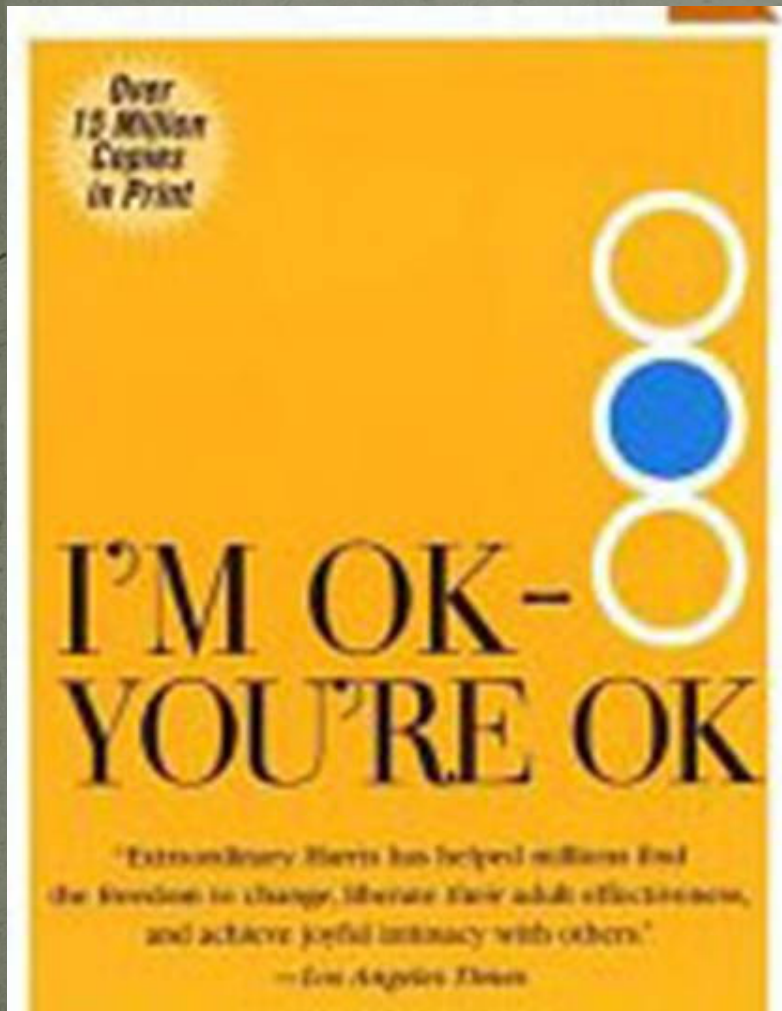


Lingually displaced
Mandibular canines

Rotated teeth



What to do about it?



I'M OK-YOU'RE OK
NORMAL -FUNCTIONAL

I'M OK-YOU'RE NOT OK
NORMAL -NOT FUNCTIONAL

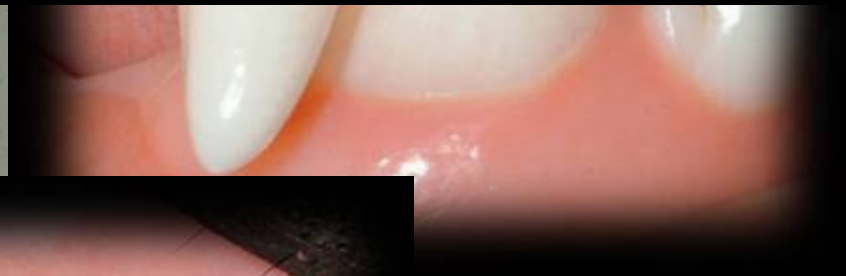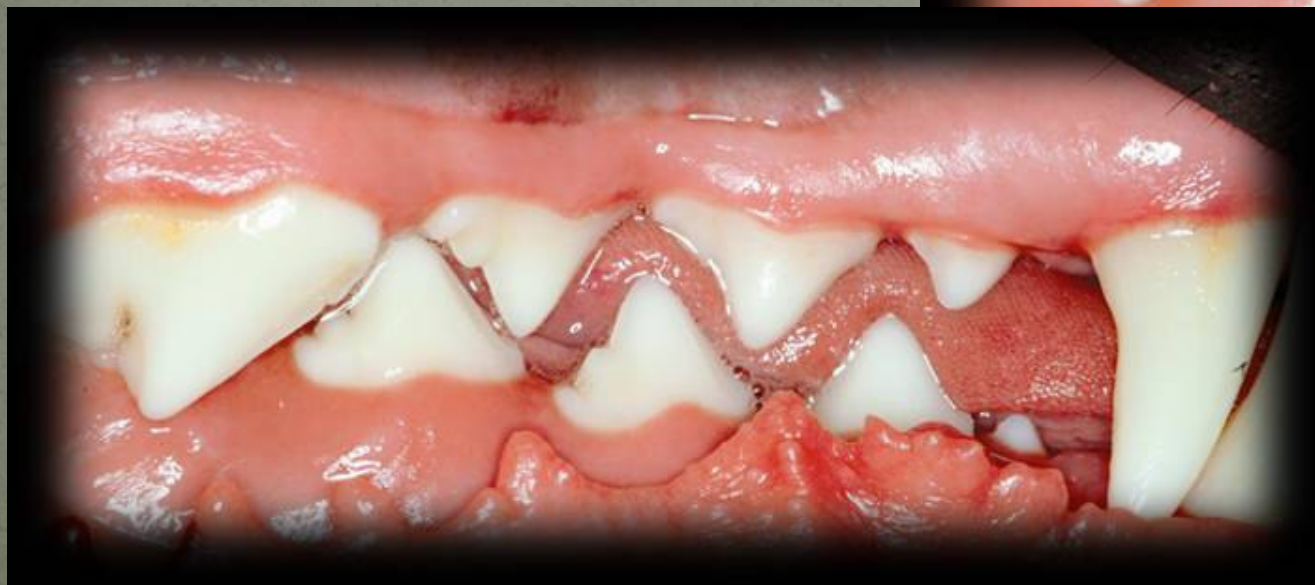I'M NOT OK YOU'RE OK

NOT NORMAL - FUNCTIONAL

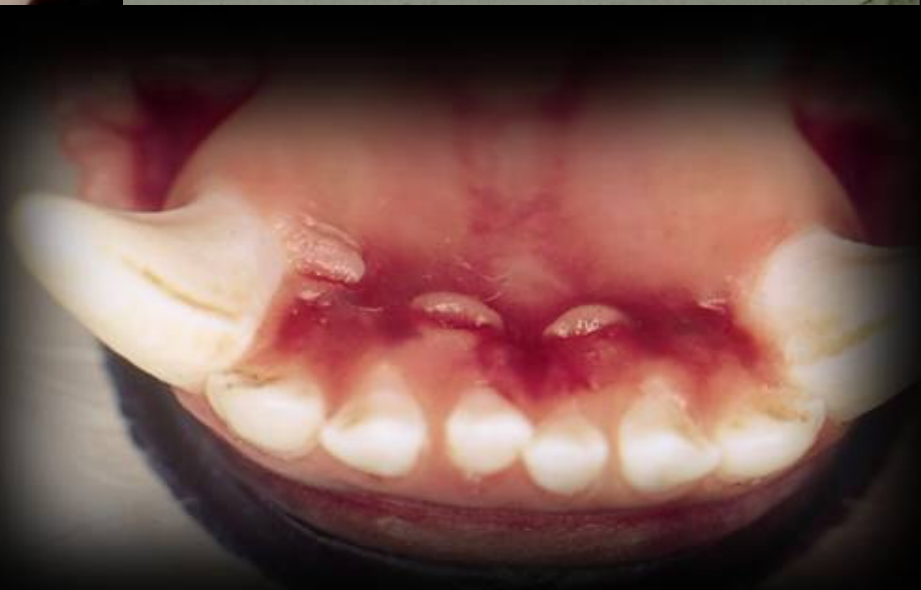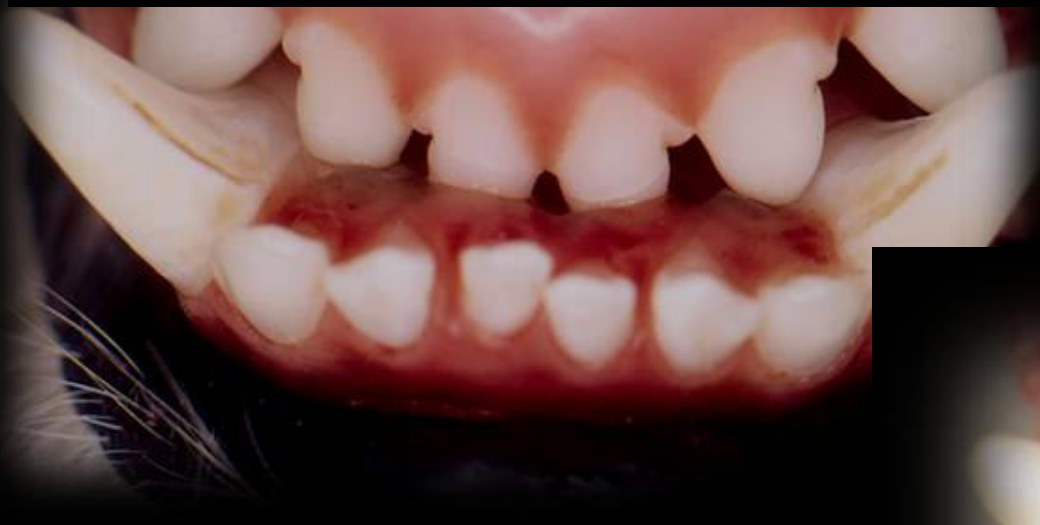I'M NOT OK- YOU'RE NOT OK

NOT NORMAL-NOT
FUNCTIONAL

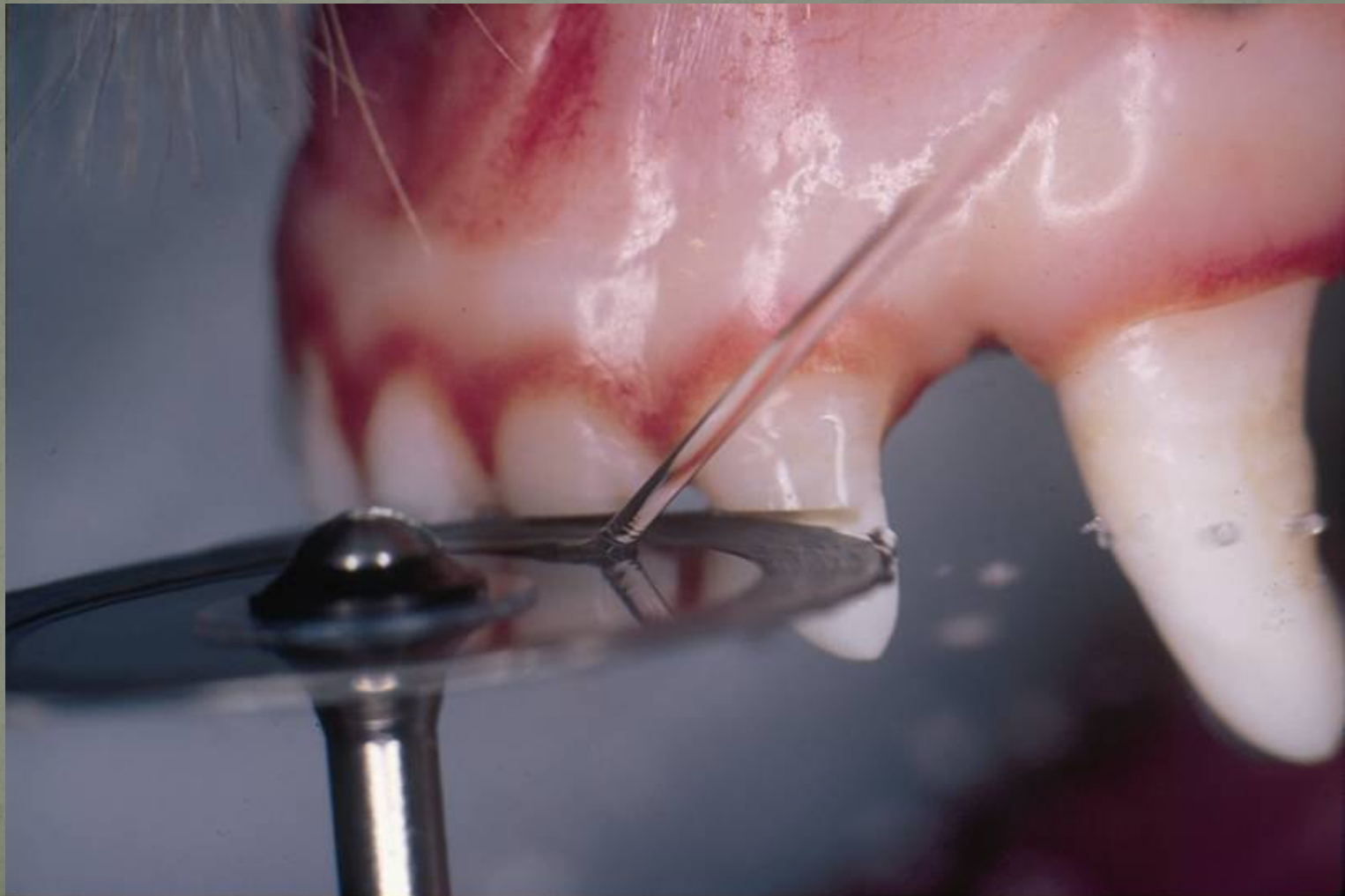I'M OK-YOU'RE OK
NORMAL -FUNCTIONAL



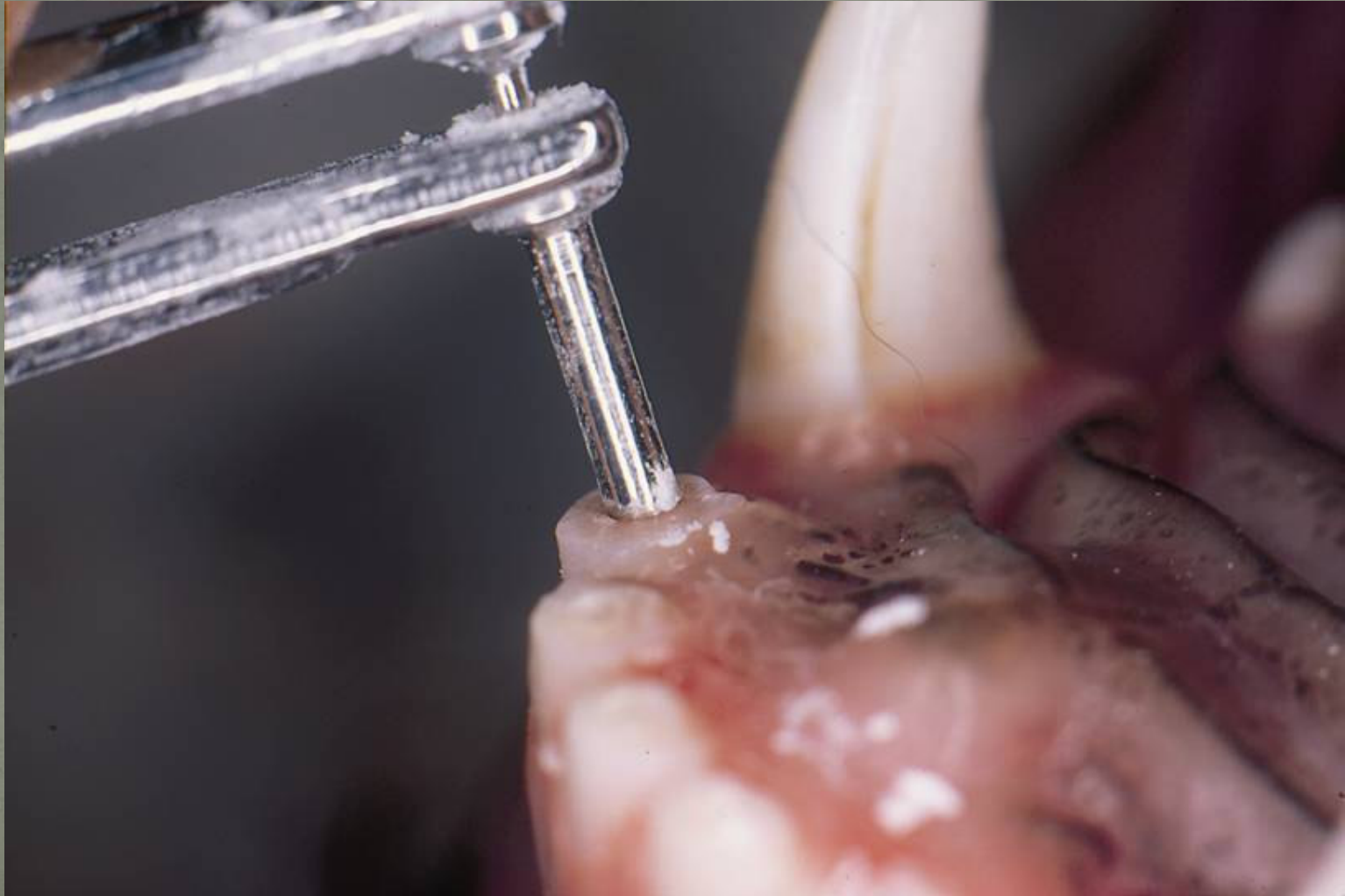I'M OK-YOU'RE NOT OK
"NORMAL" FOR BREED -NOT
FUNCTIONAL



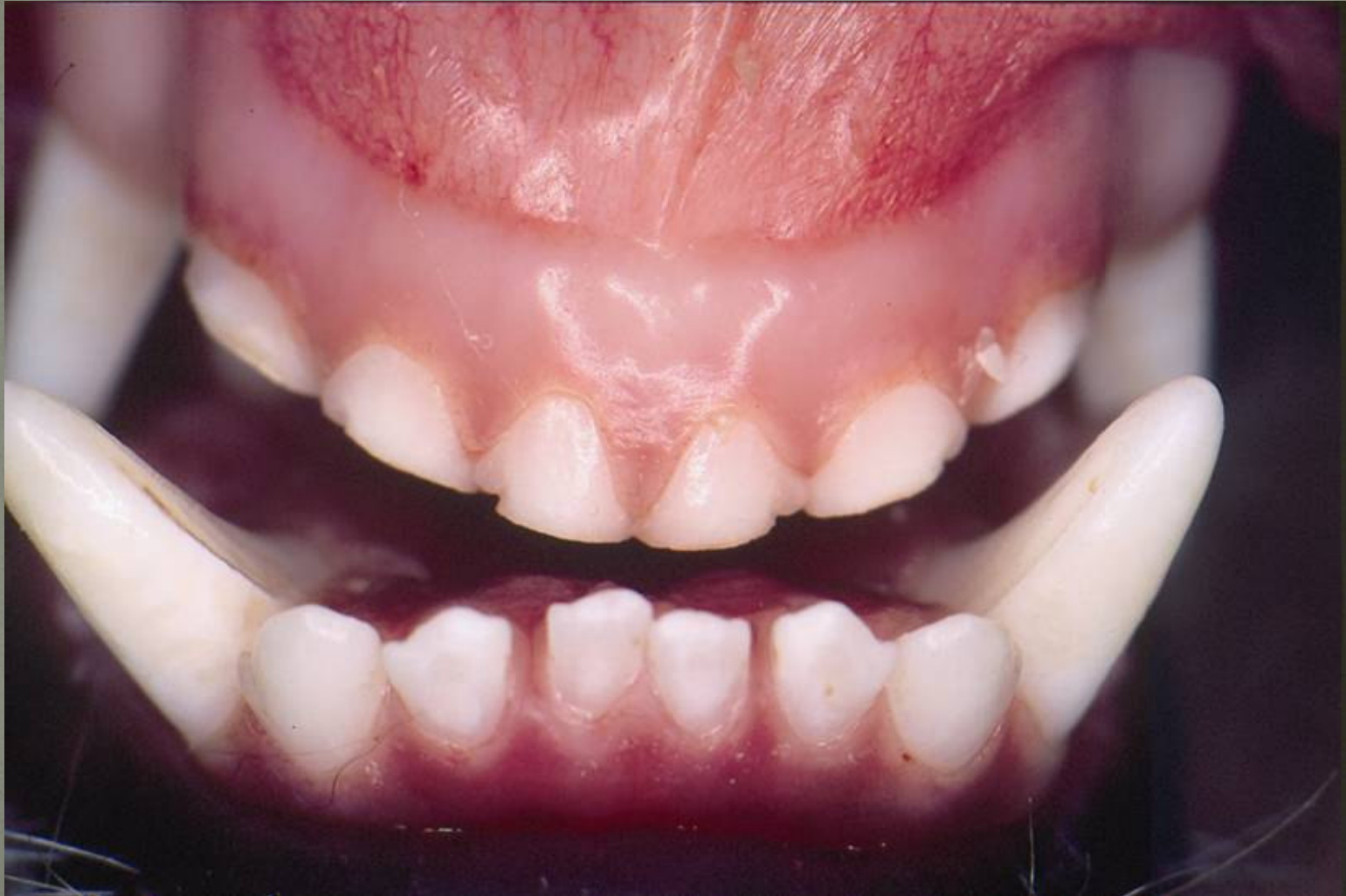Maxillary incisors crown reduction using a diamond disk



Calcium hydroxide applied on top of vital pulp tissue

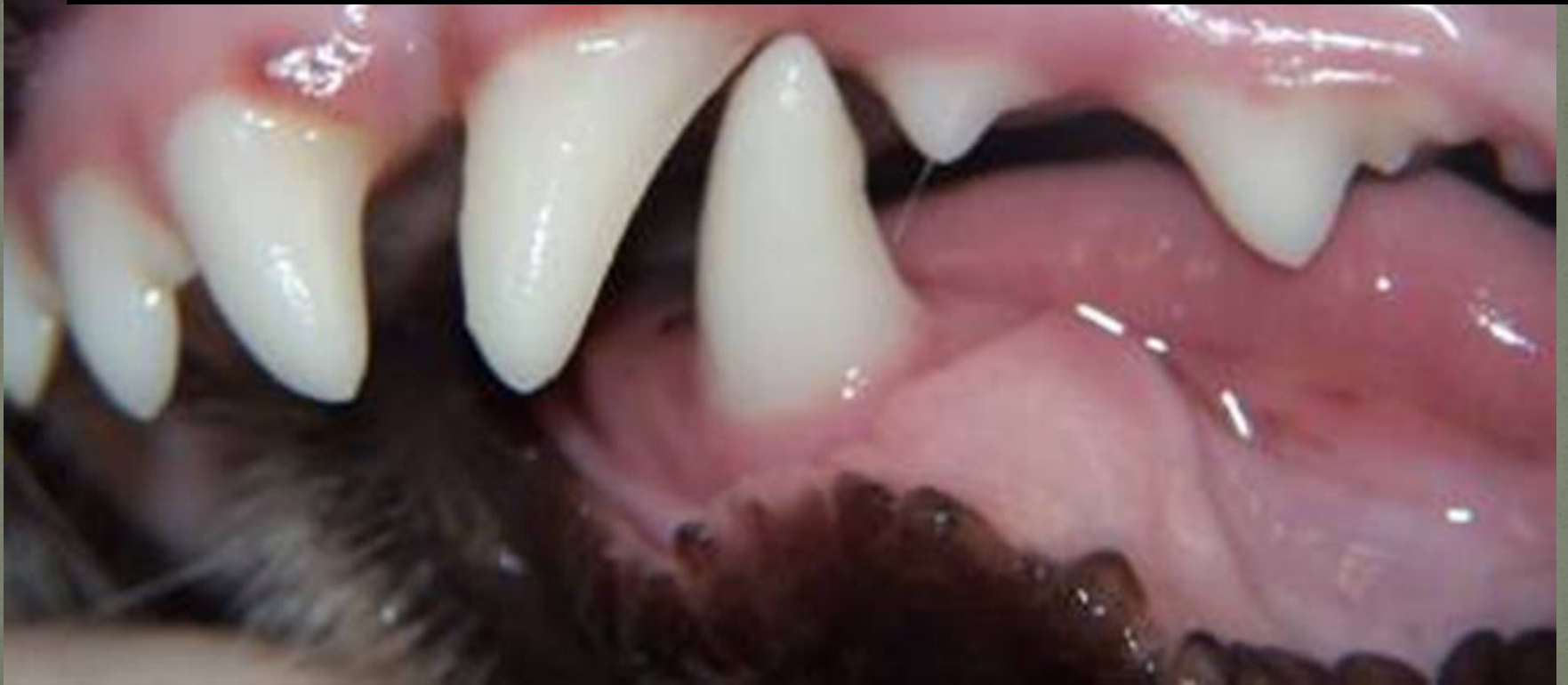

Crown reduced and restored incisors alleviating

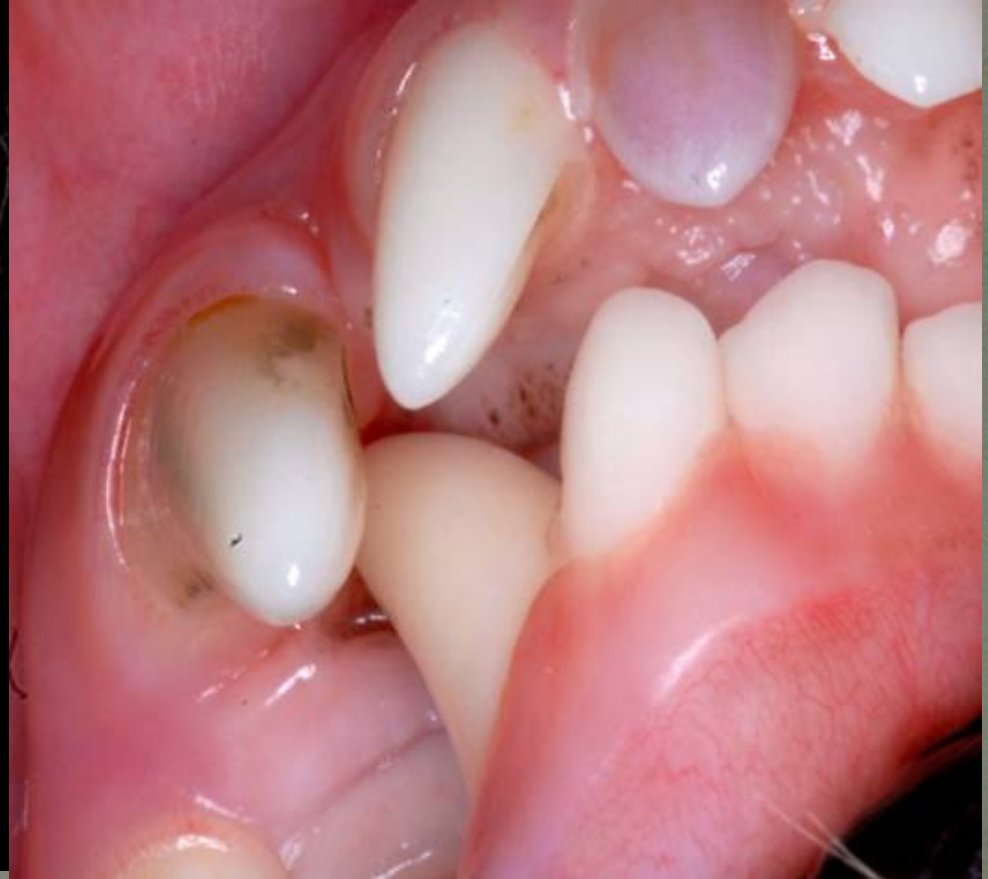
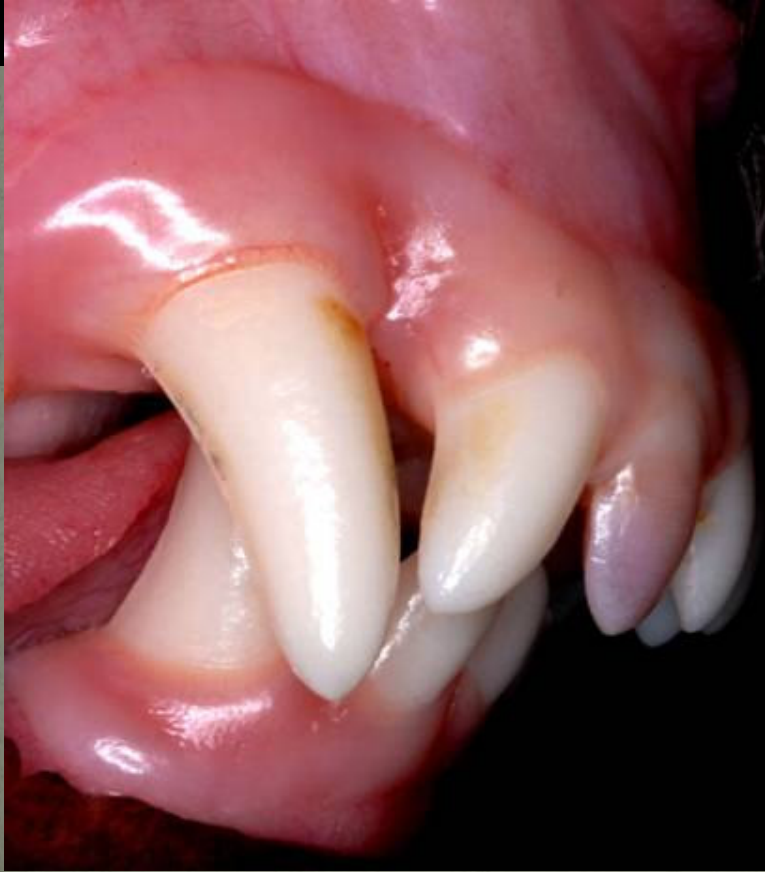
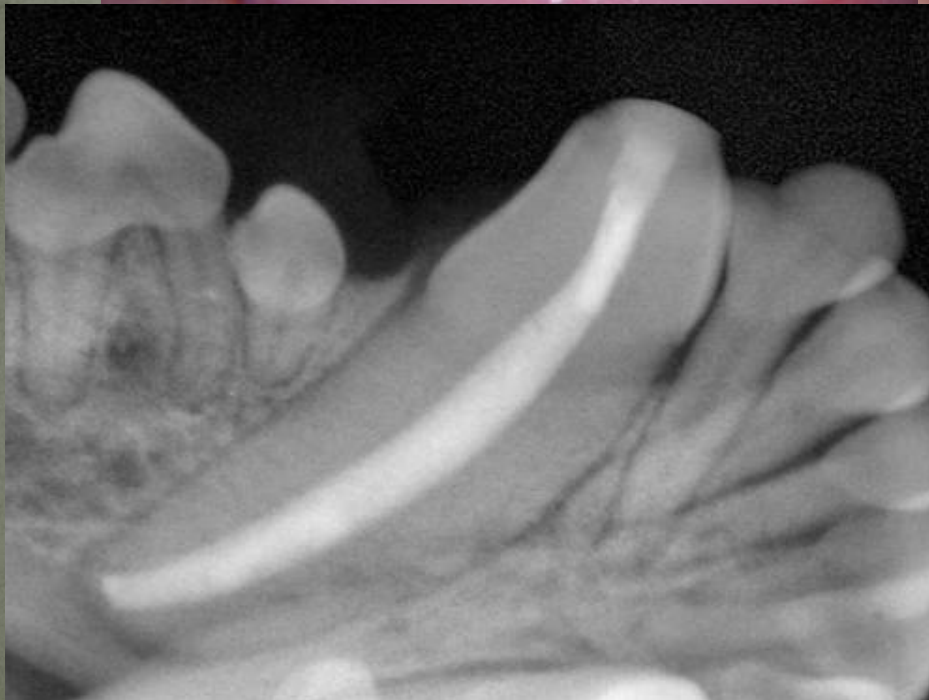
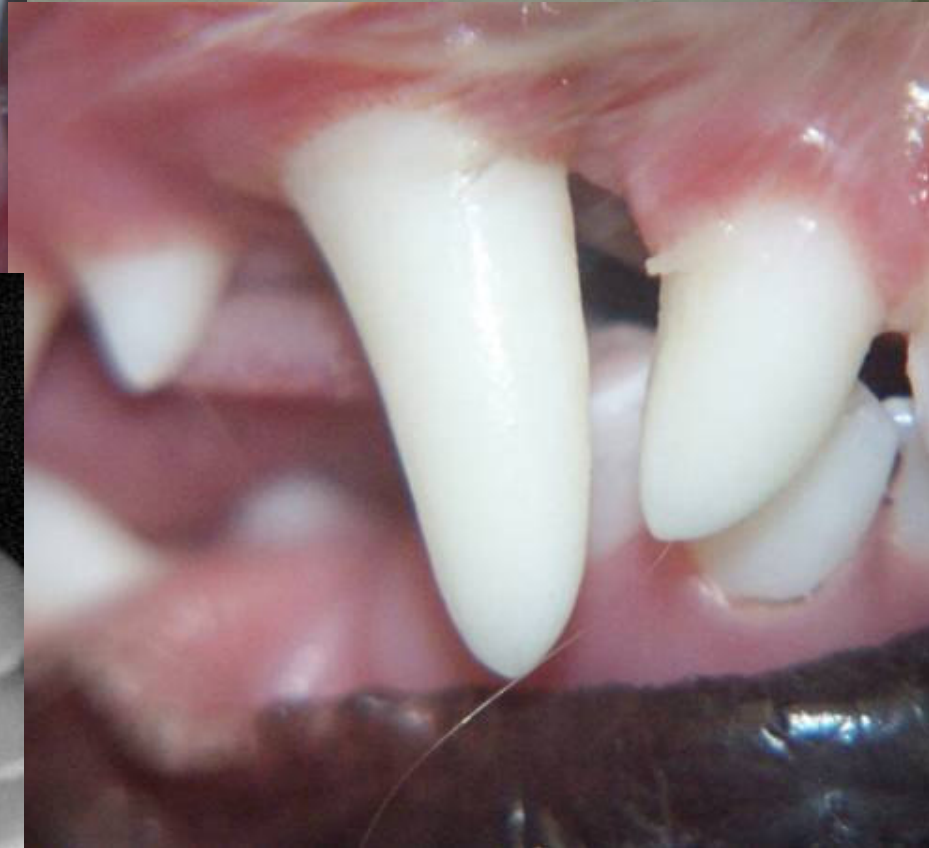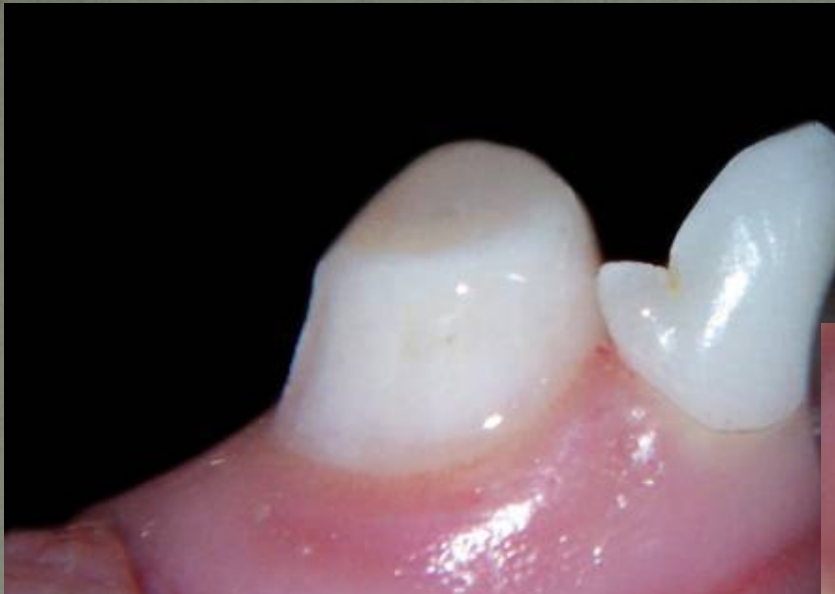I'M NOT
NOT

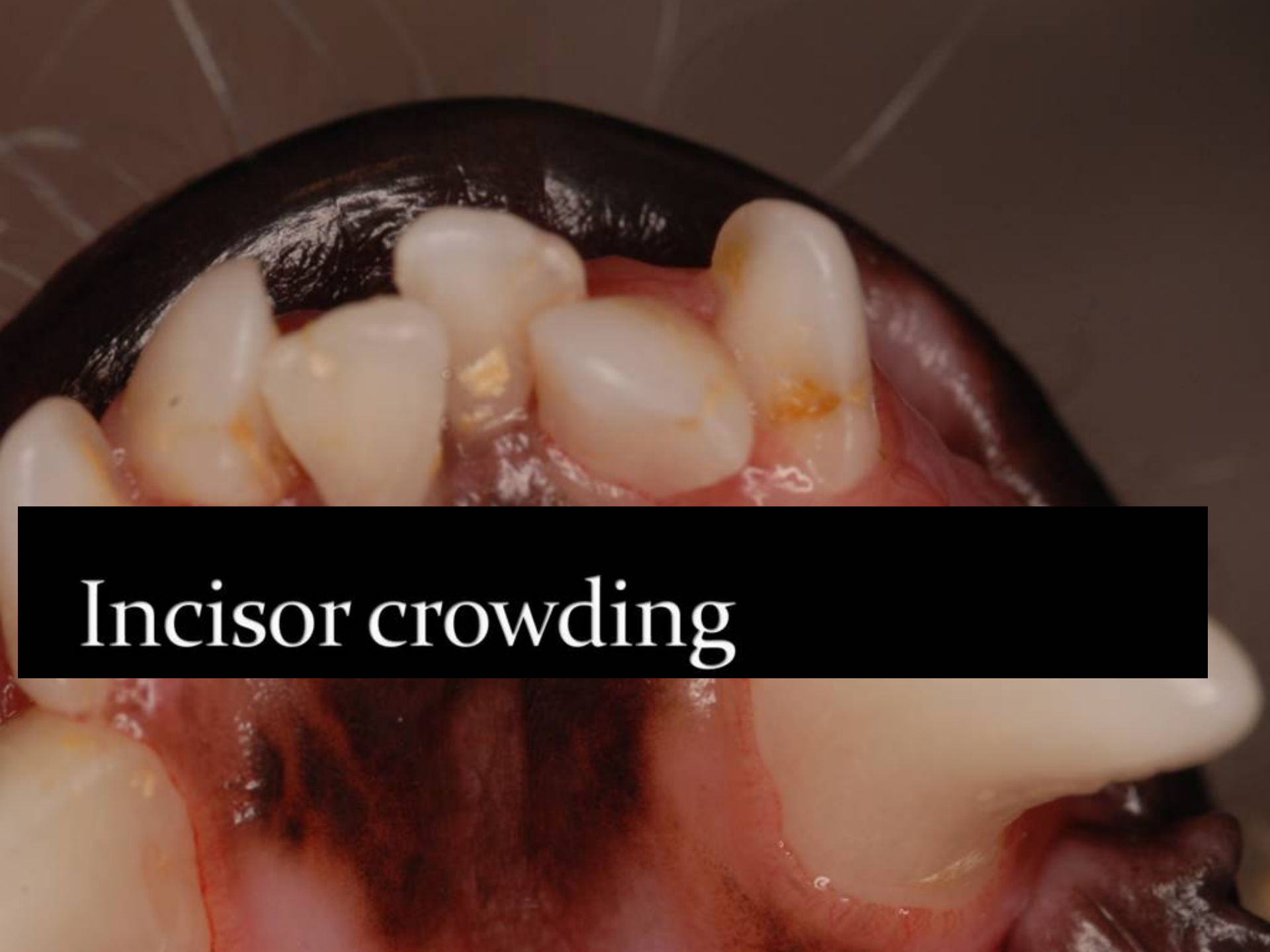FUNCTIONAL



I'M NOT OK- YOU'RE NOT OK
NOT NORMAL-NOT FUNCTIONAL

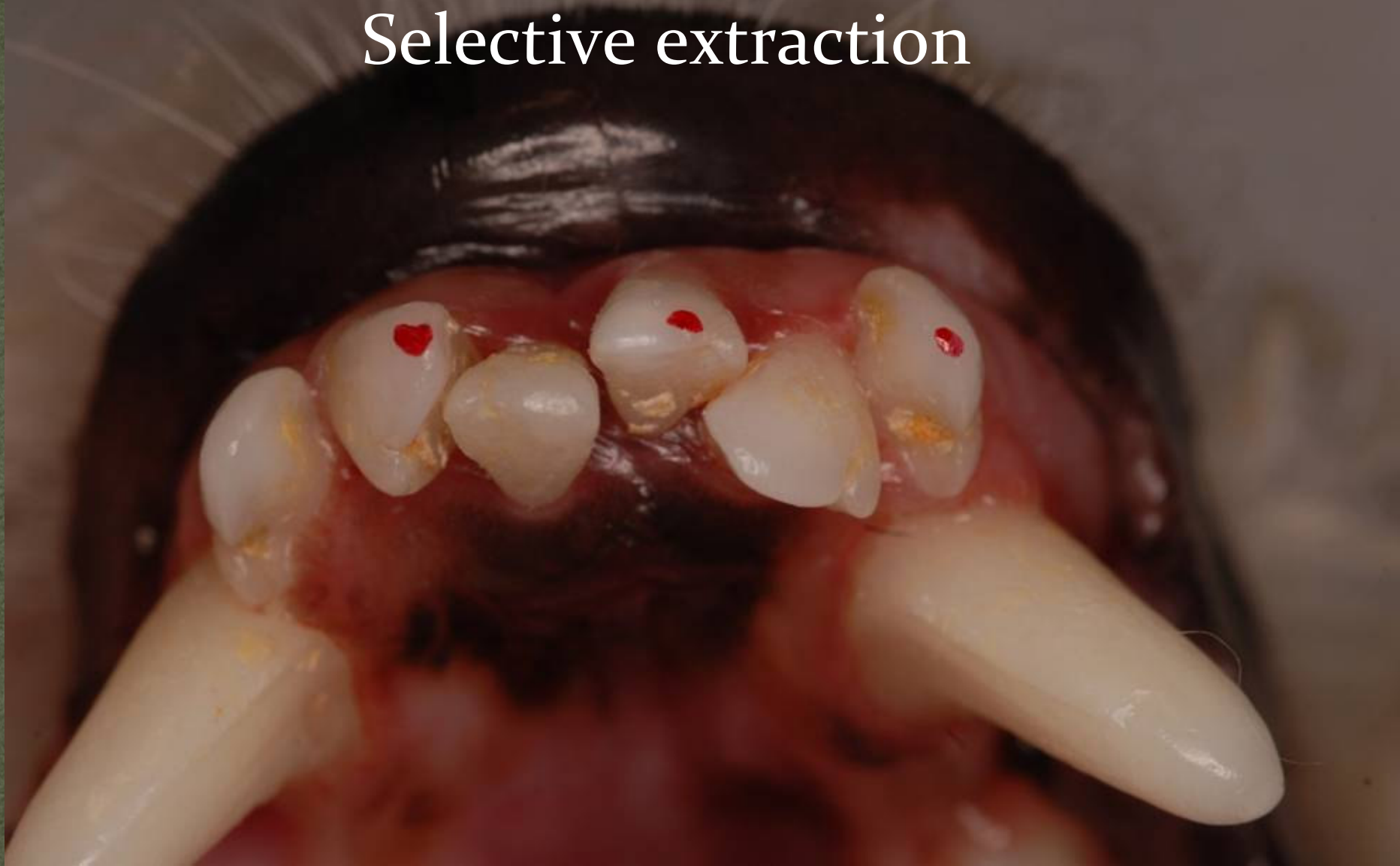

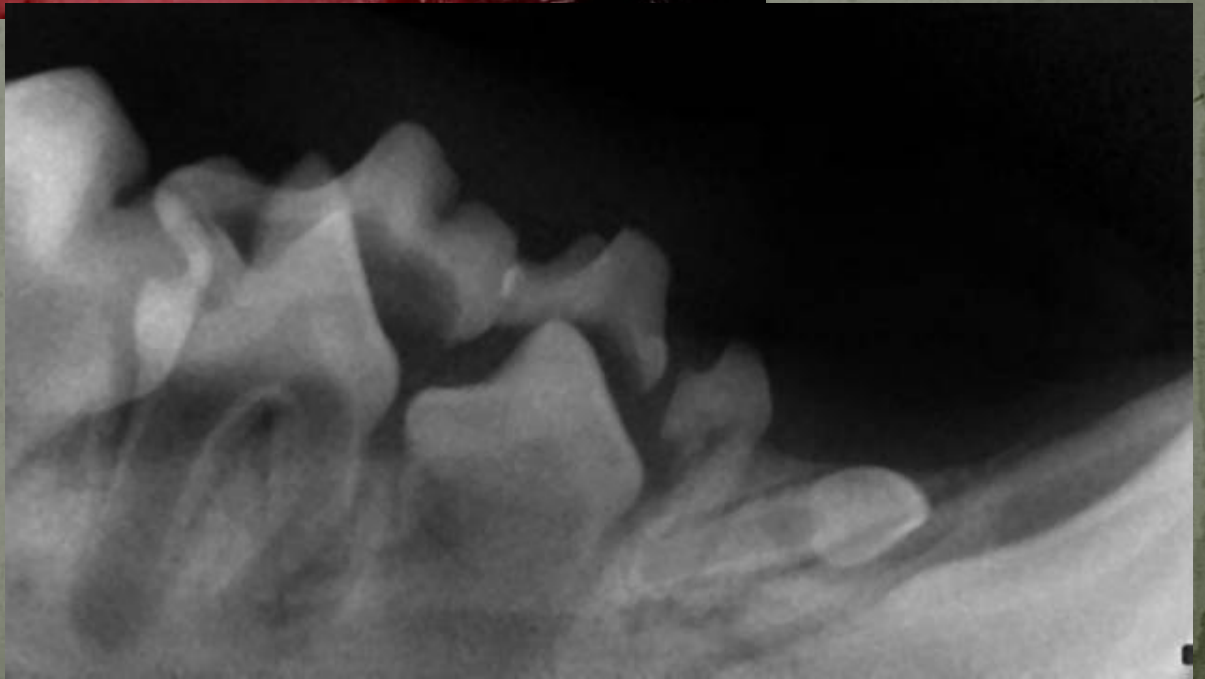

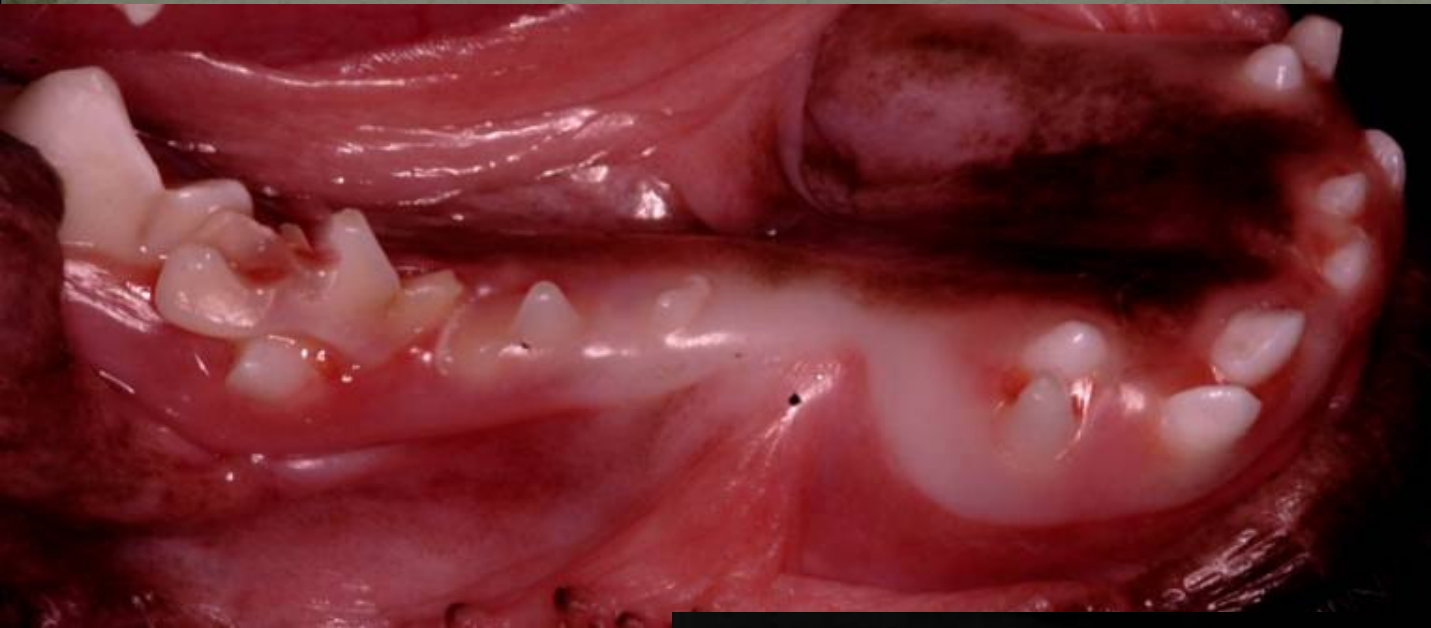
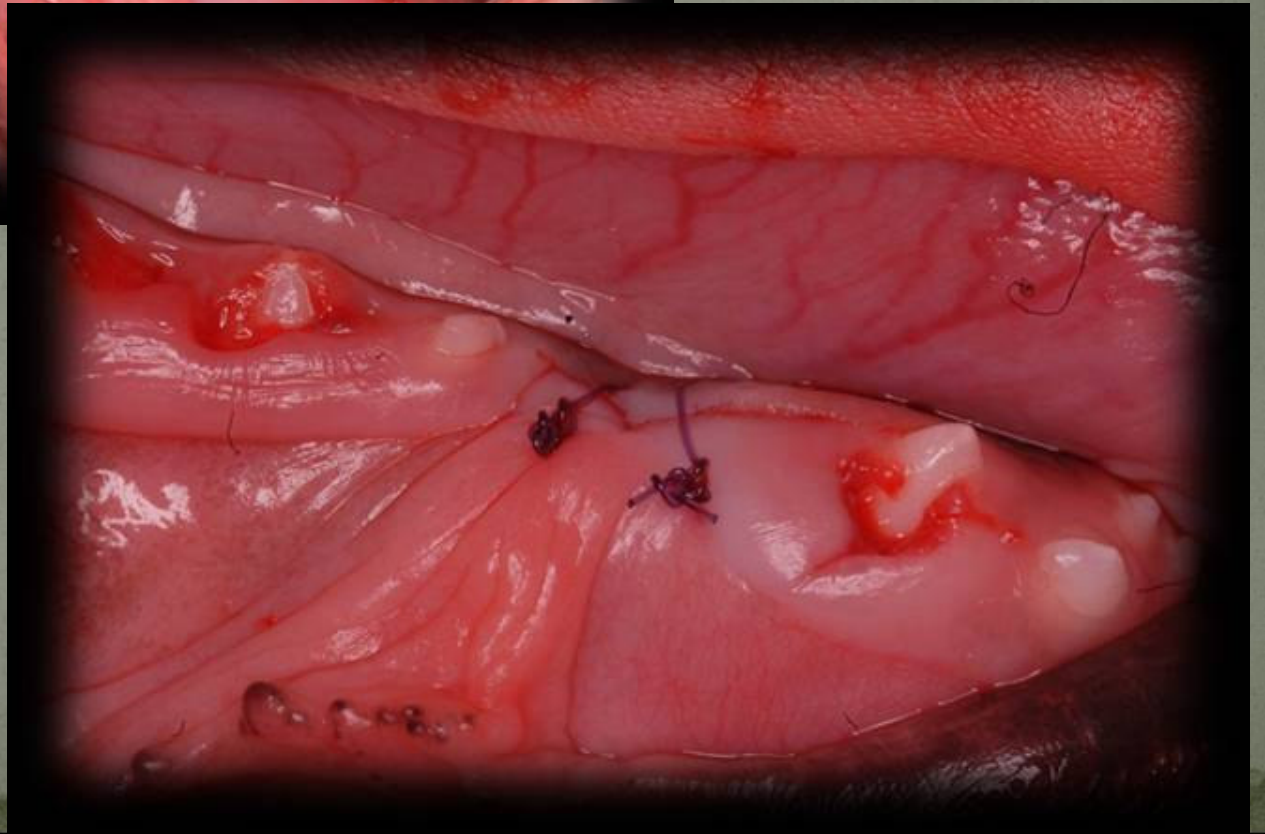
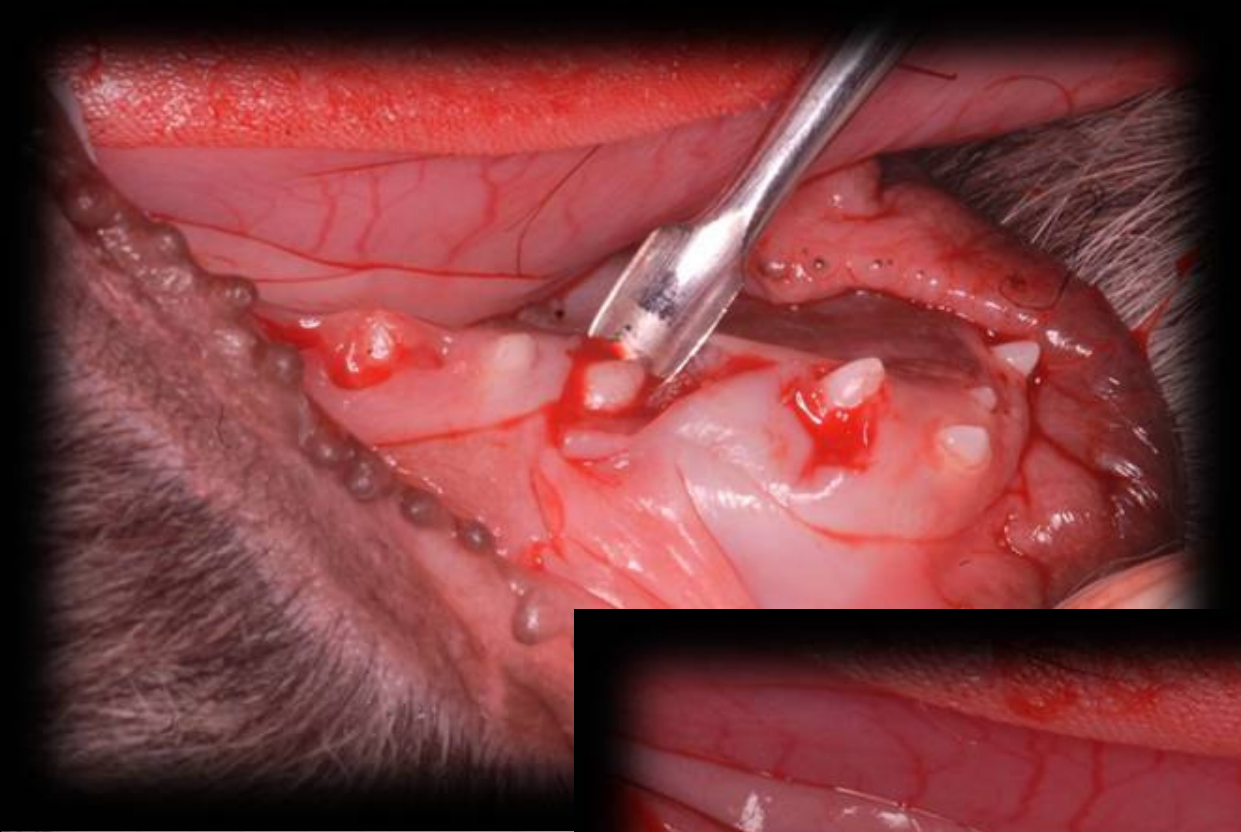


Incisor crowding

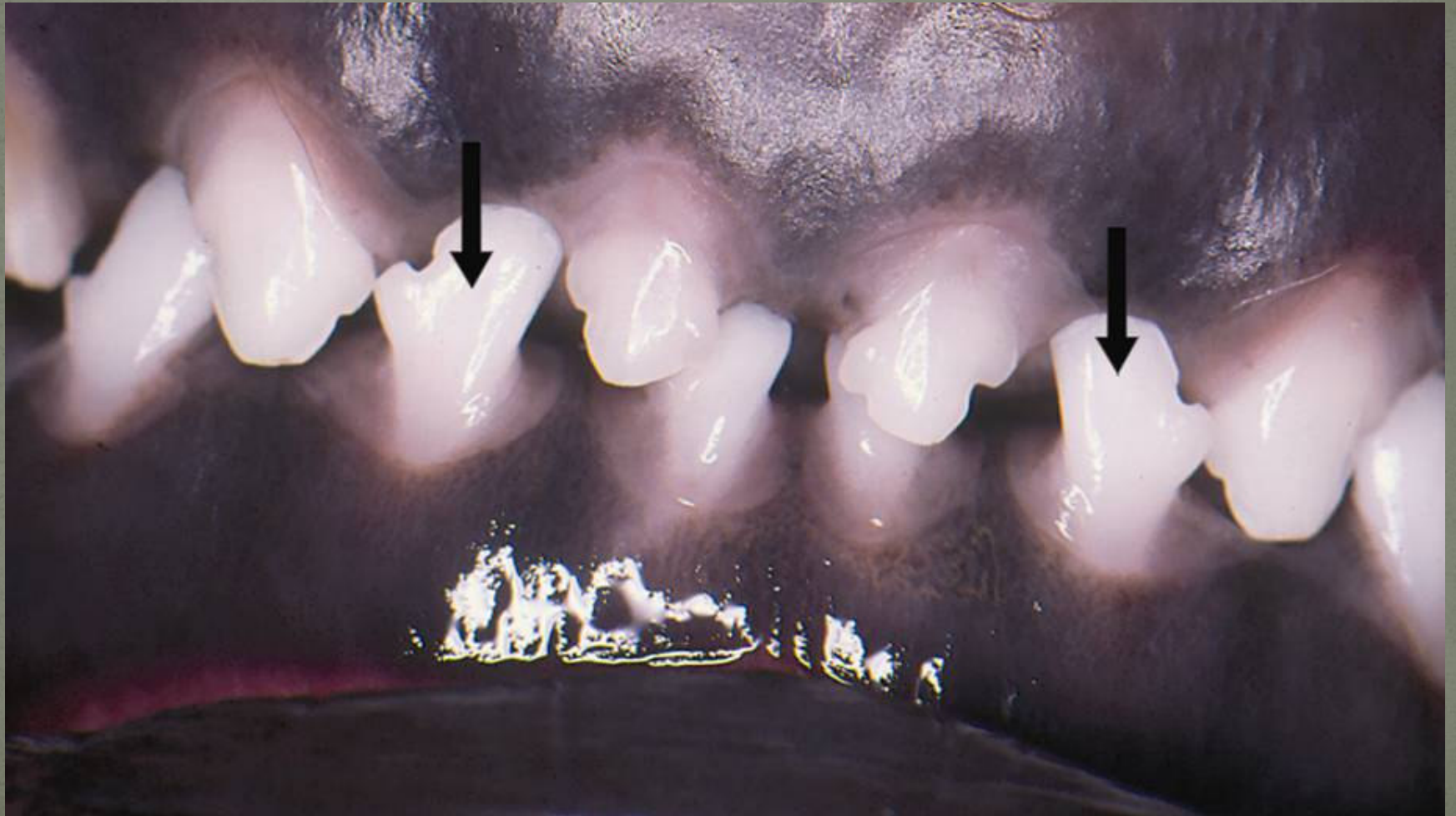
Selective extraction



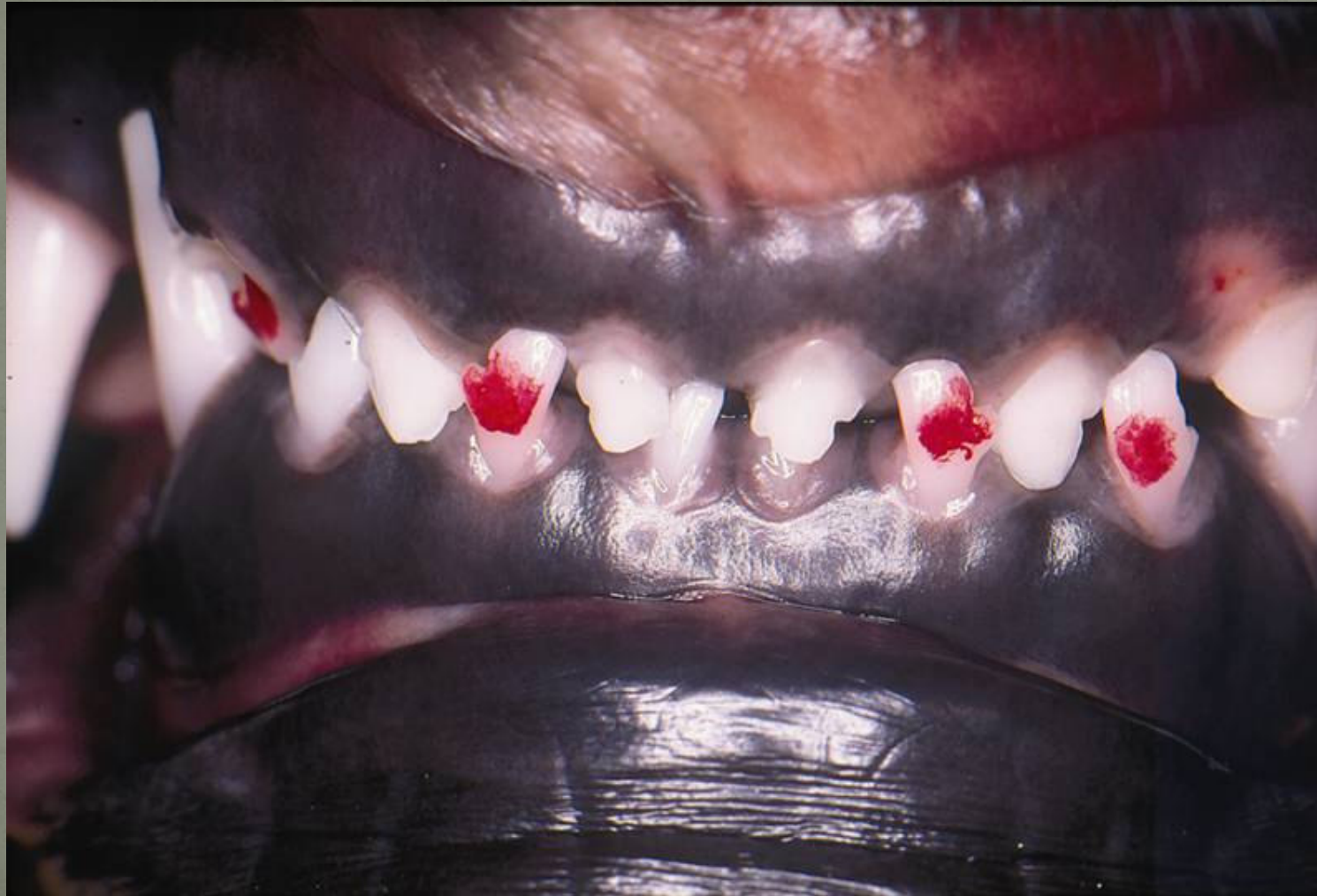



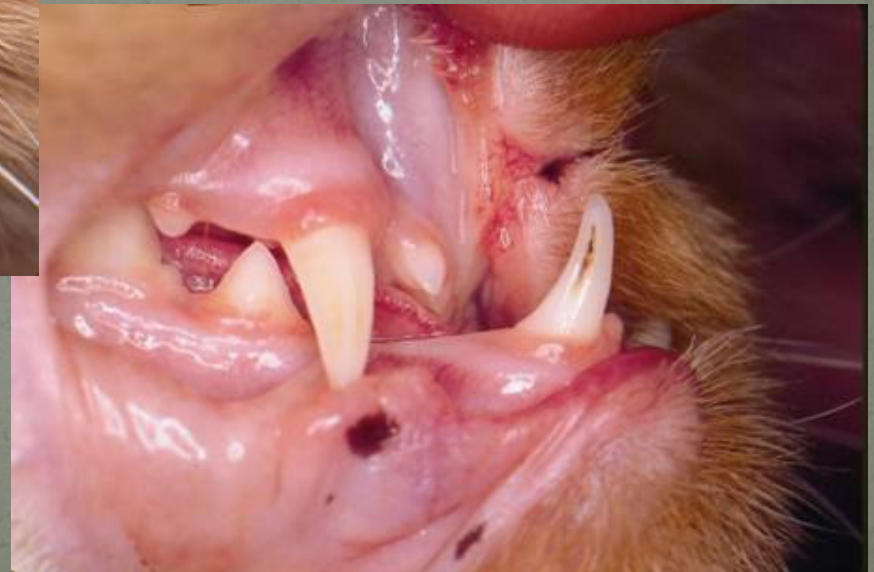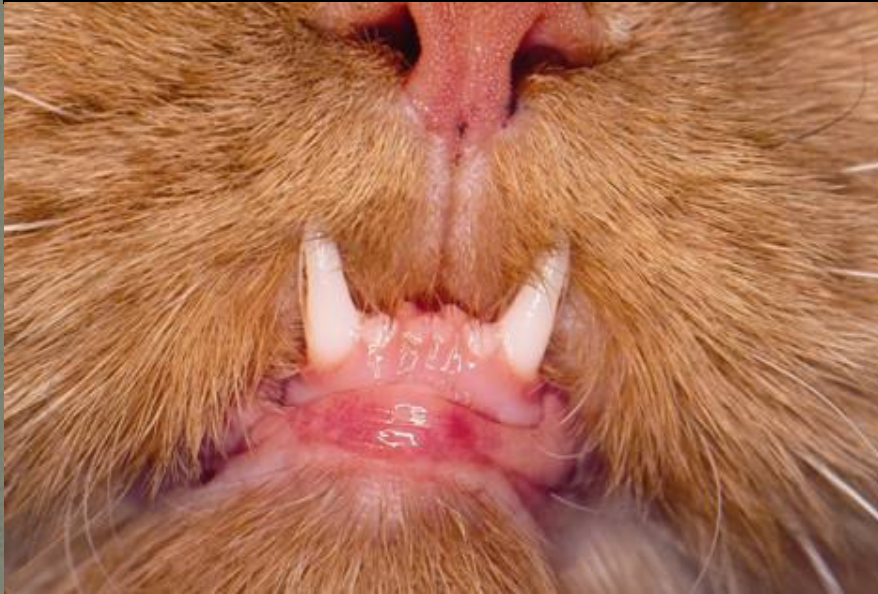Interceptive orthodontics



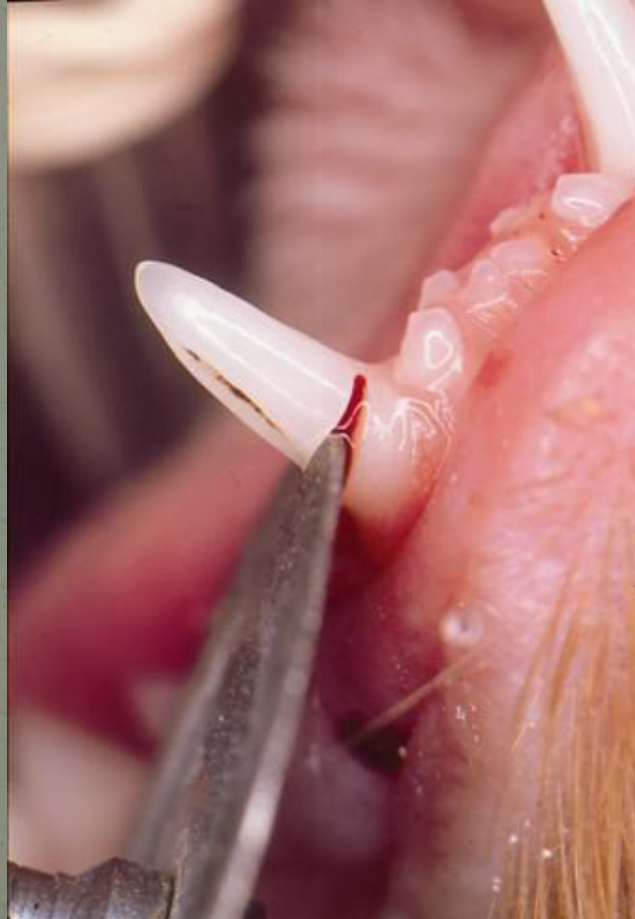Teeth marked for extractions



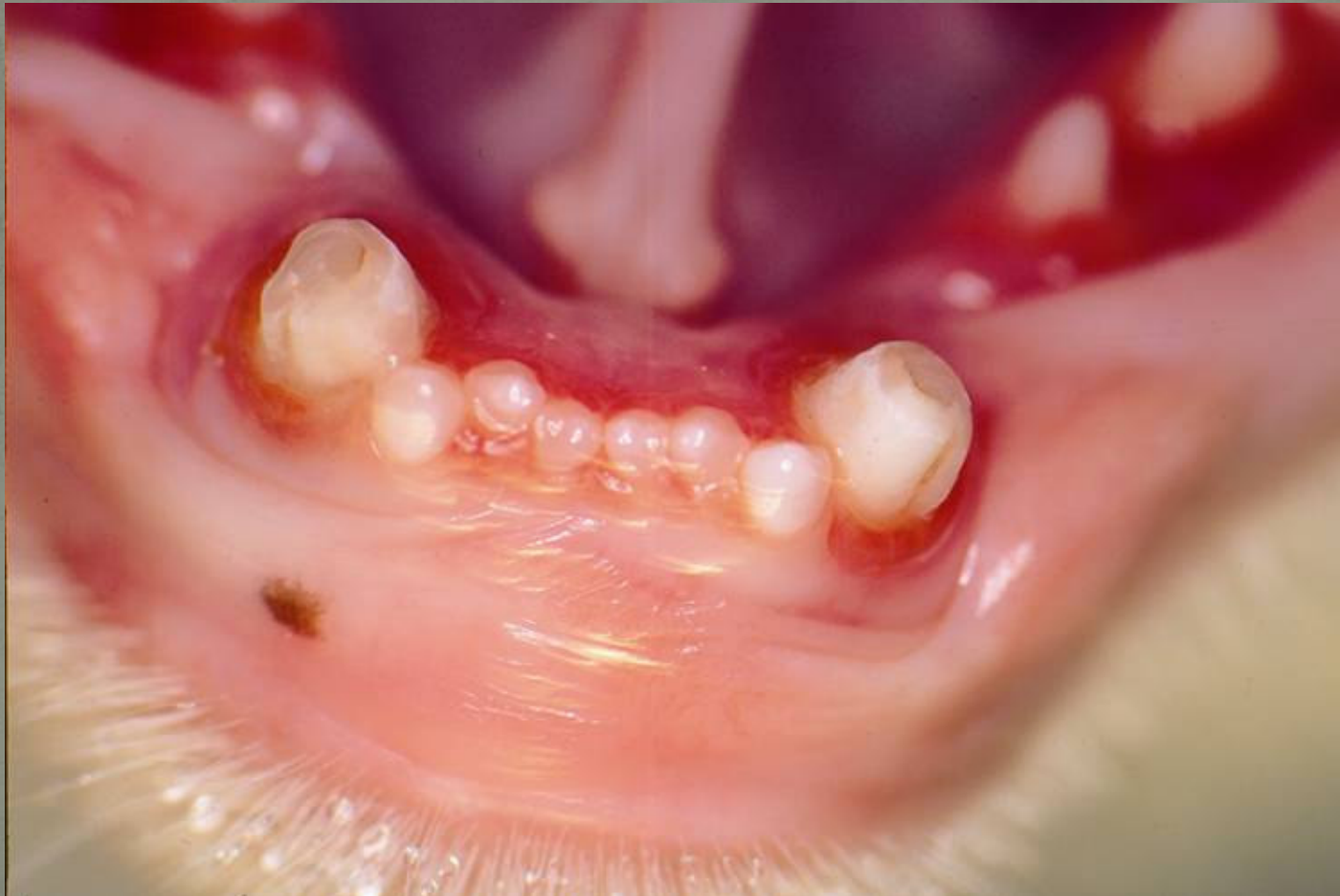Mandibular canines protruding due to mark prognathism (class III malocclusion) in a cat



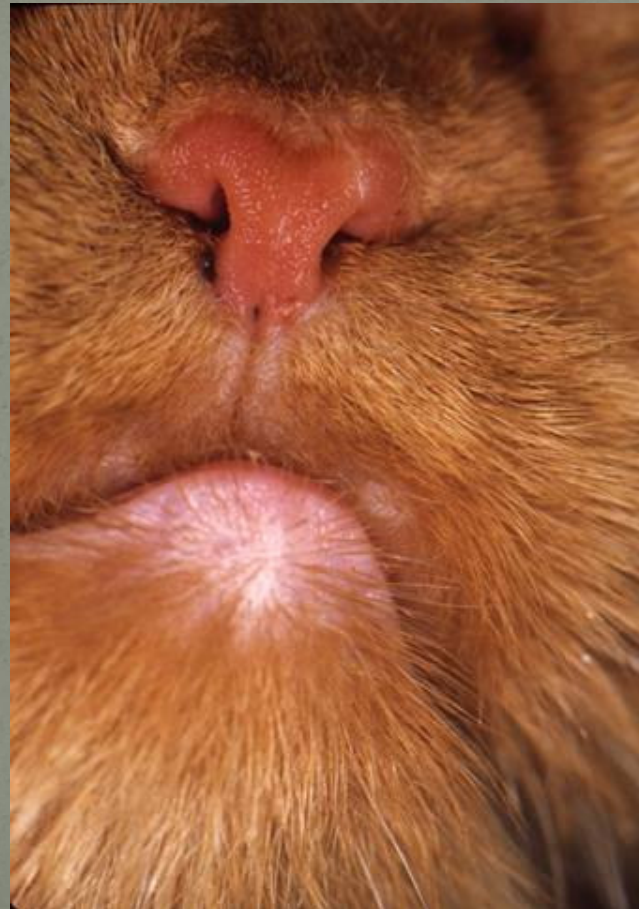
Mandibular canine crown reduction



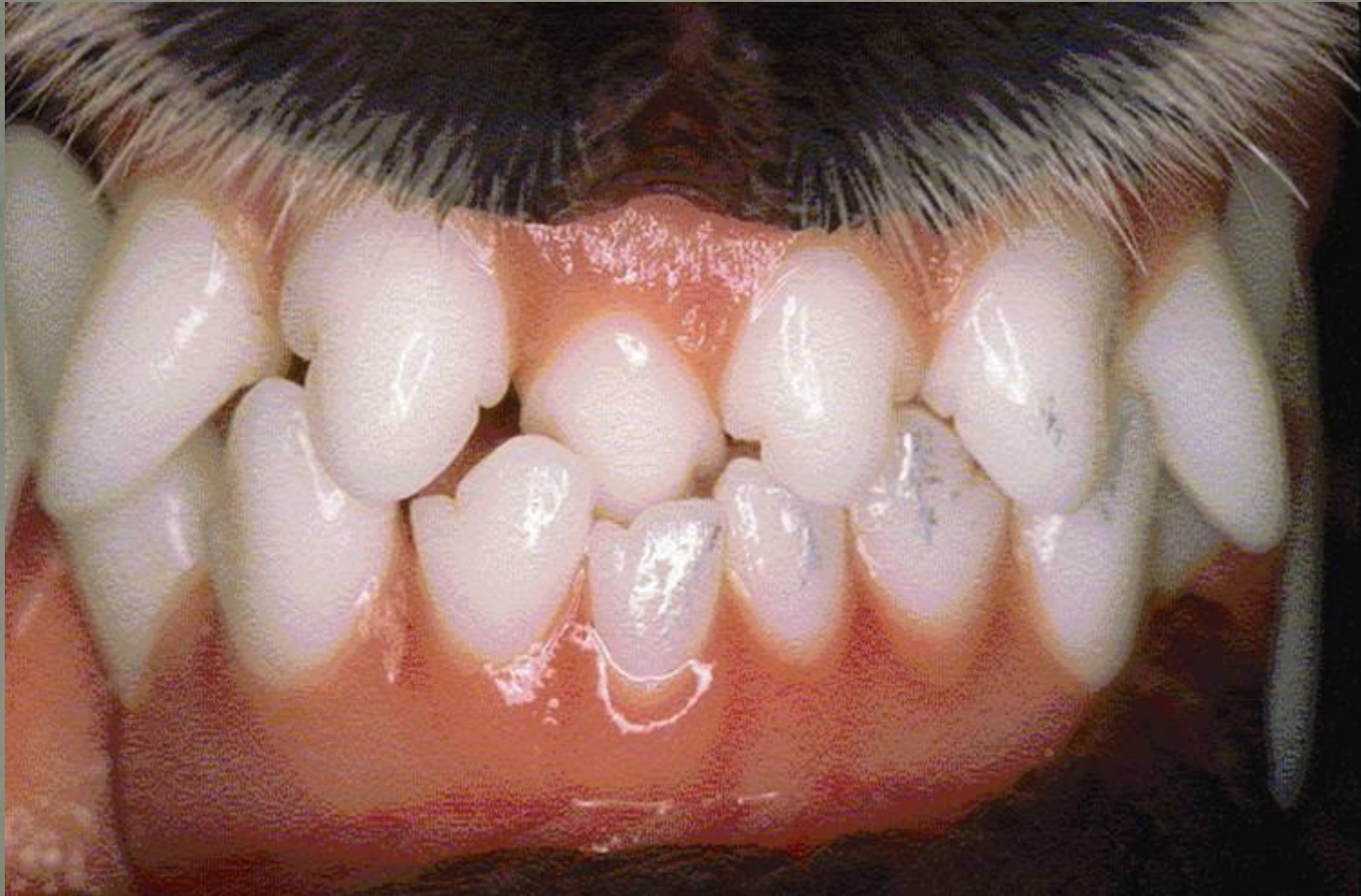Composite restoration of crowns after direct pulp capping of the reduced canines

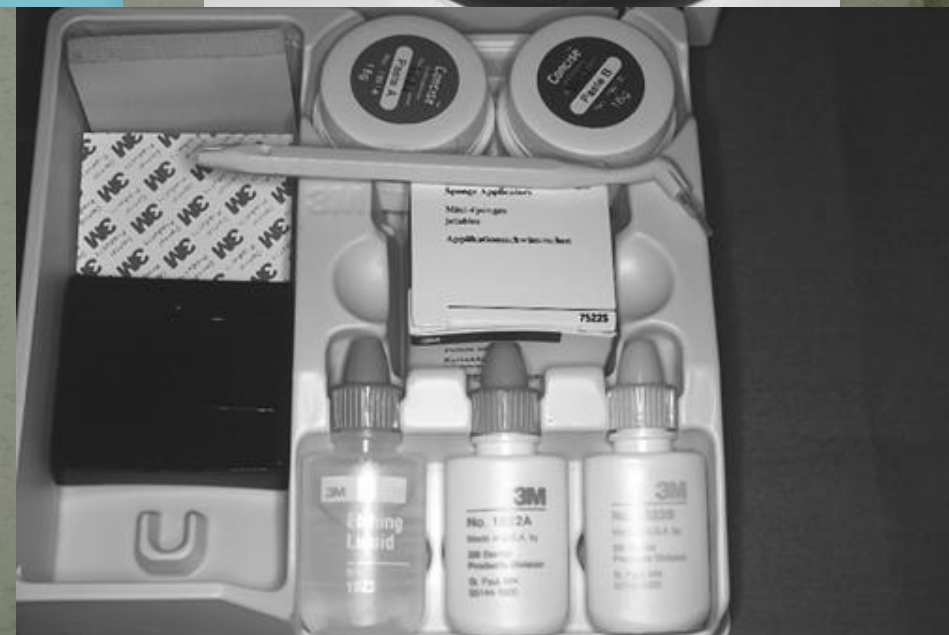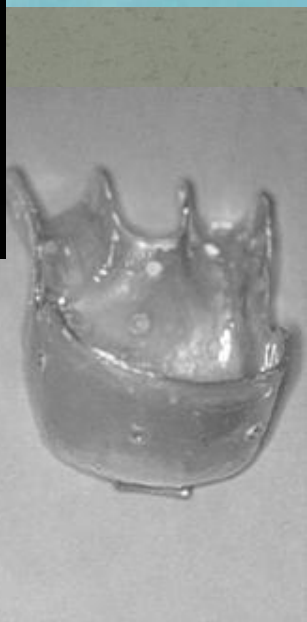

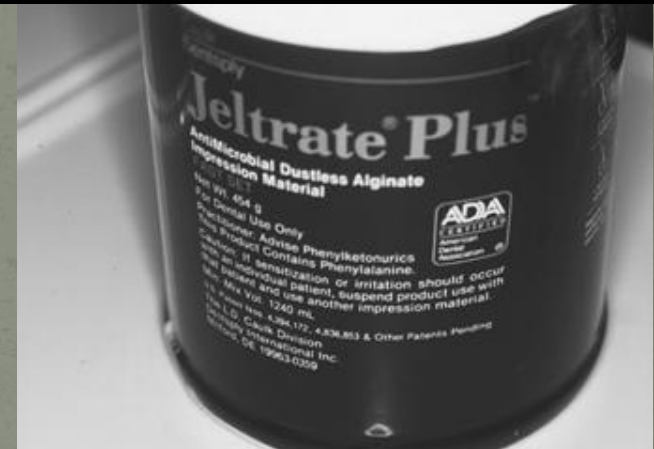
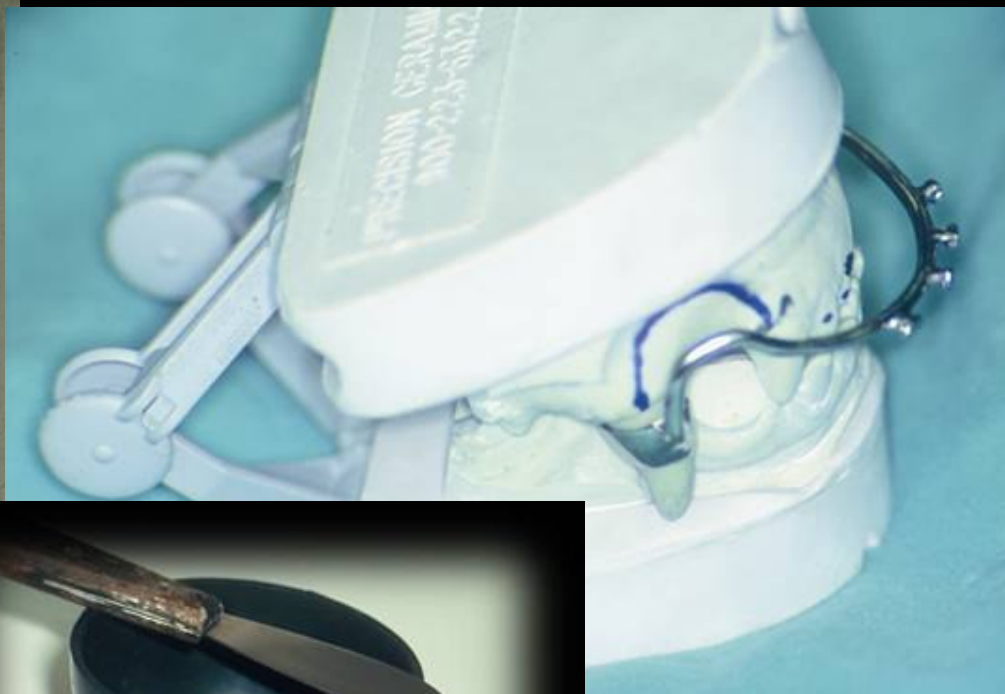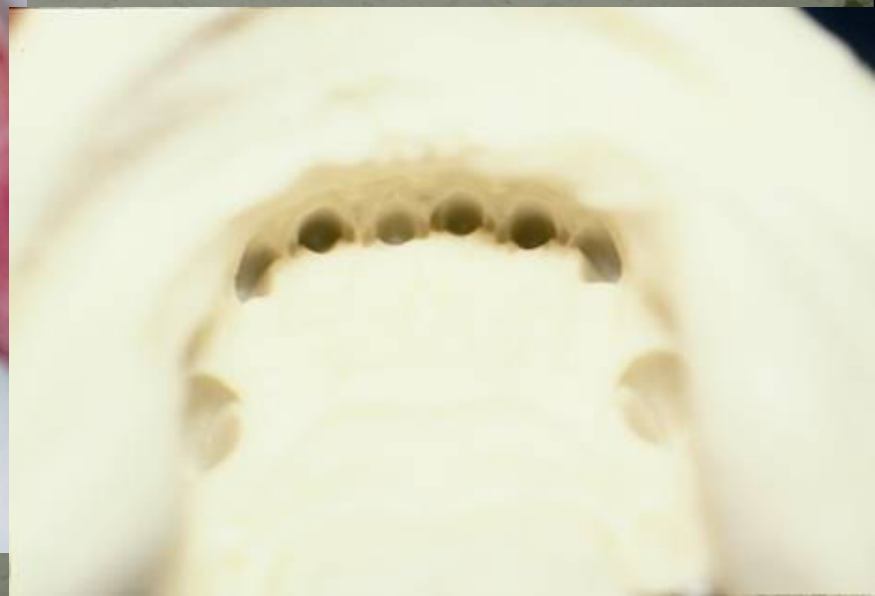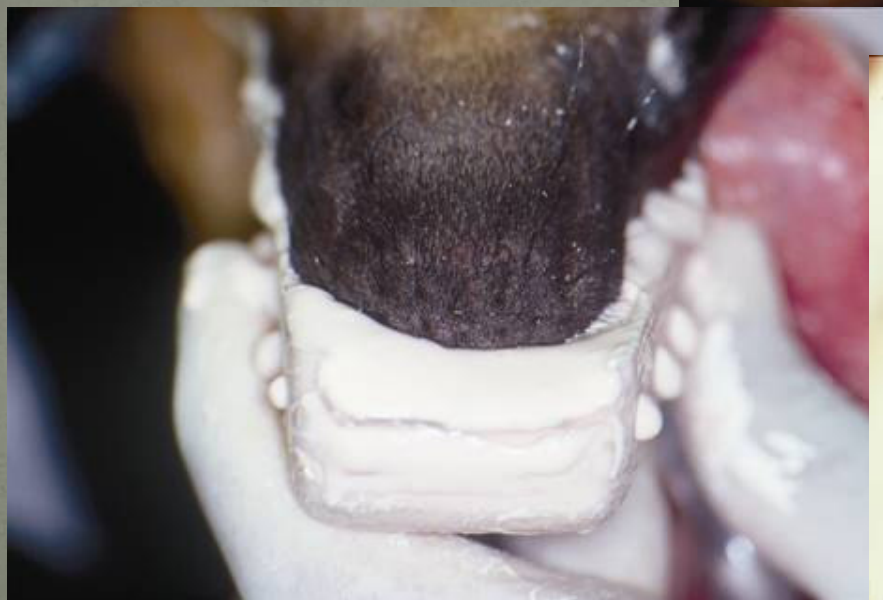Lips closed normally

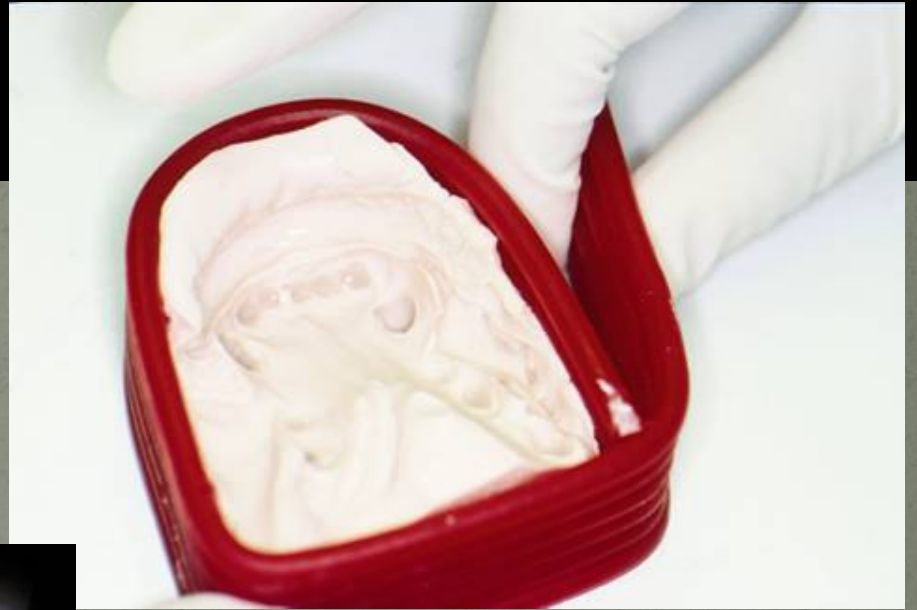

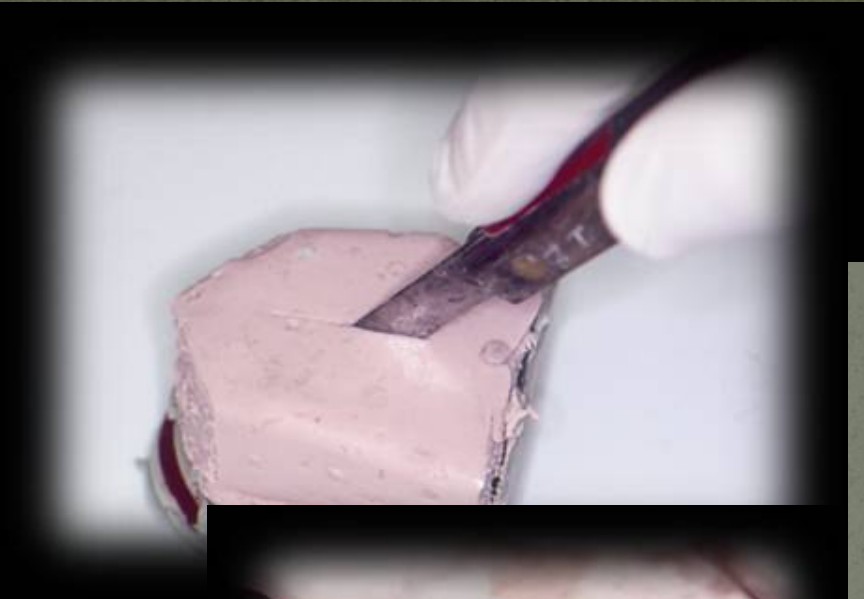
Anterior crossbite

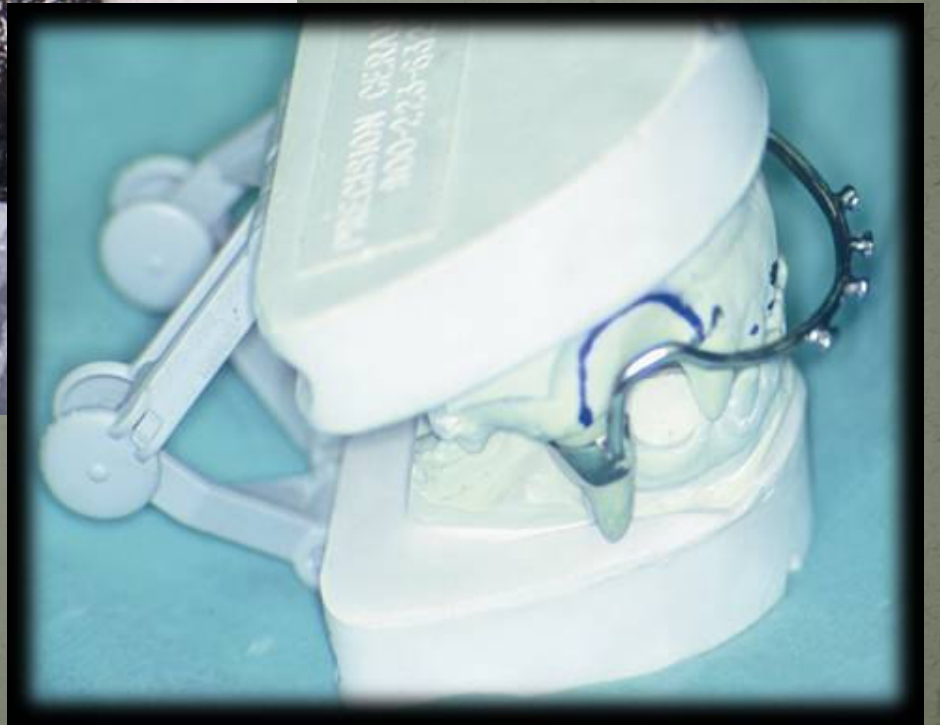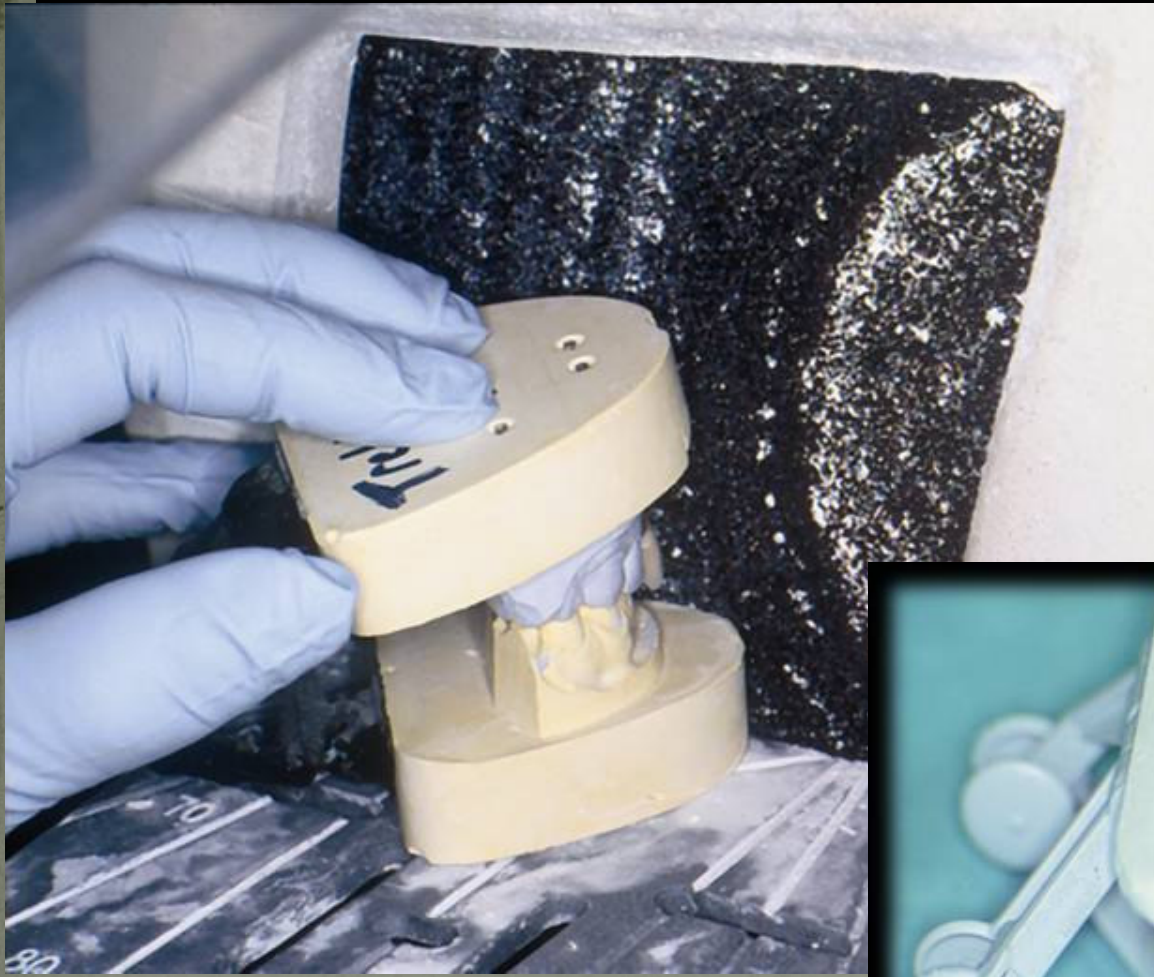



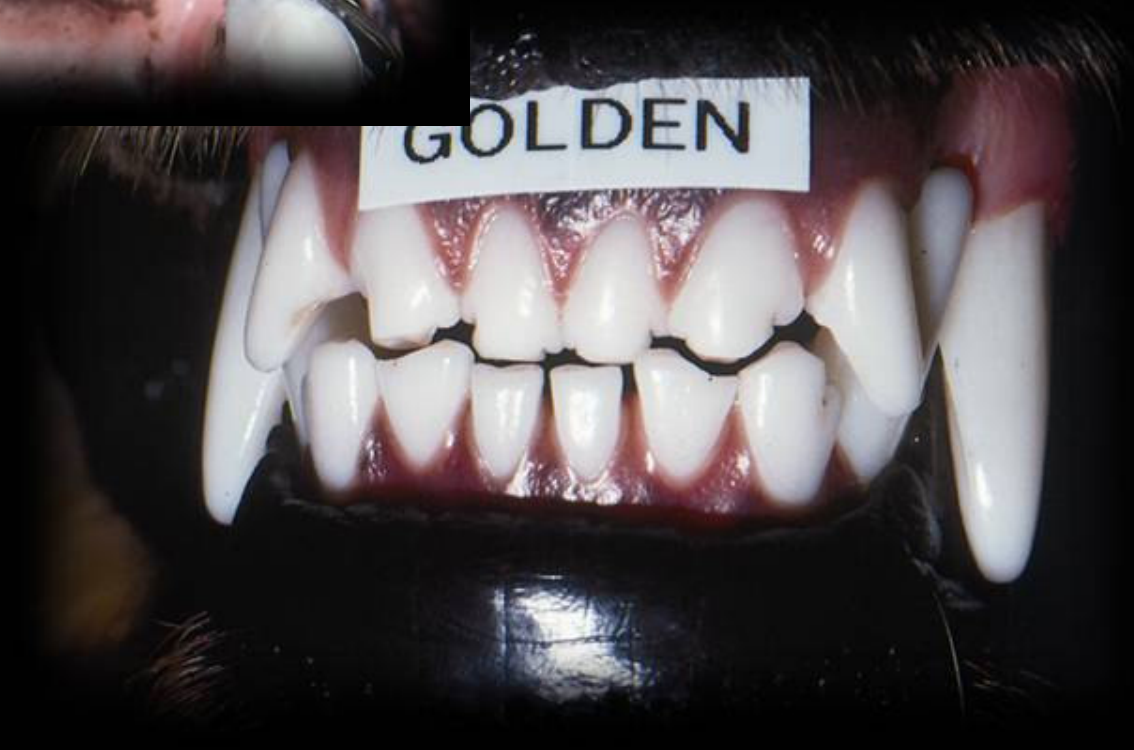
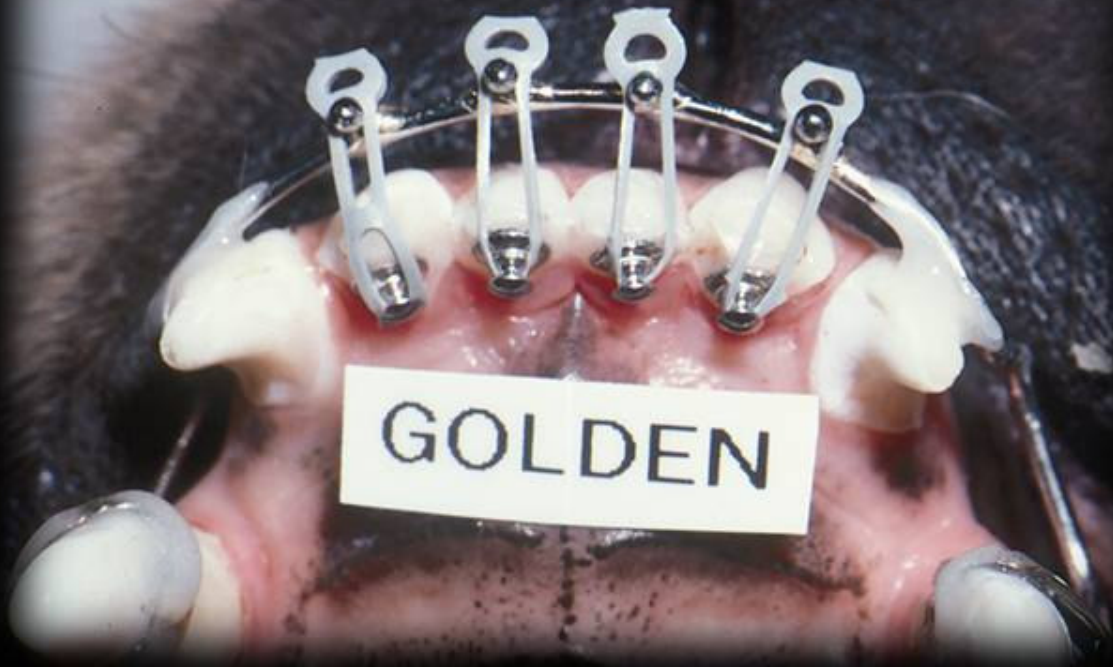




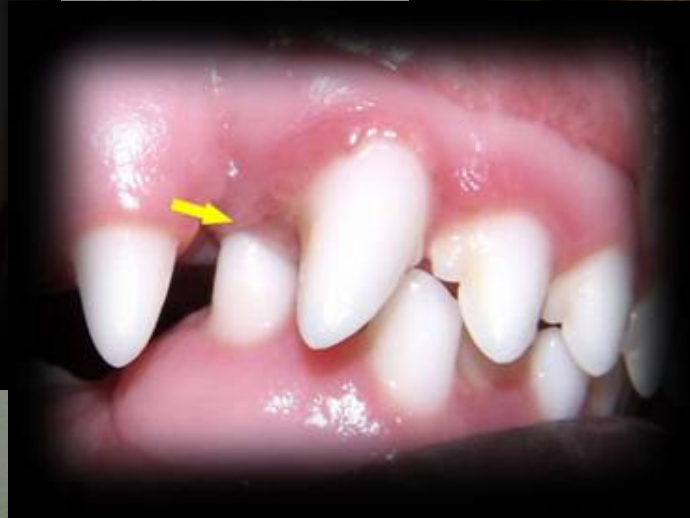
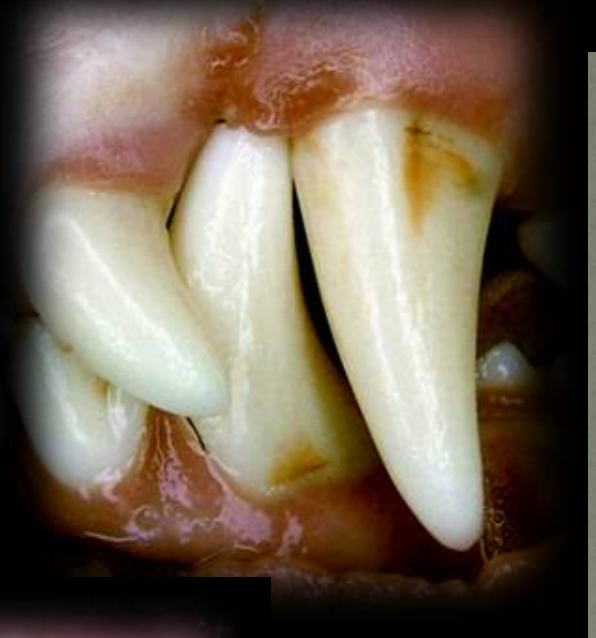
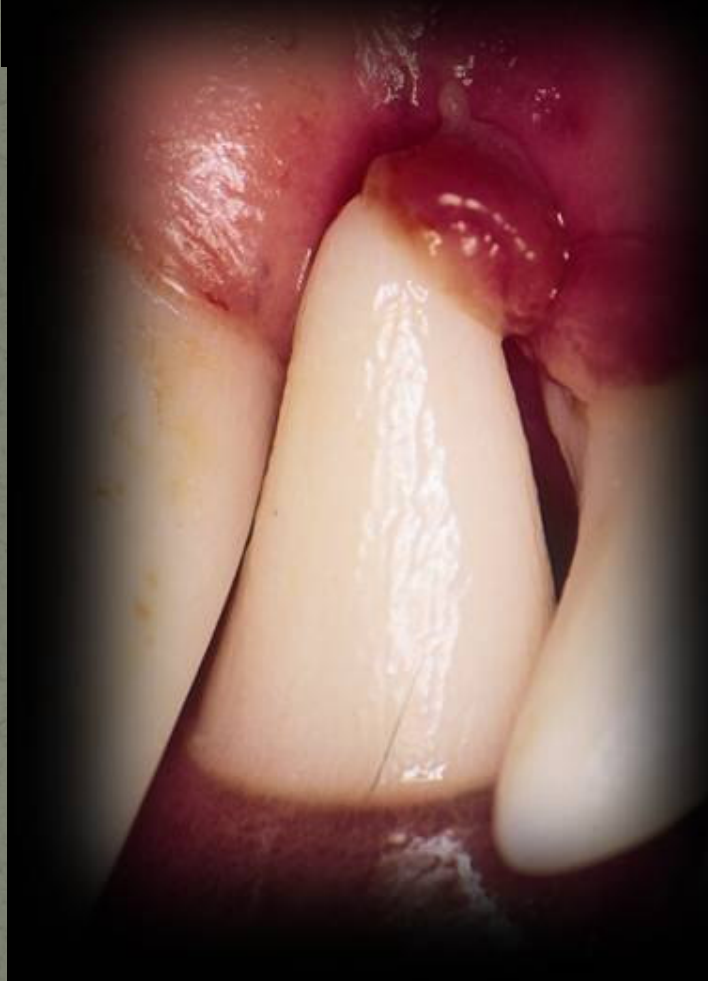




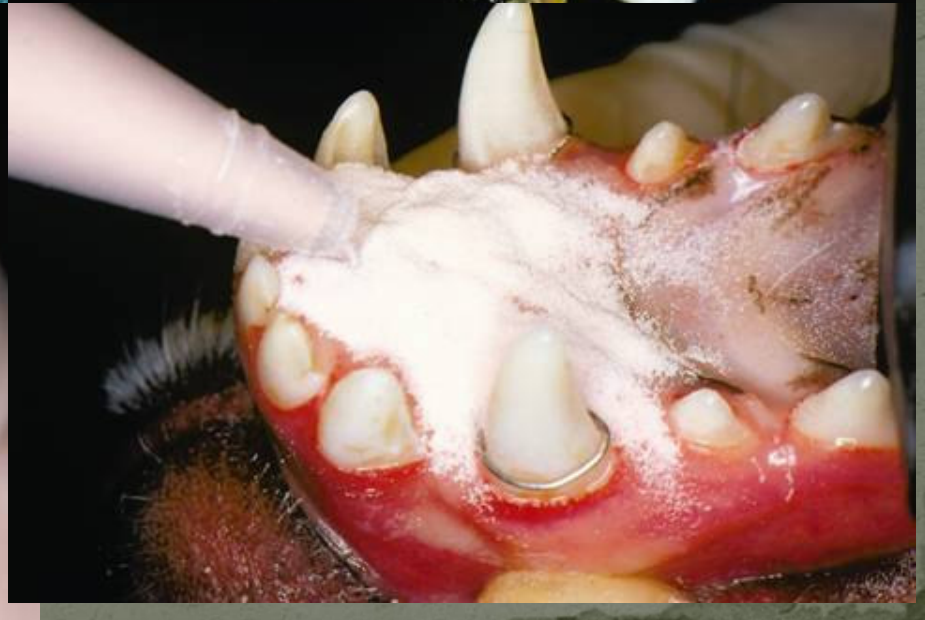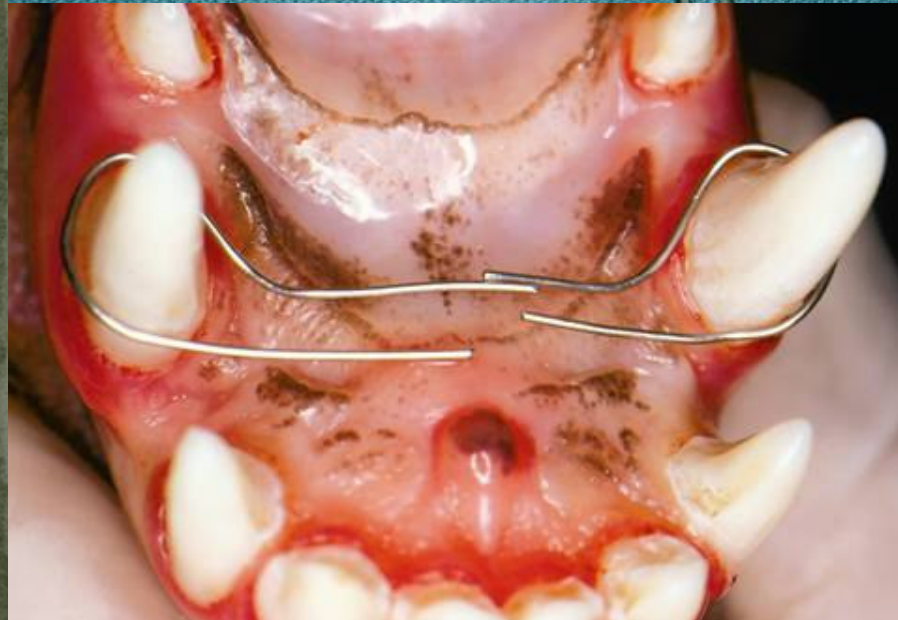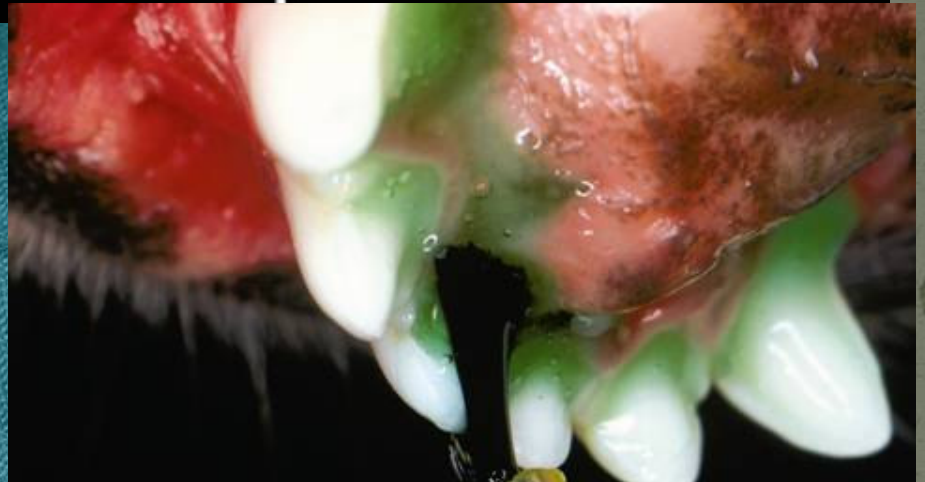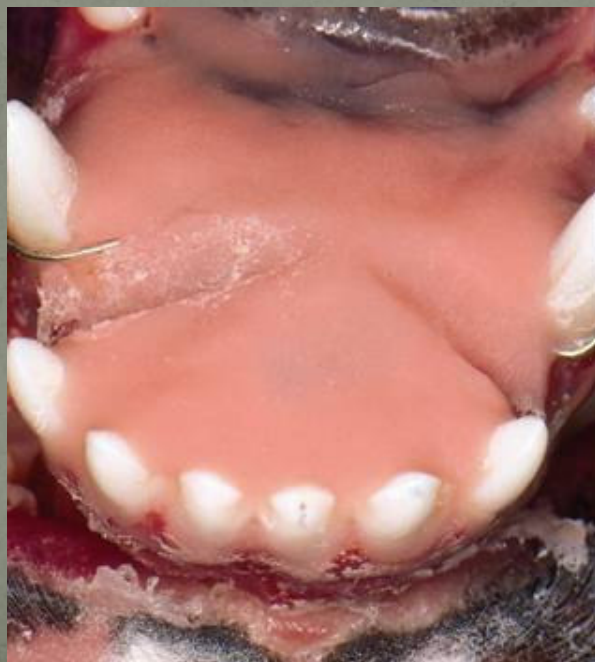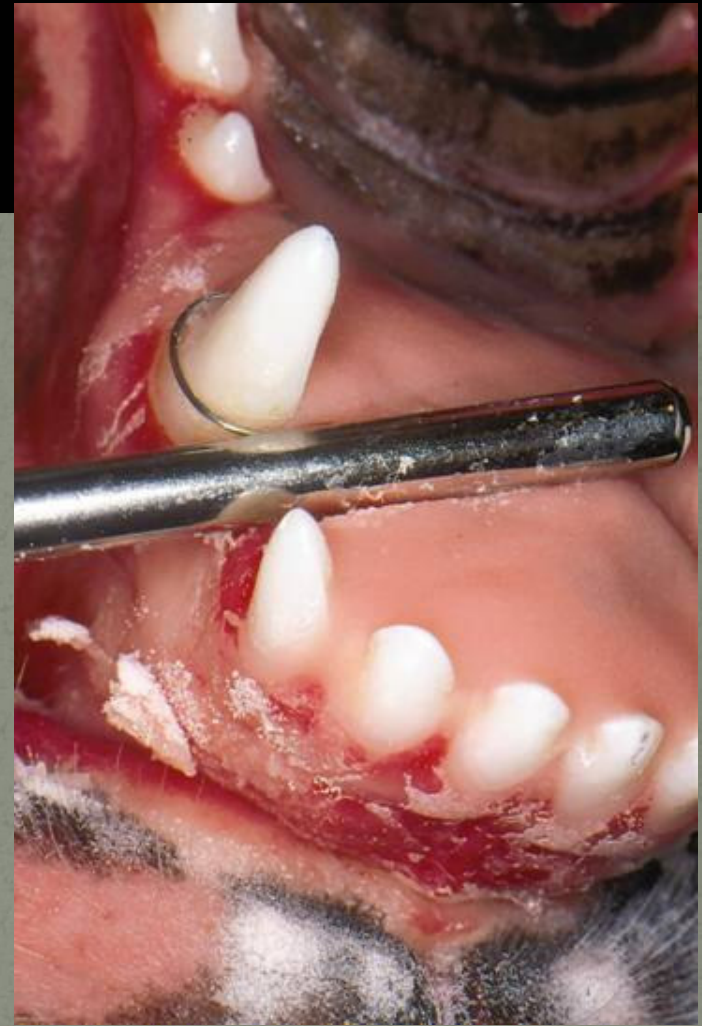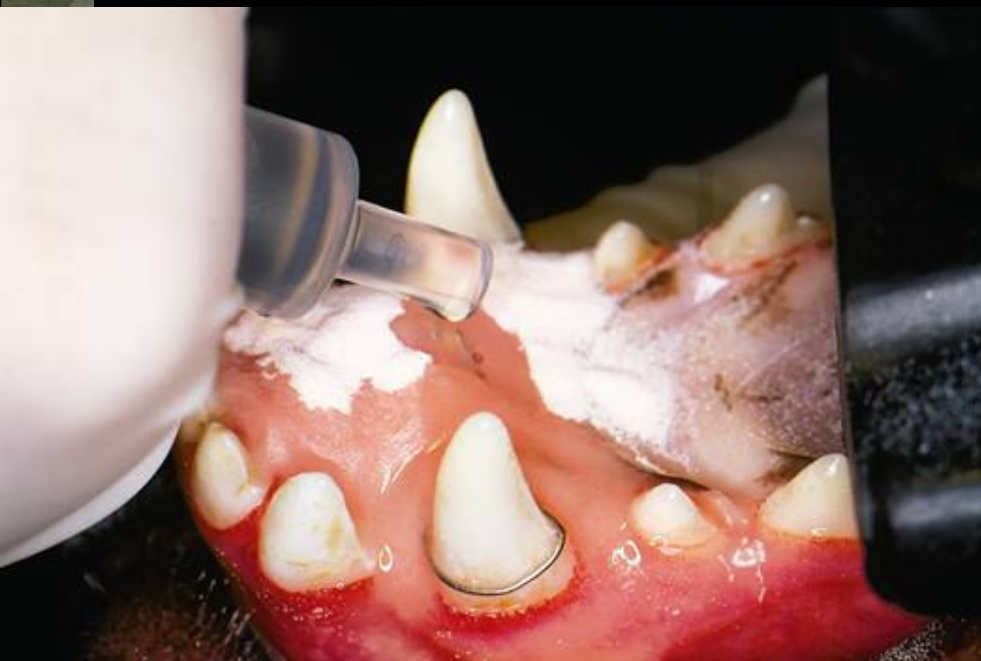Inclined planes to treat ed mand

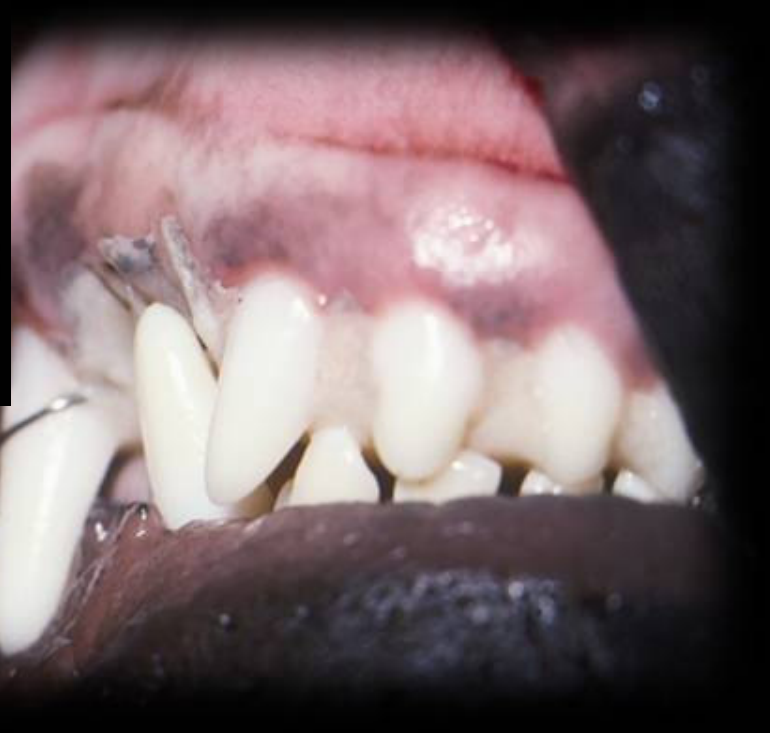
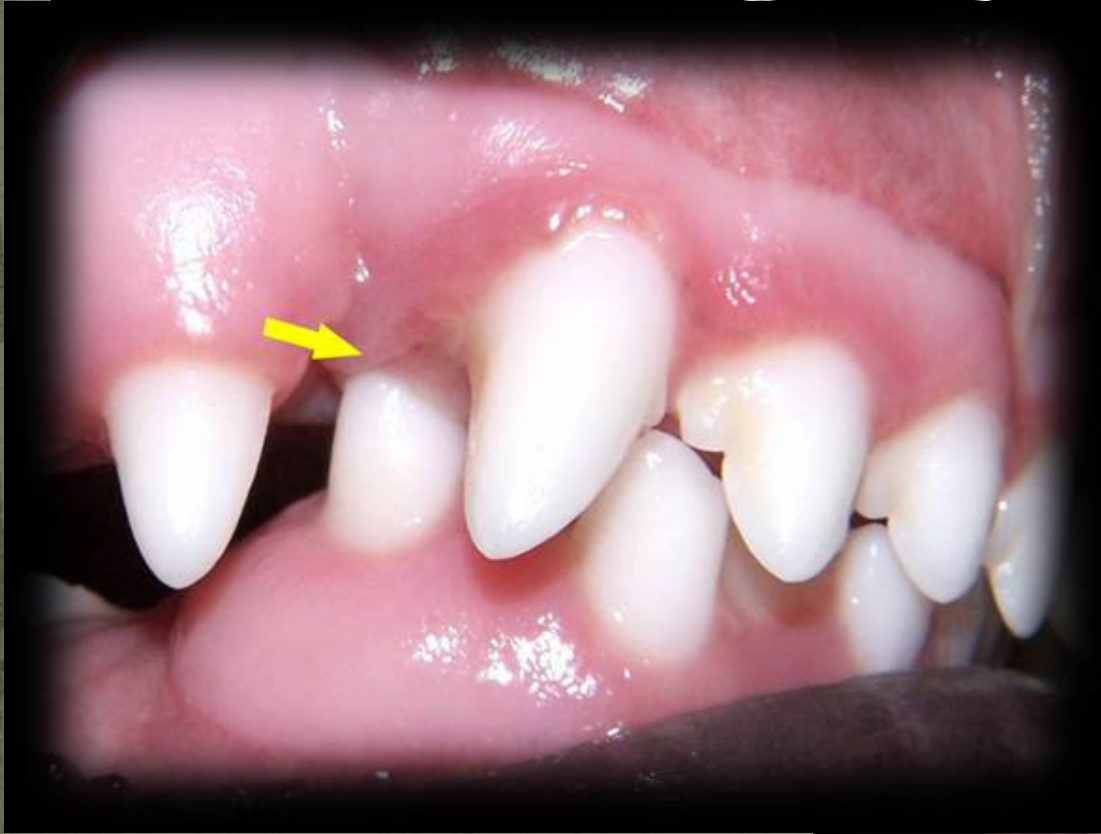

Acrylic inclined plane

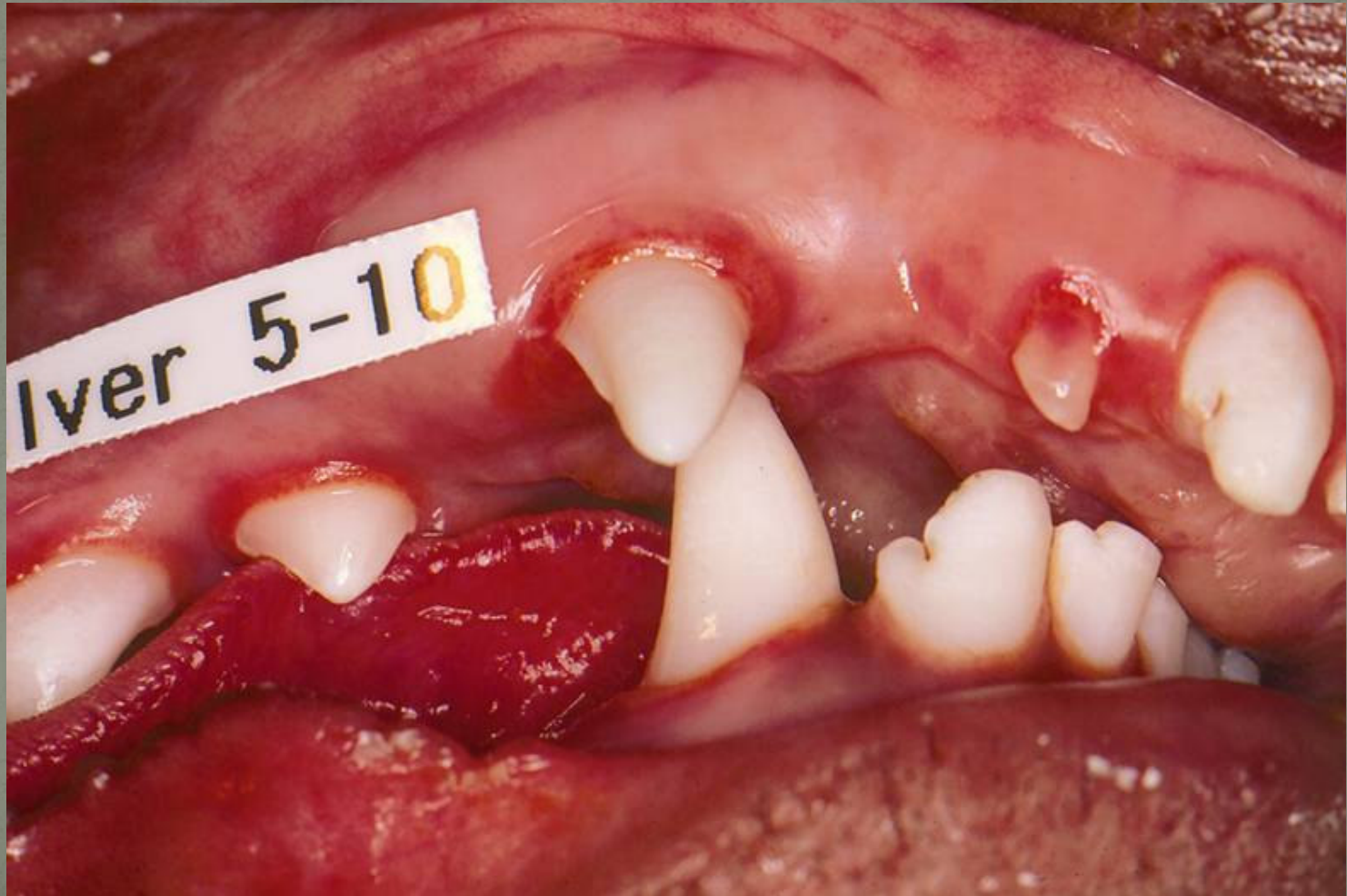



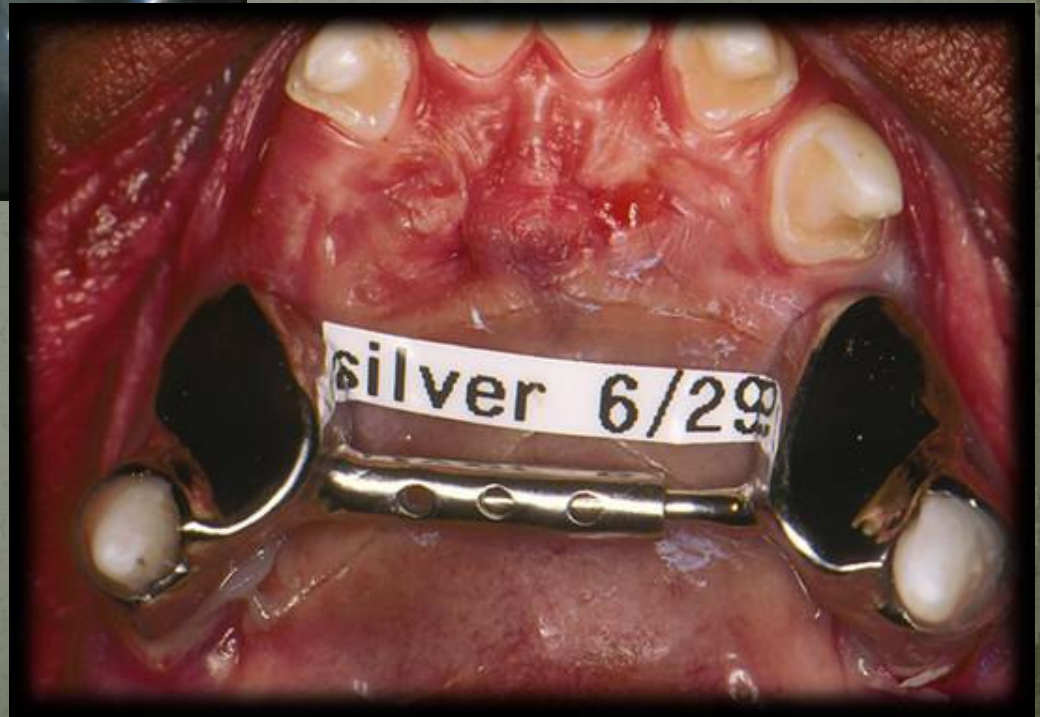Orthodontic correction, after three weeks of treatment, using an acrylic inclined plane



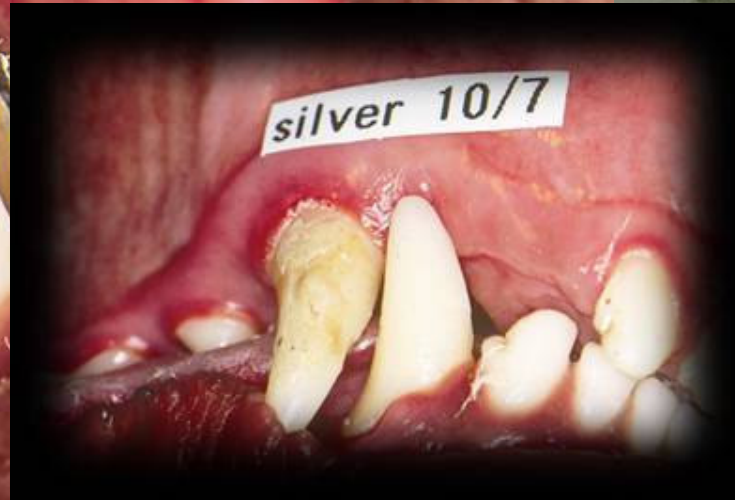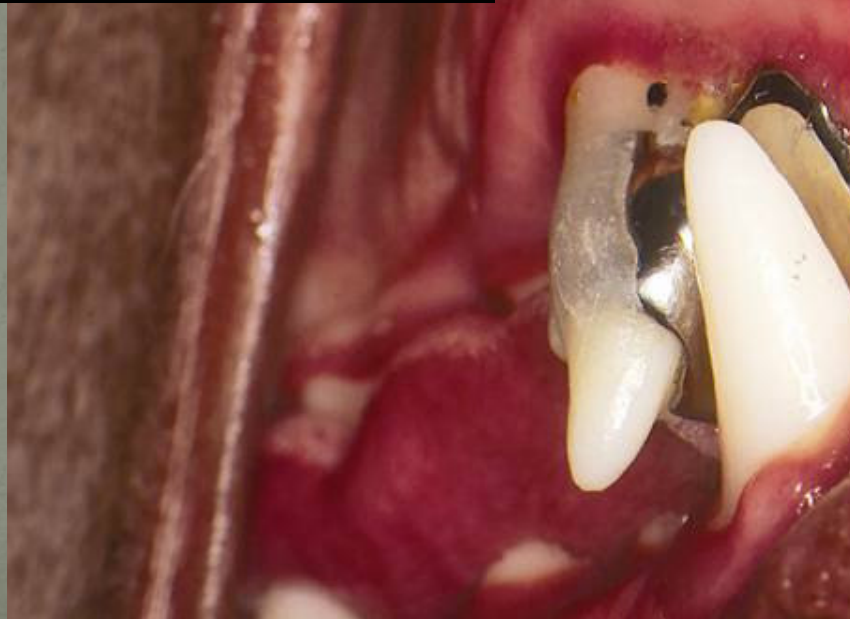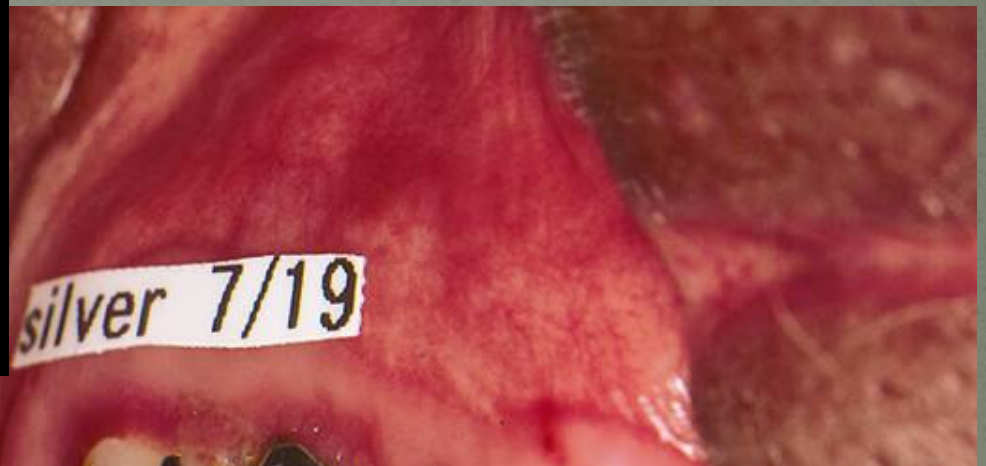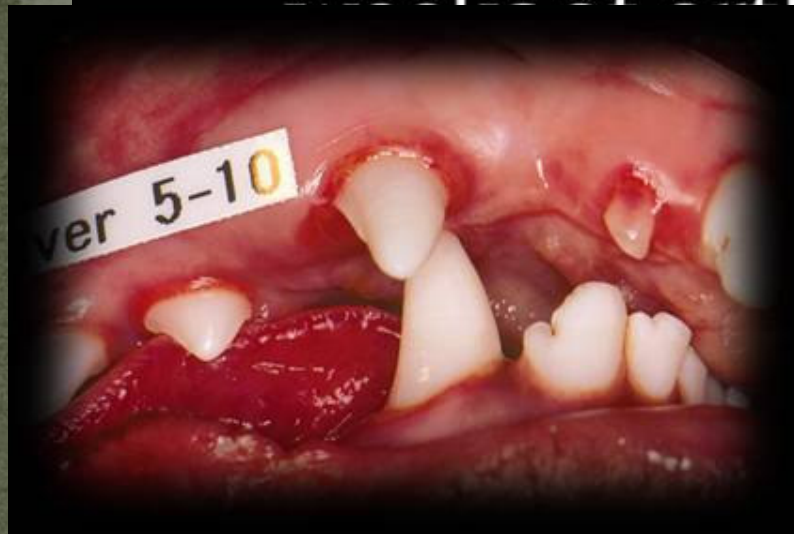Telescoping inclined plane



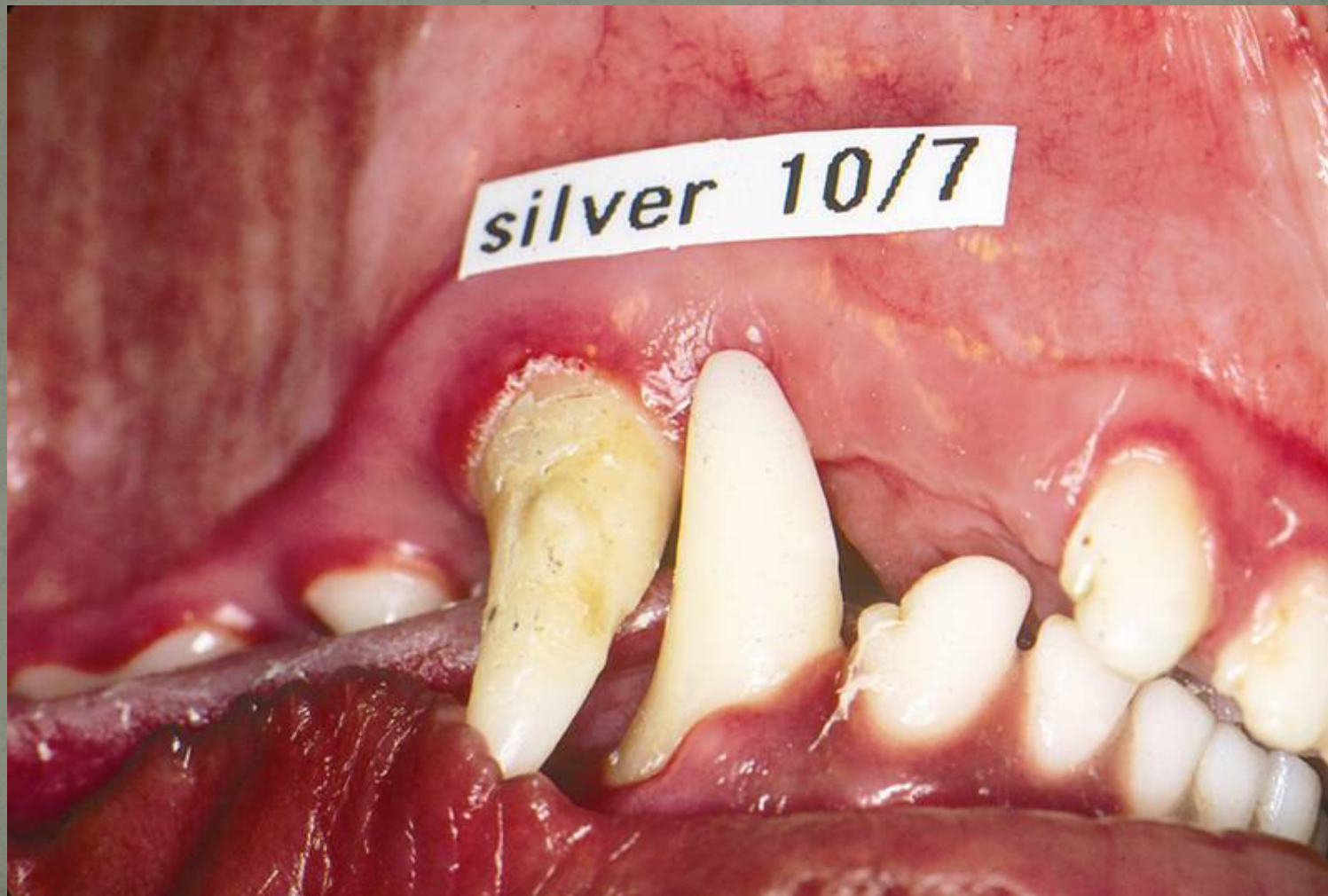Cast metal inclined plane with telescoping bar



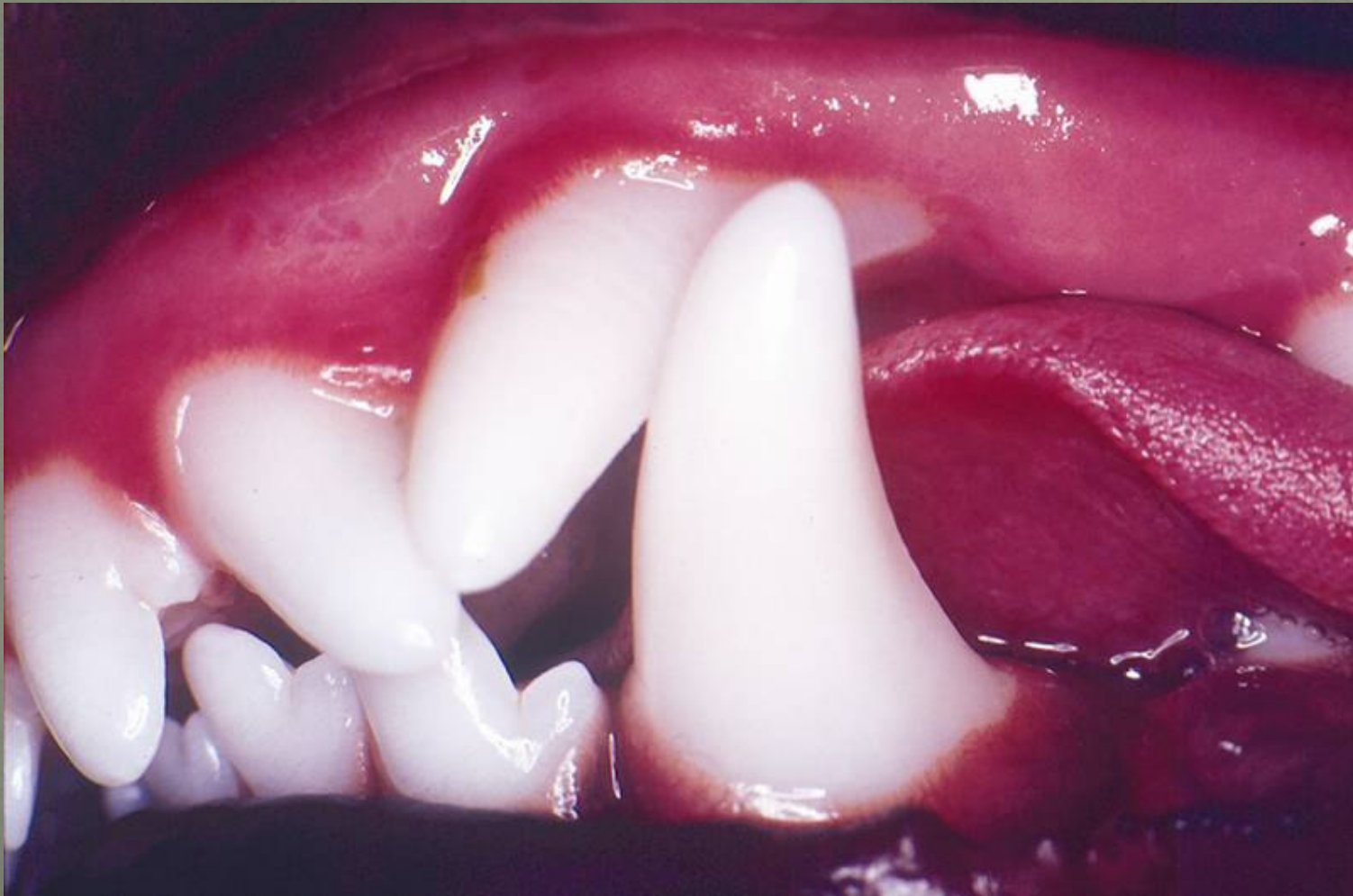Lingually displaced canines after 10 months of orthodontic correction

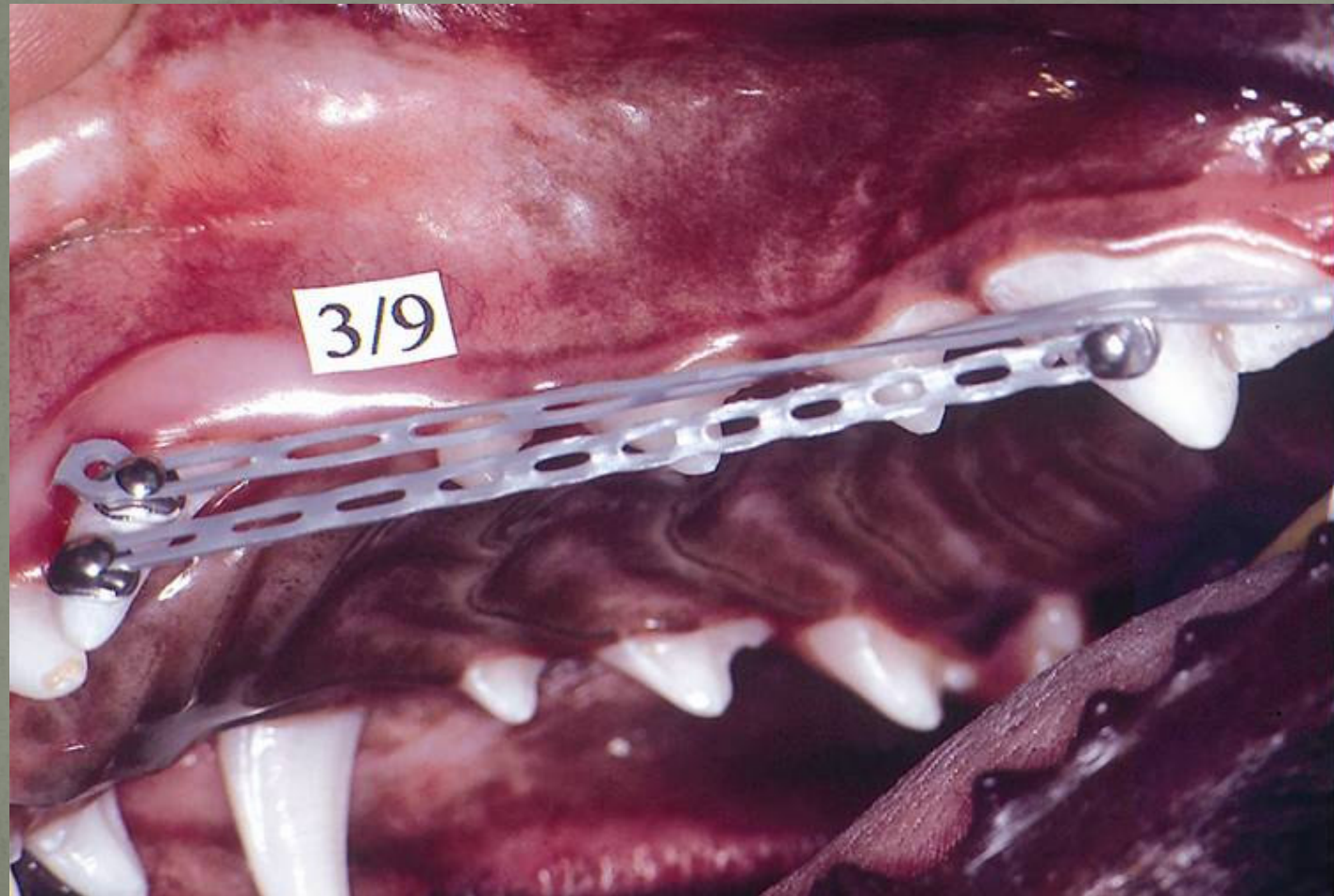


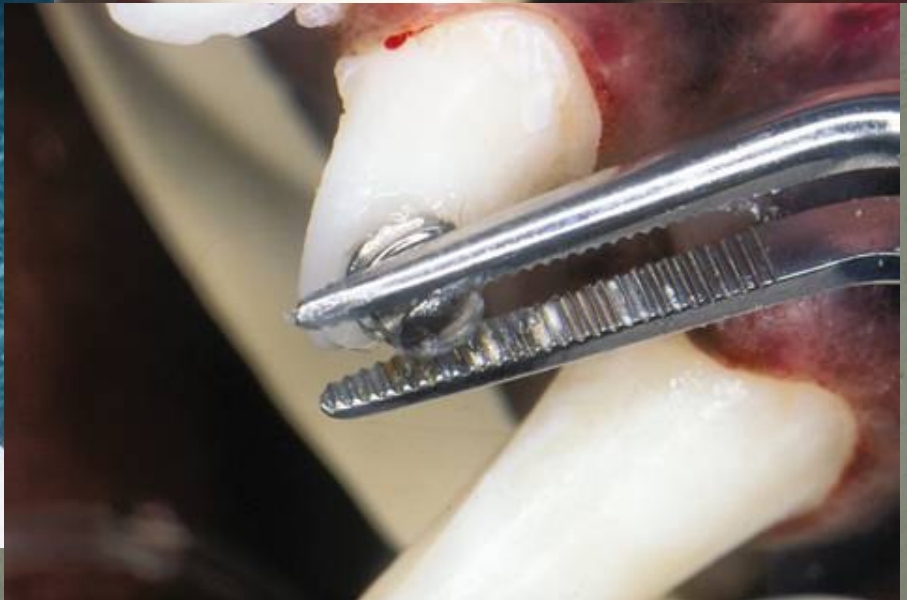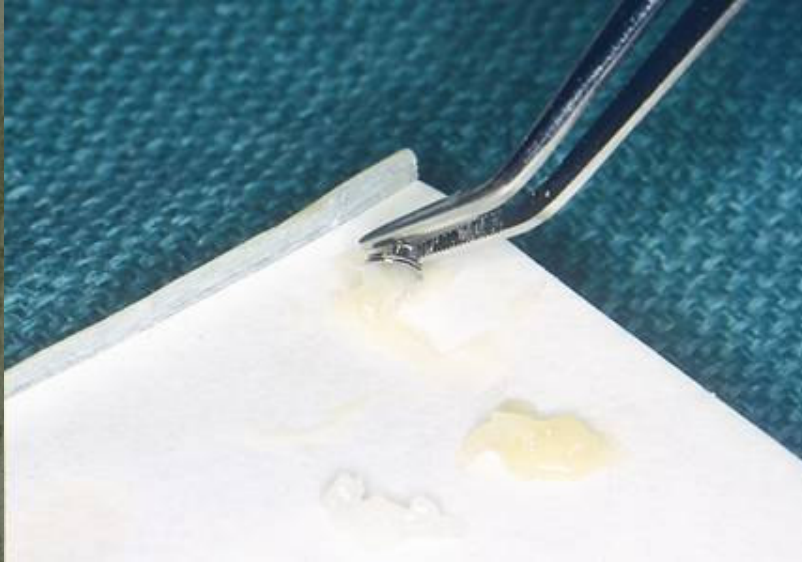
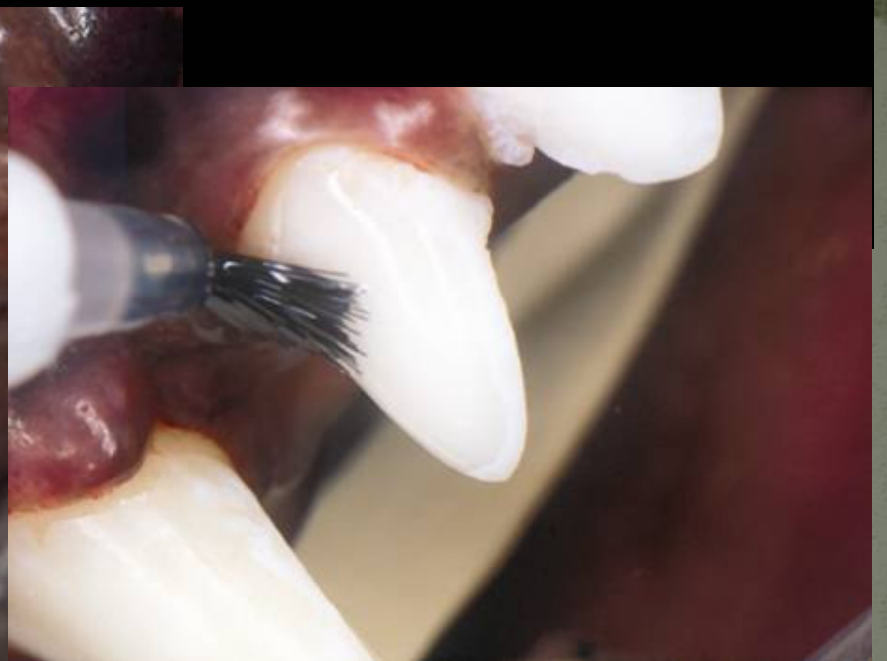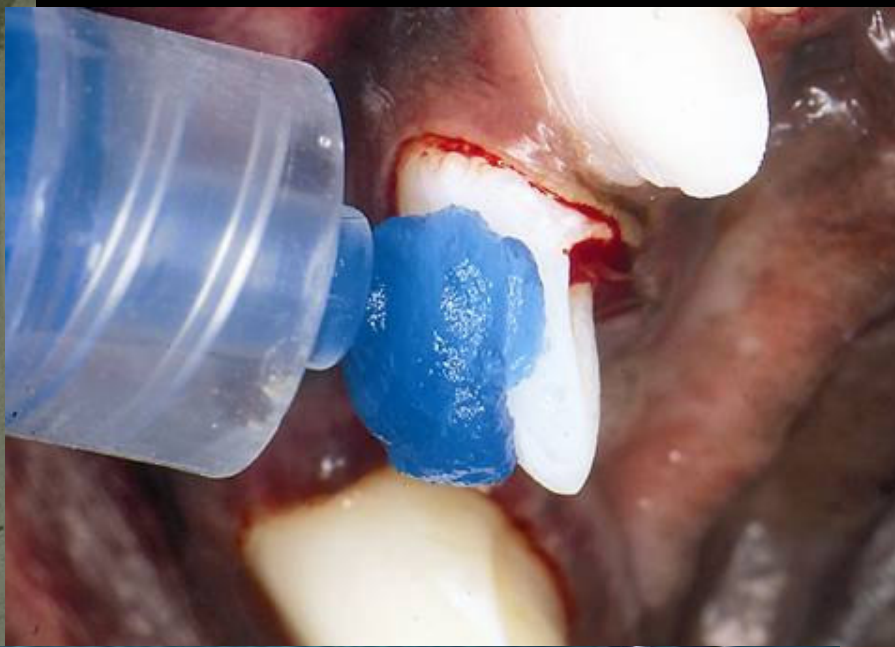Right mandibular canine moved labially
by inclined plane

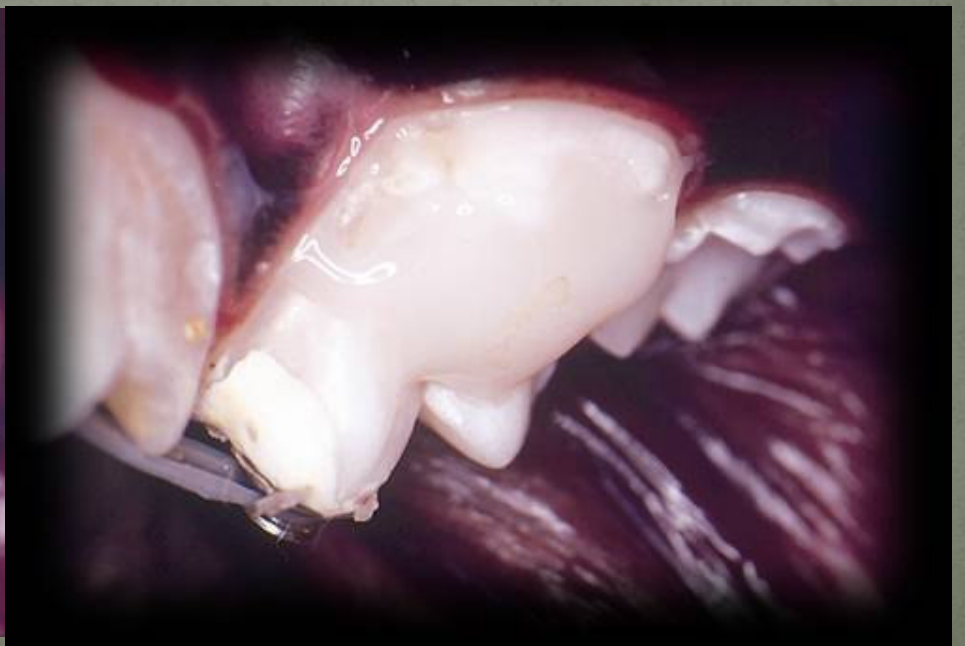
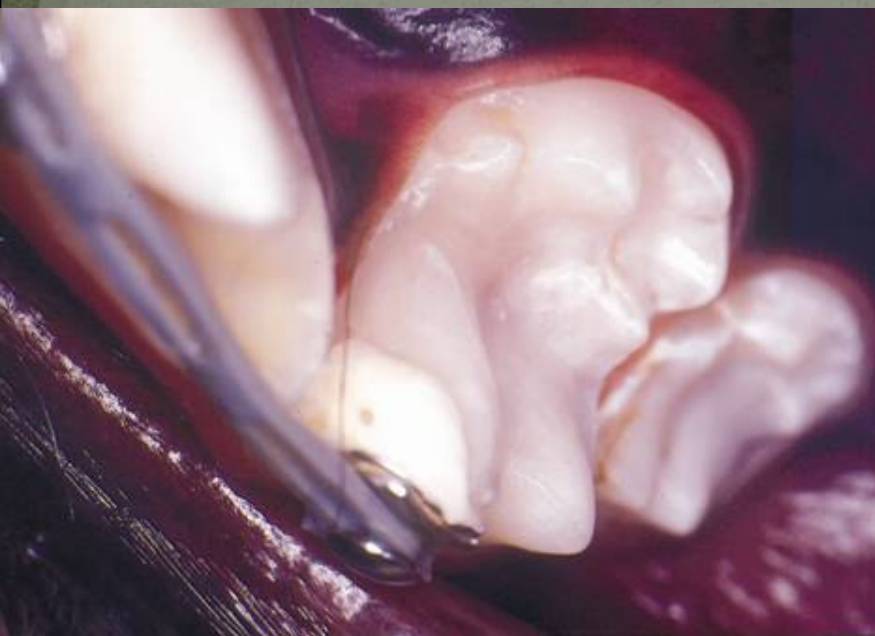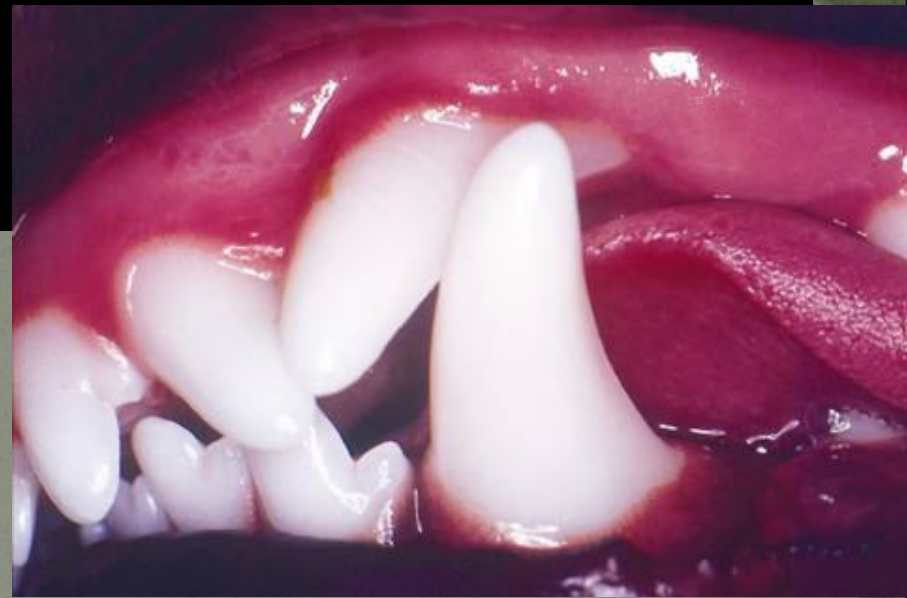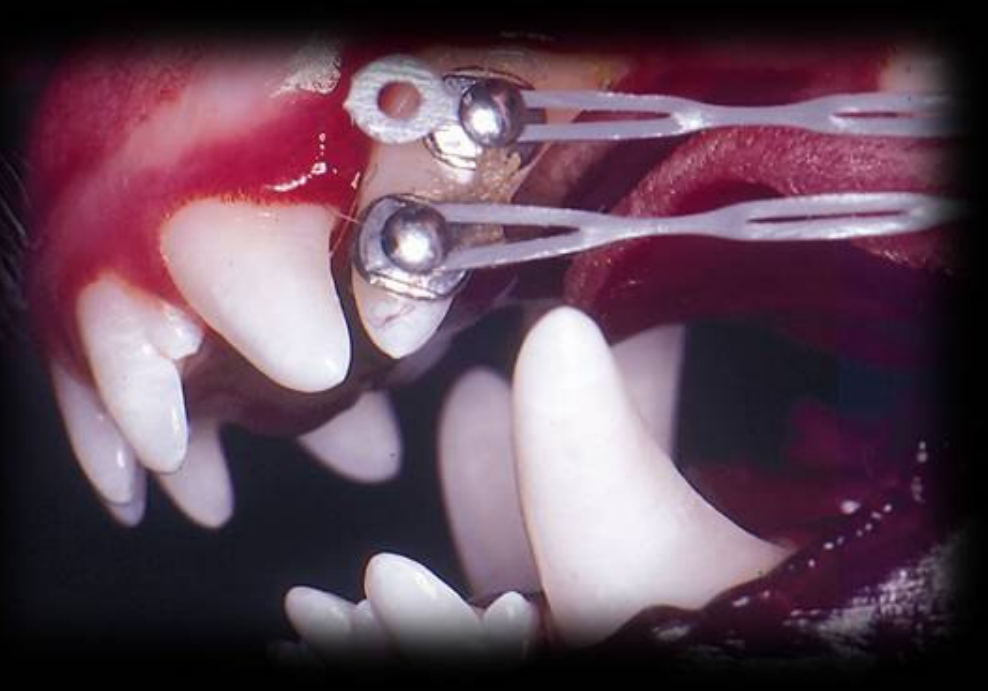


Orthodontic buttons and elastics

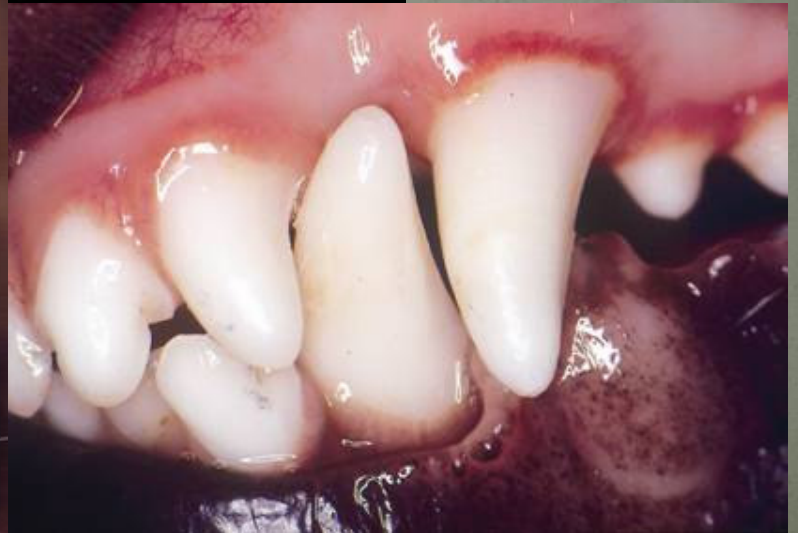
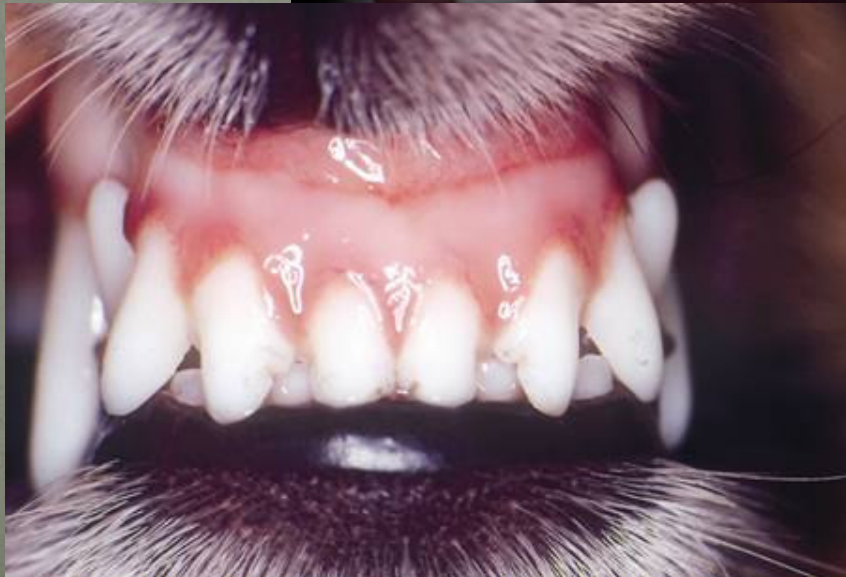
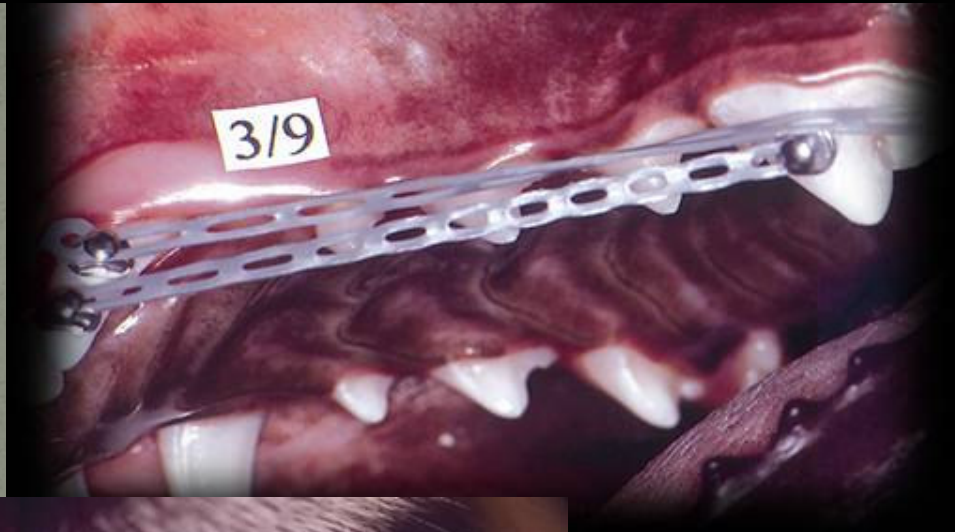



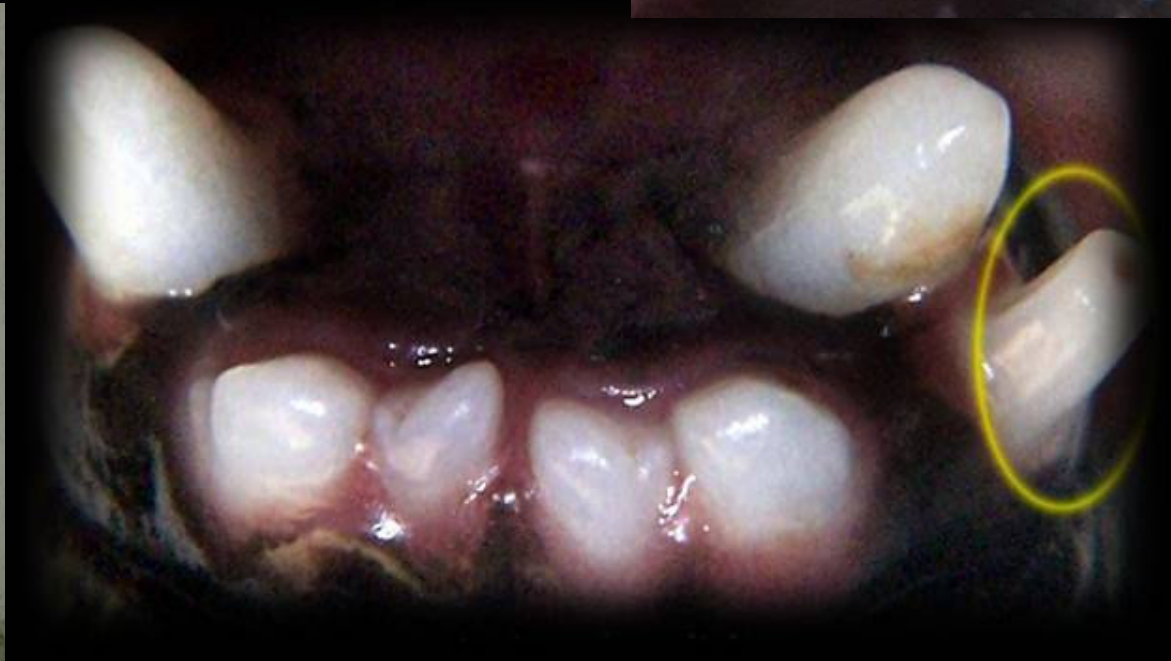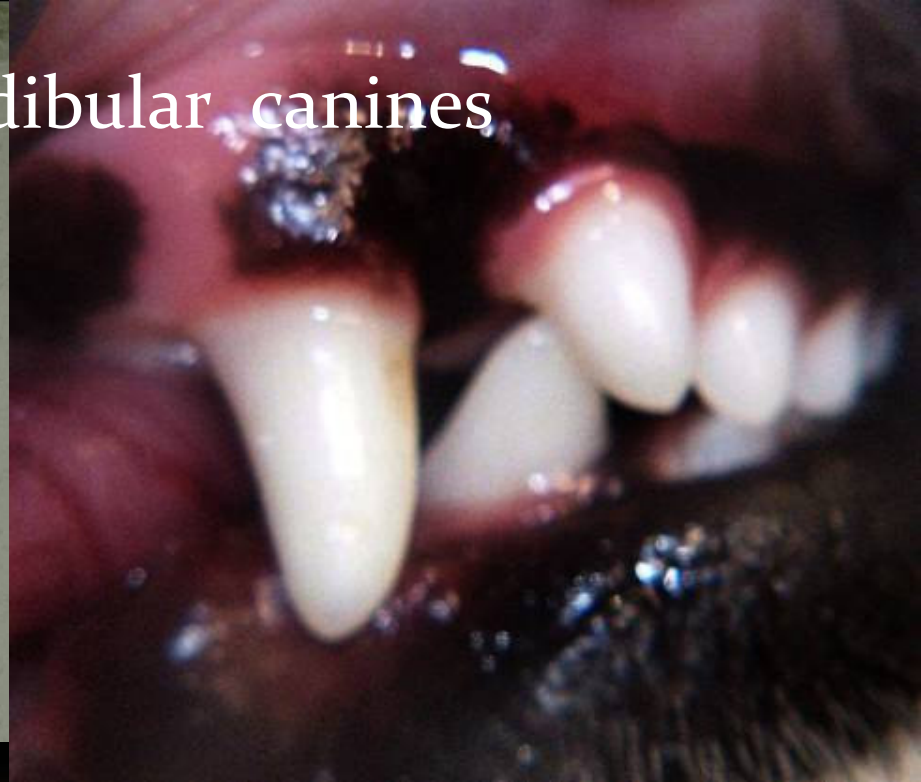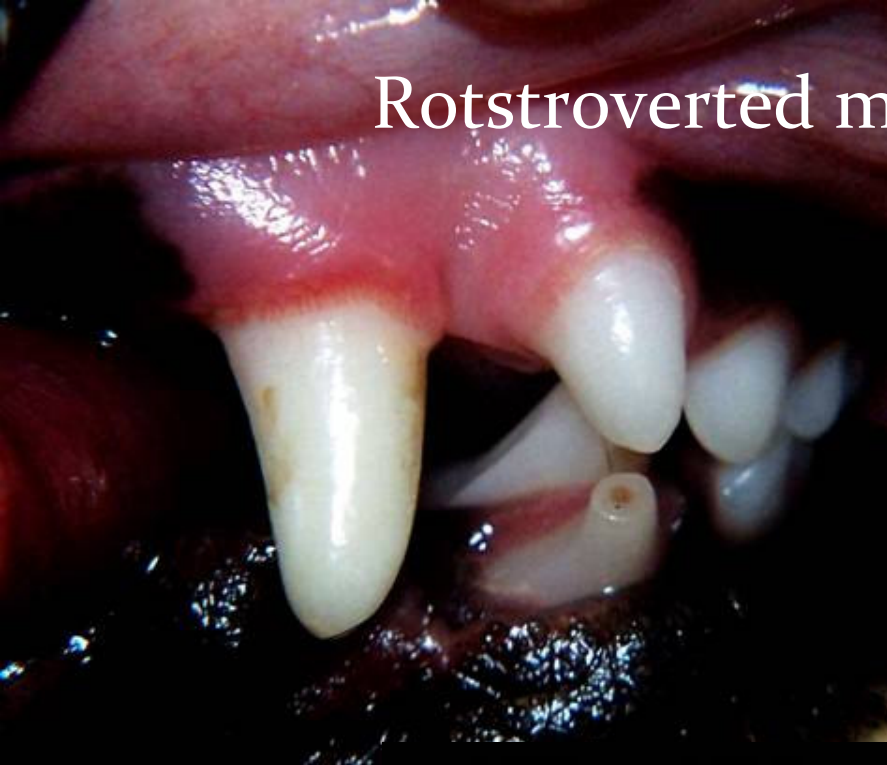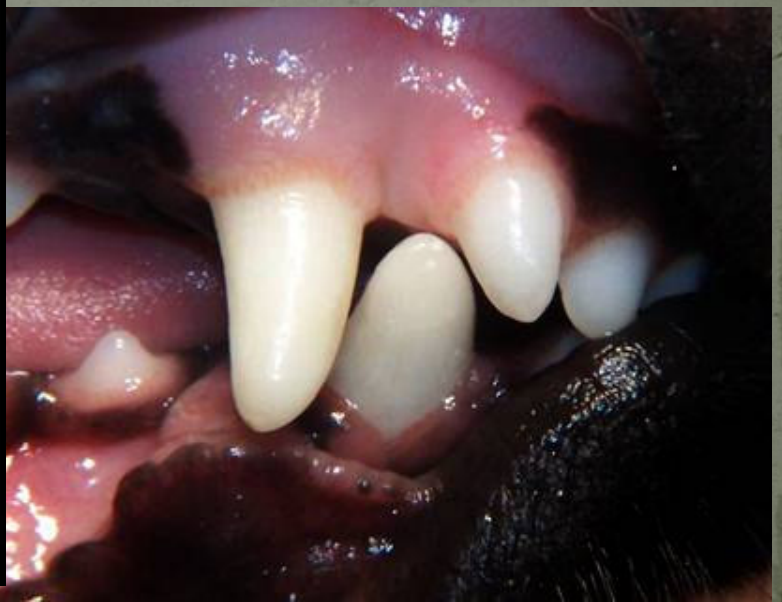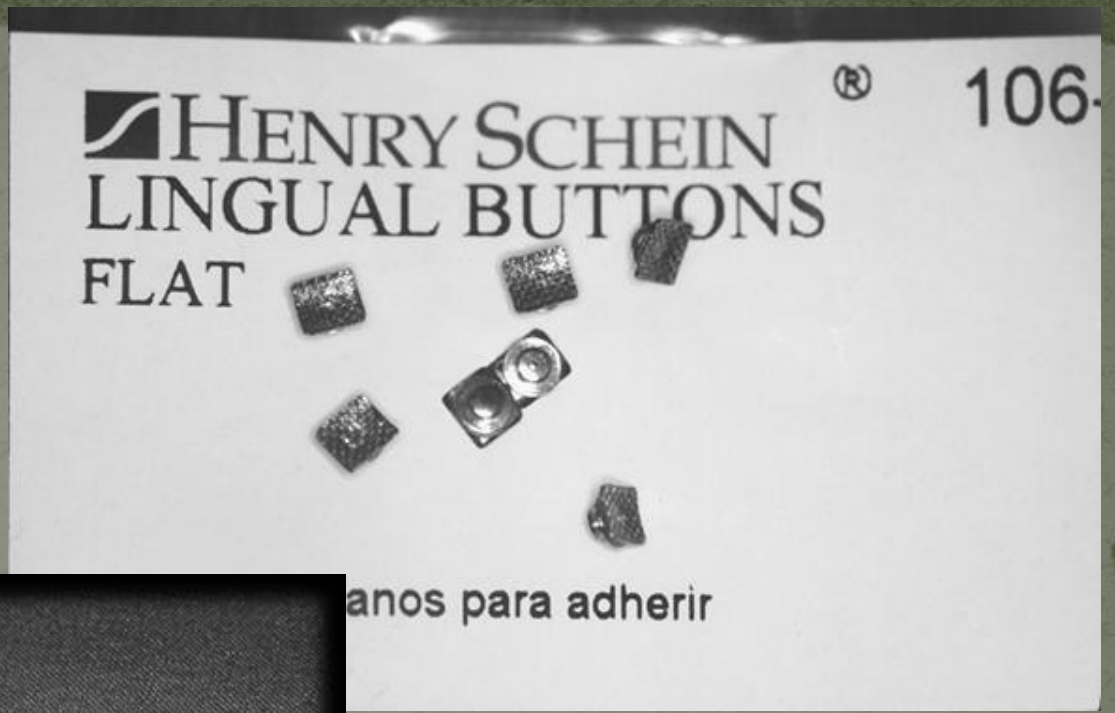


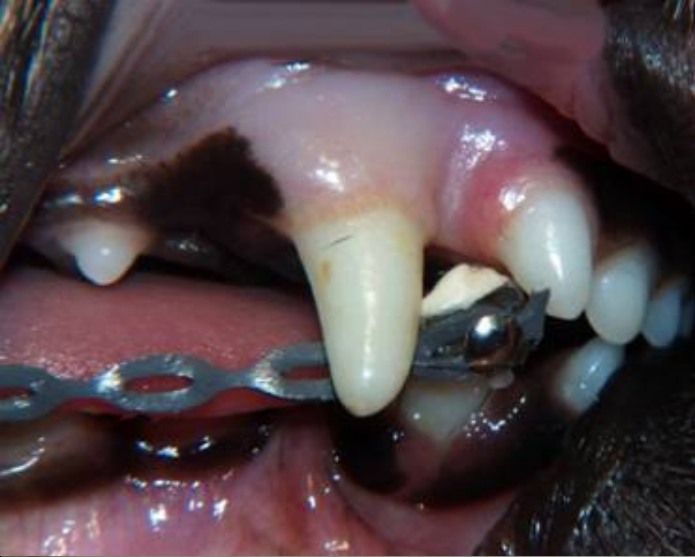Distal movement of the maxillary canine achieved in three months

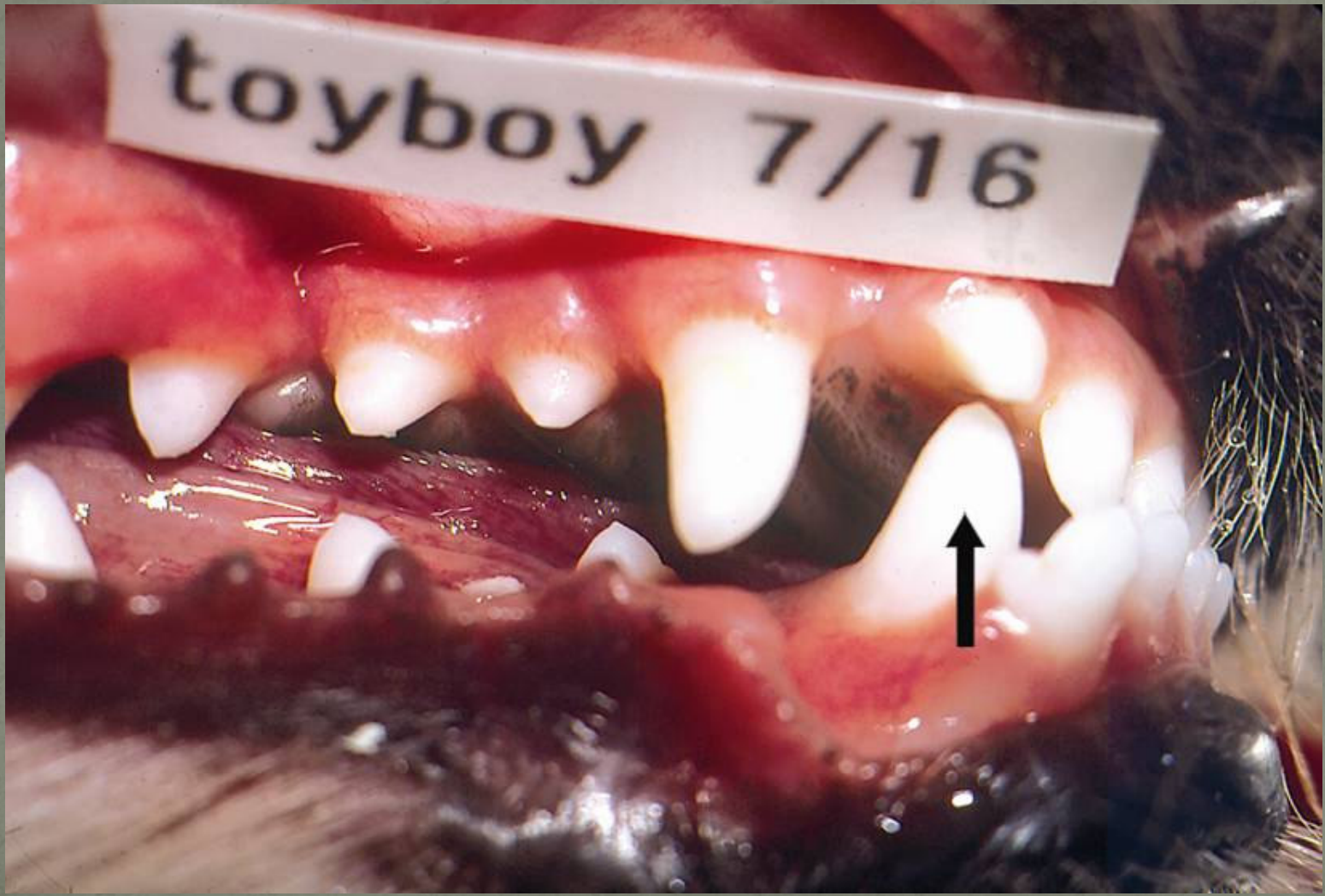


Rotstroverted mandibular canines

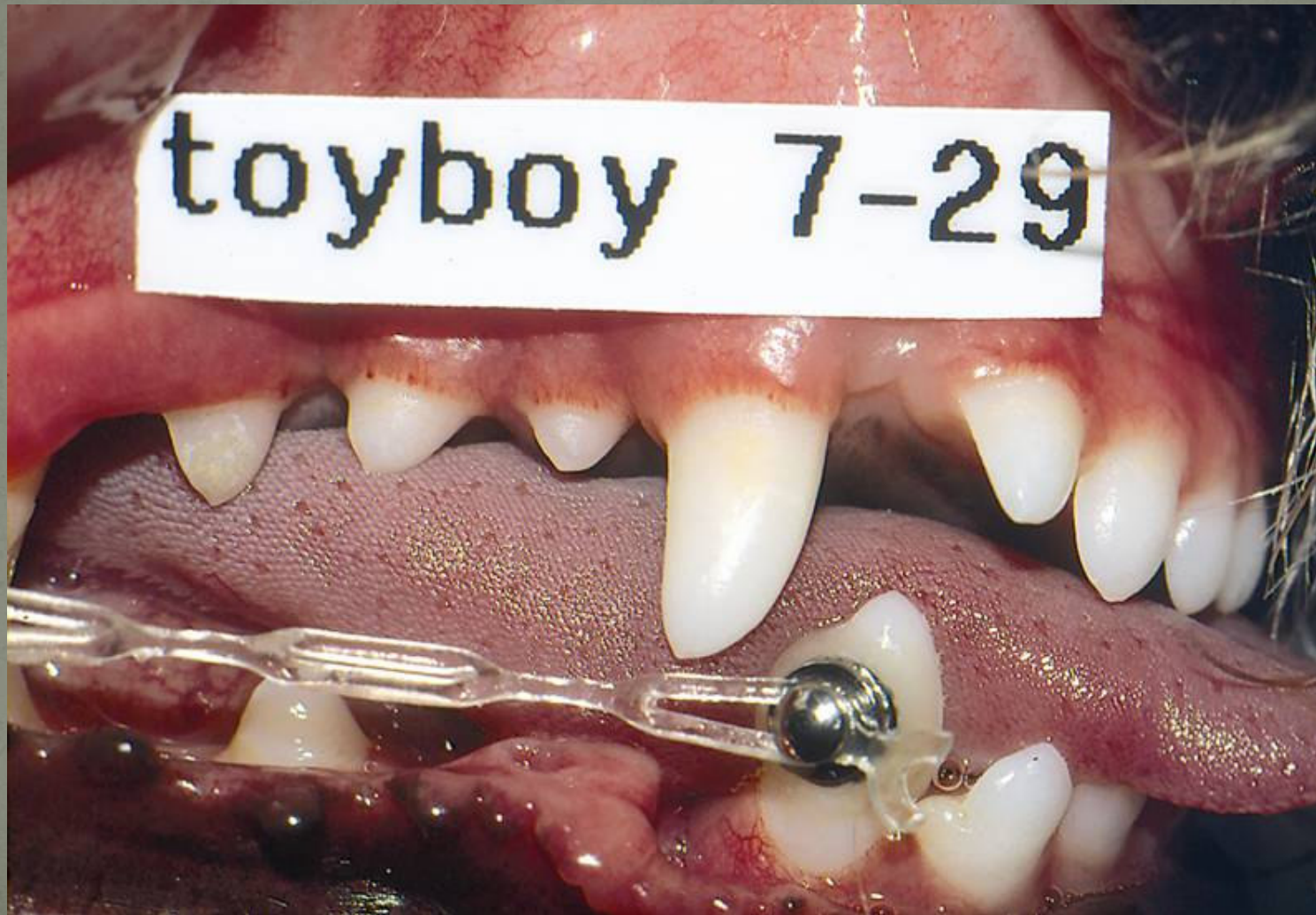




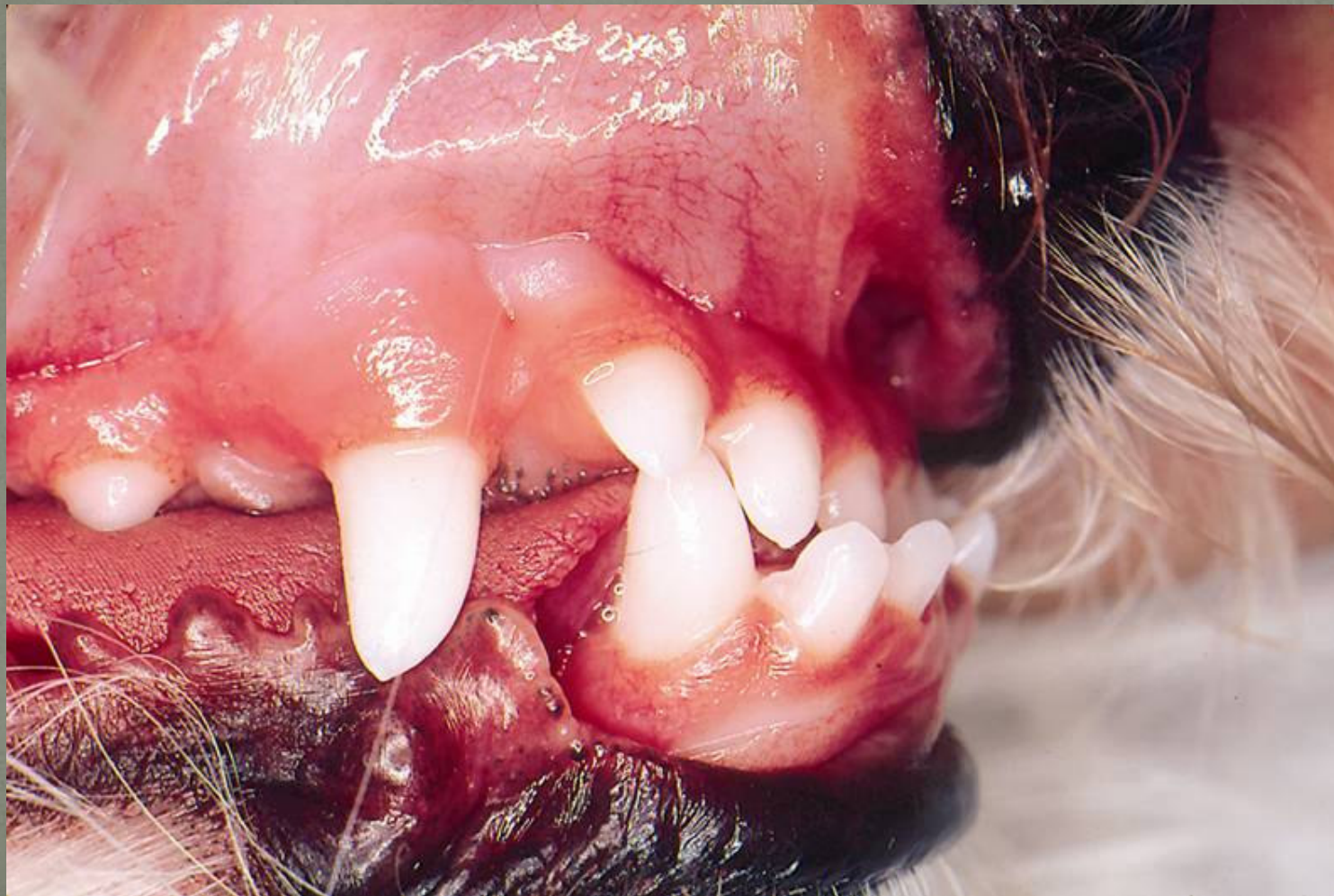toyboy 7/16



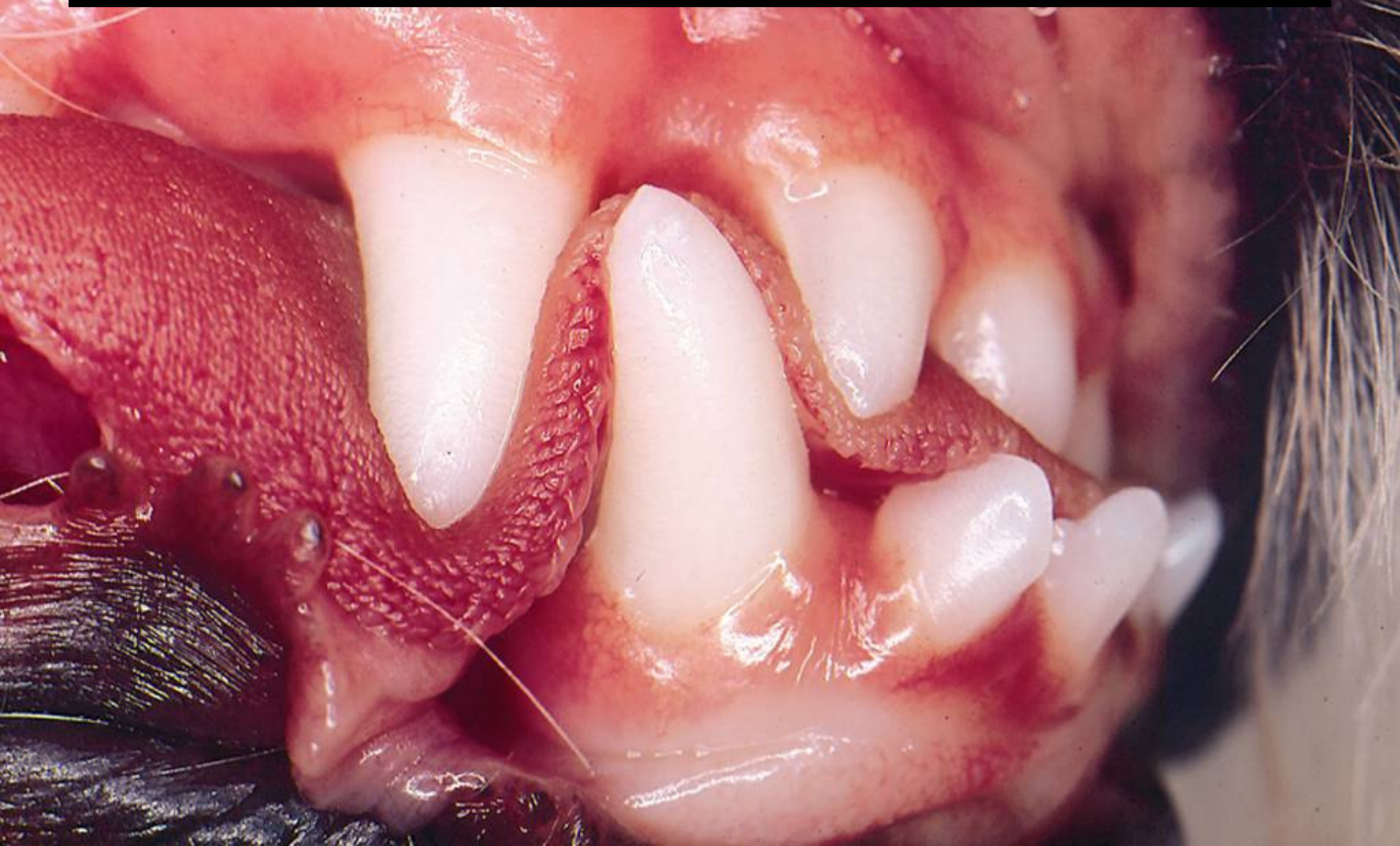Orthodontic buttons and elastics 13 days after application

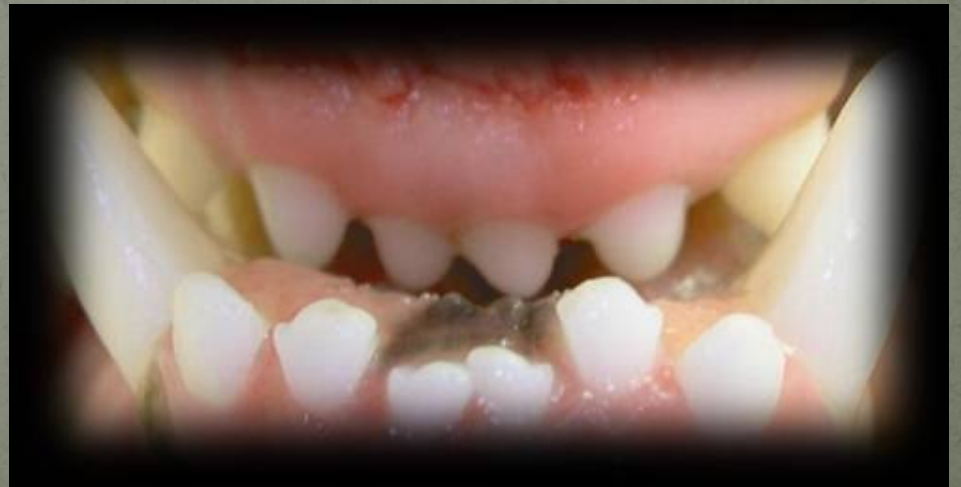
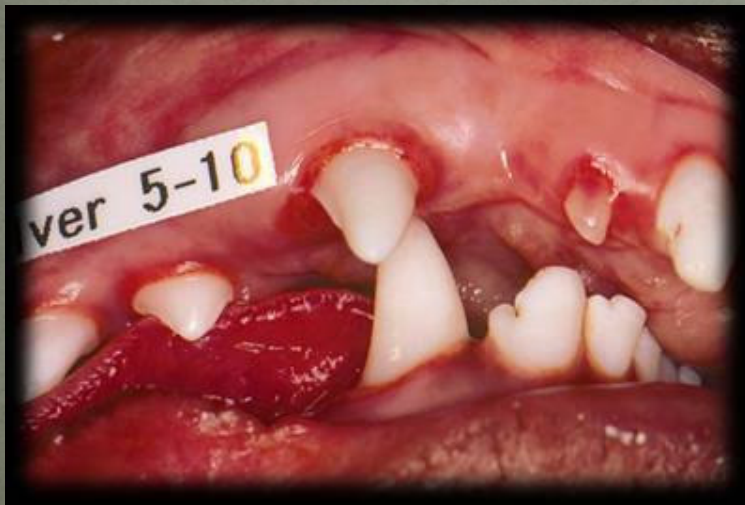
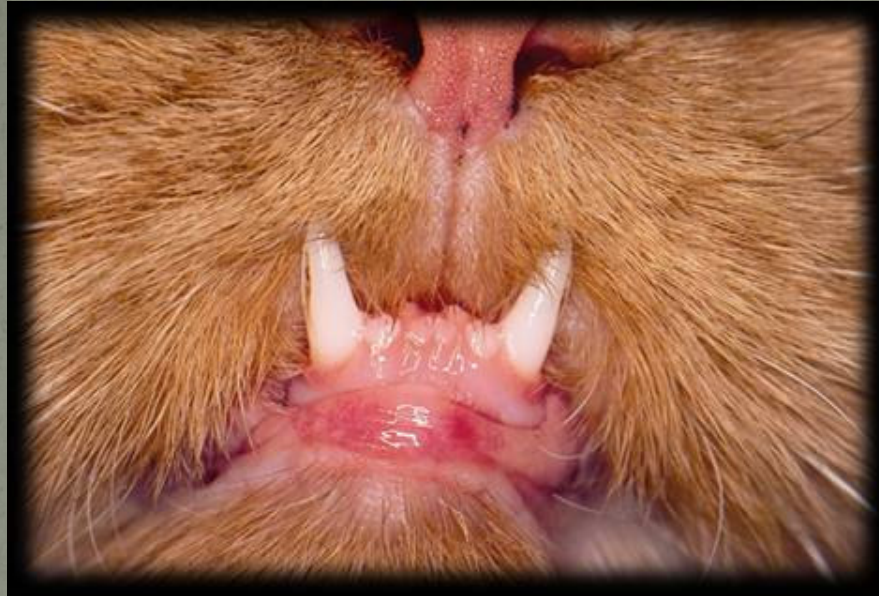Mandibular canine interfering with the maxillary corner incisor

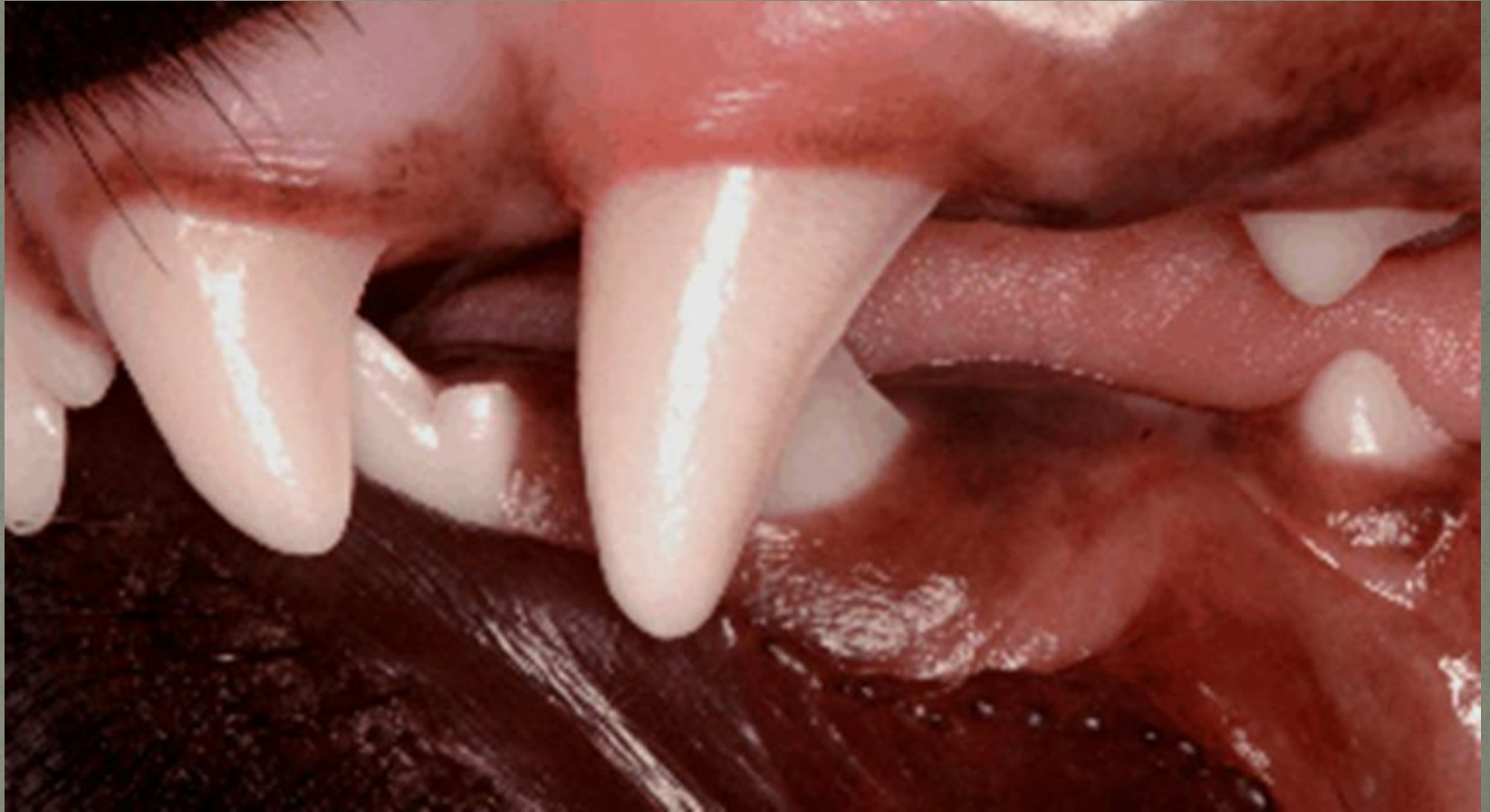

Maxillary corner incisors extracted
alleviating the interference





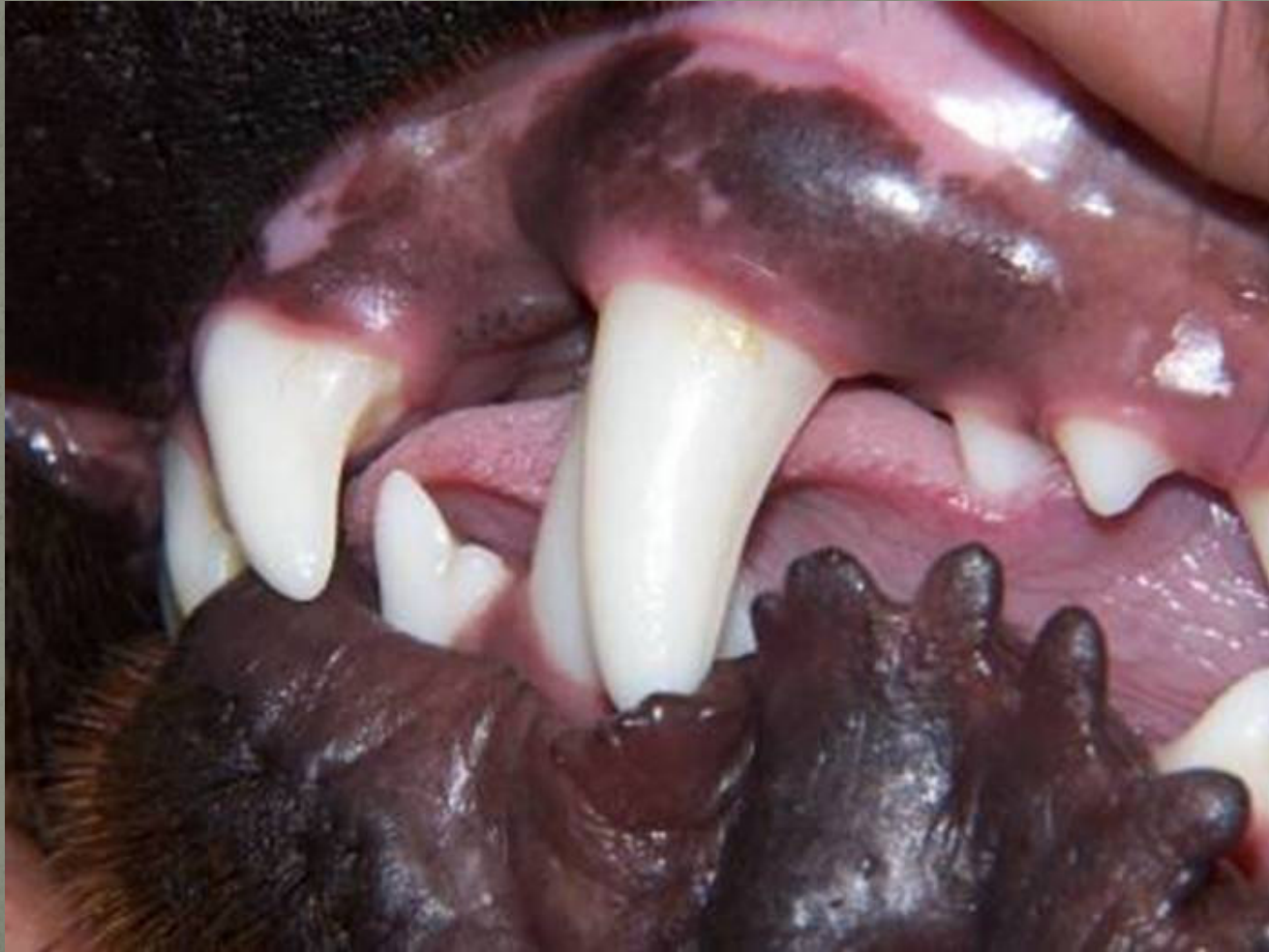Demystified?



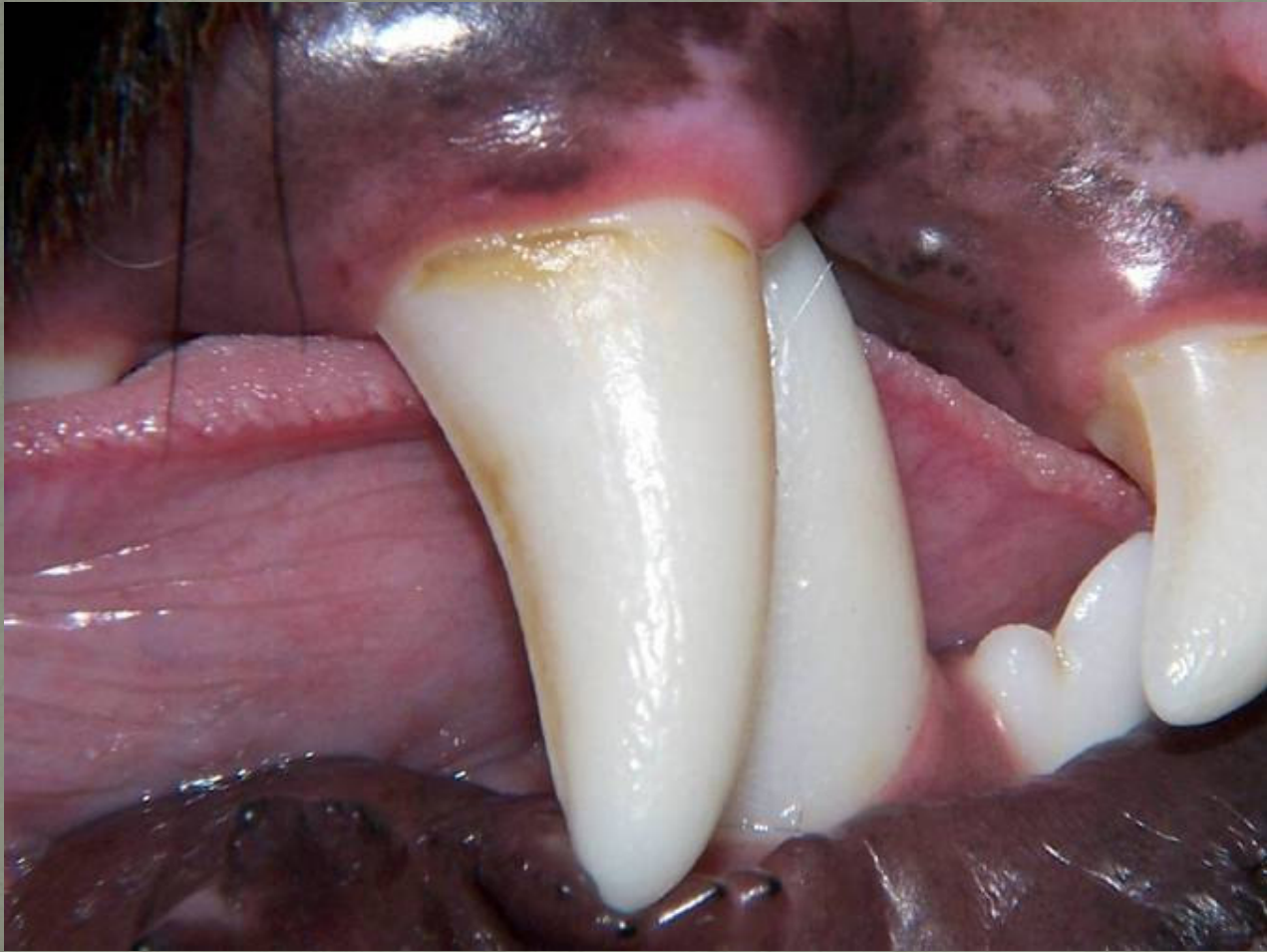11 month old Rotti



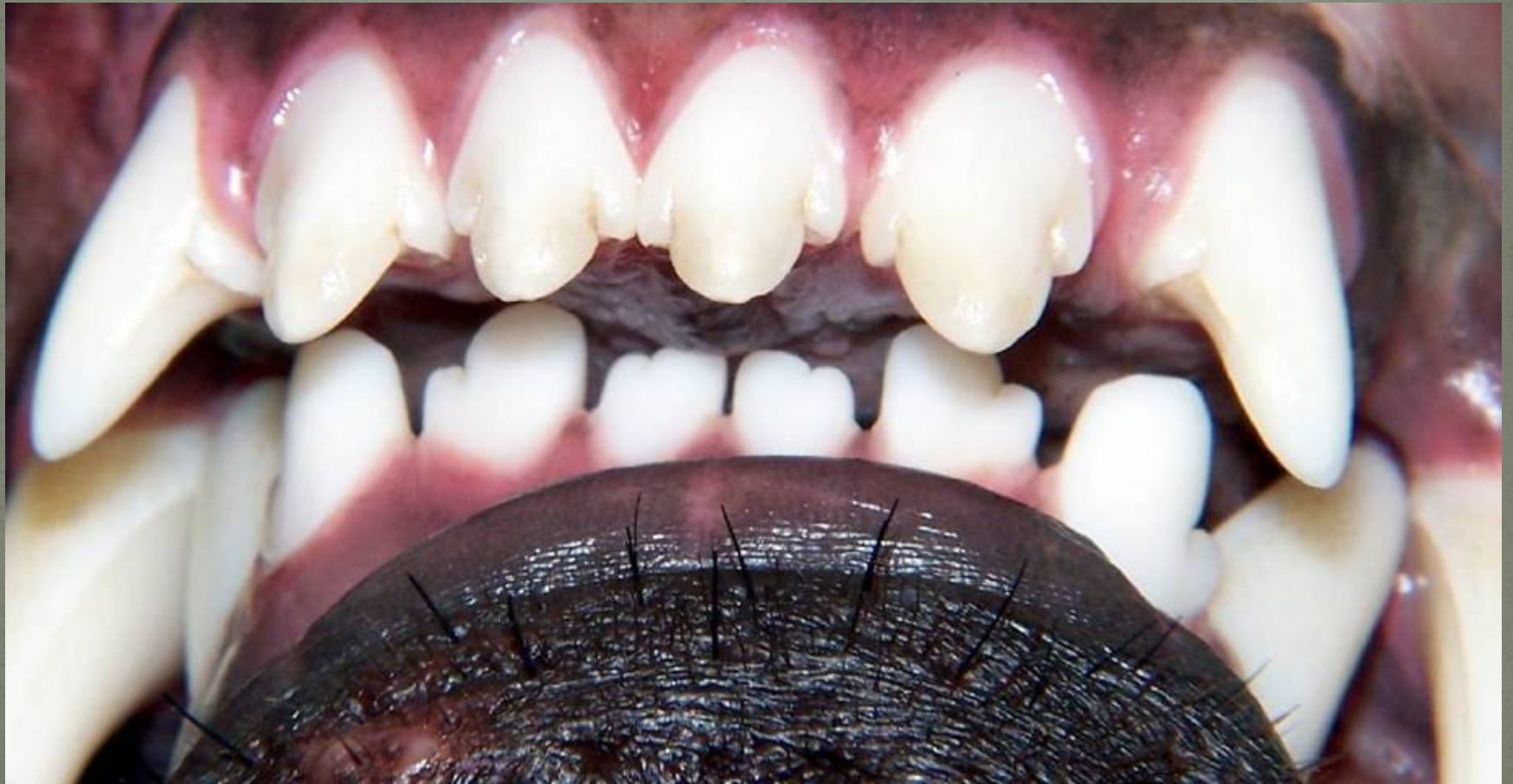mandibular canines are penetrating the palate



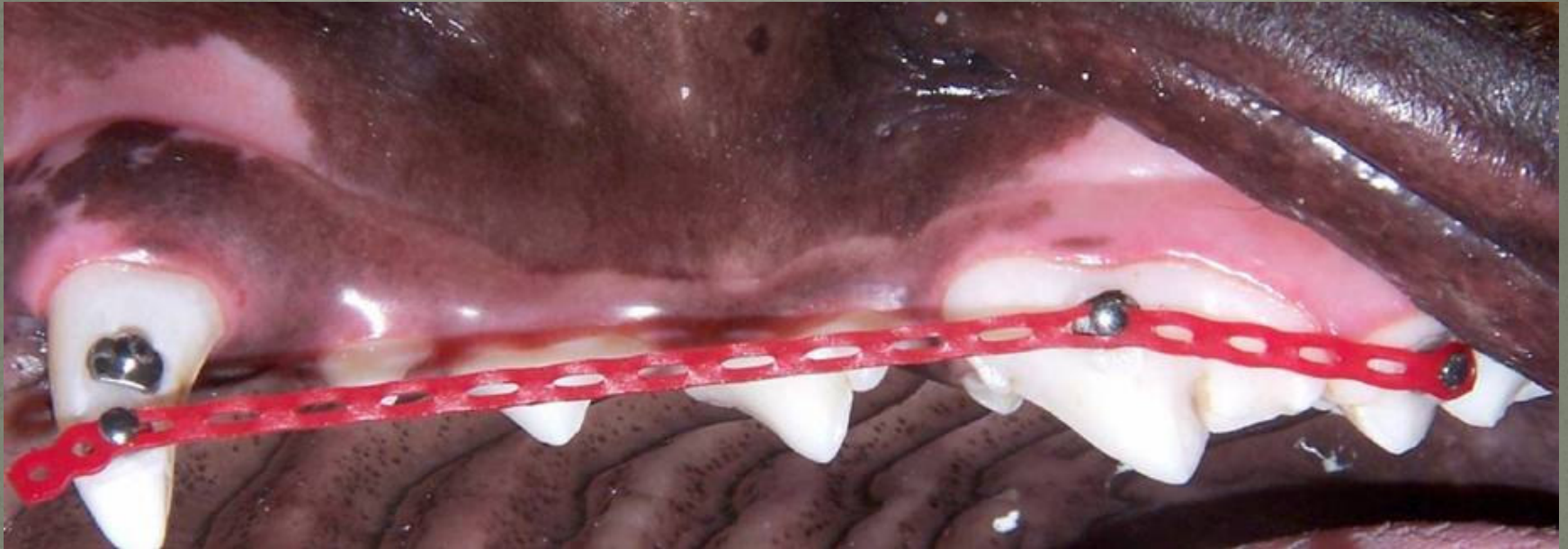right



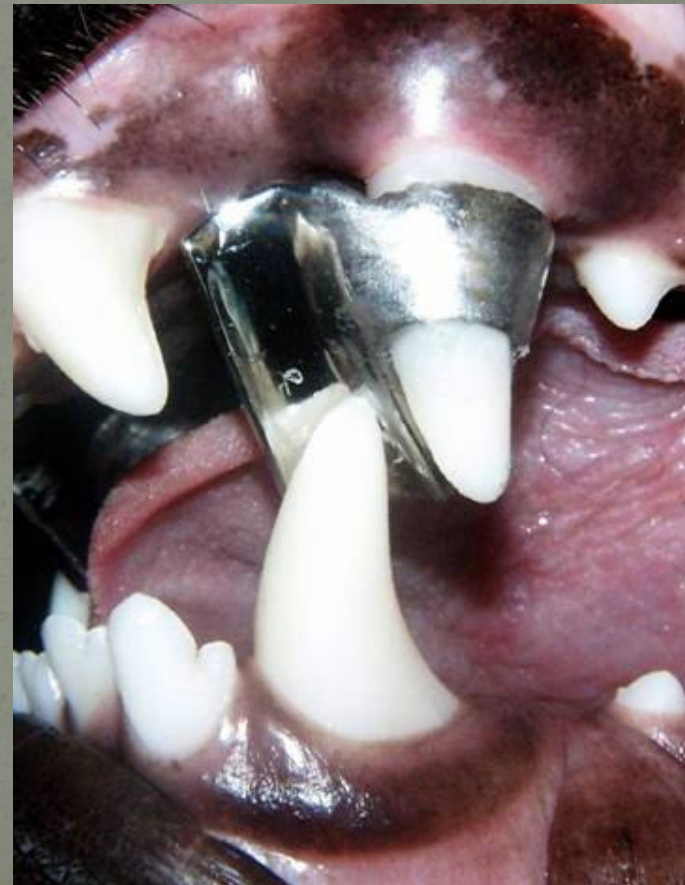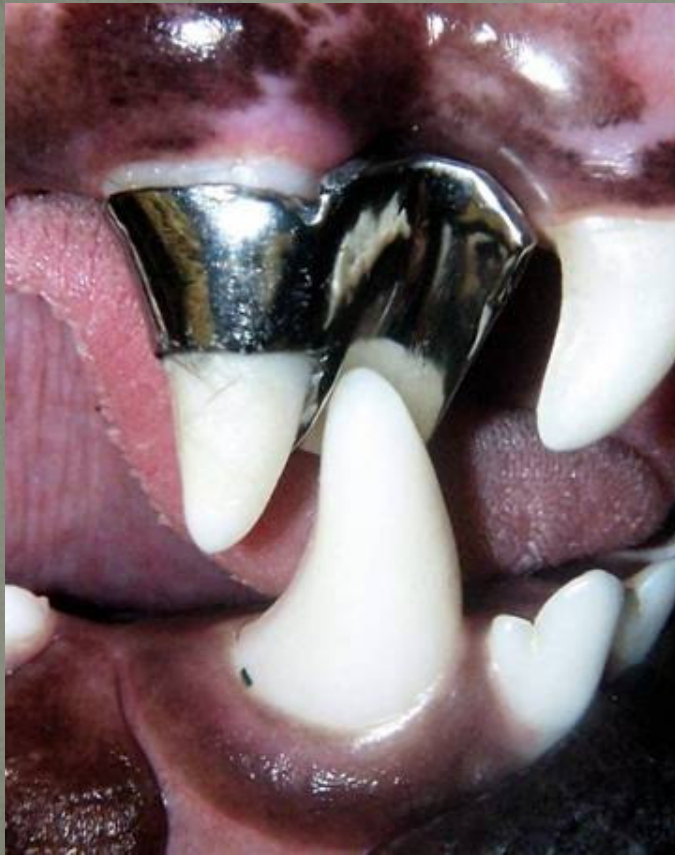front view



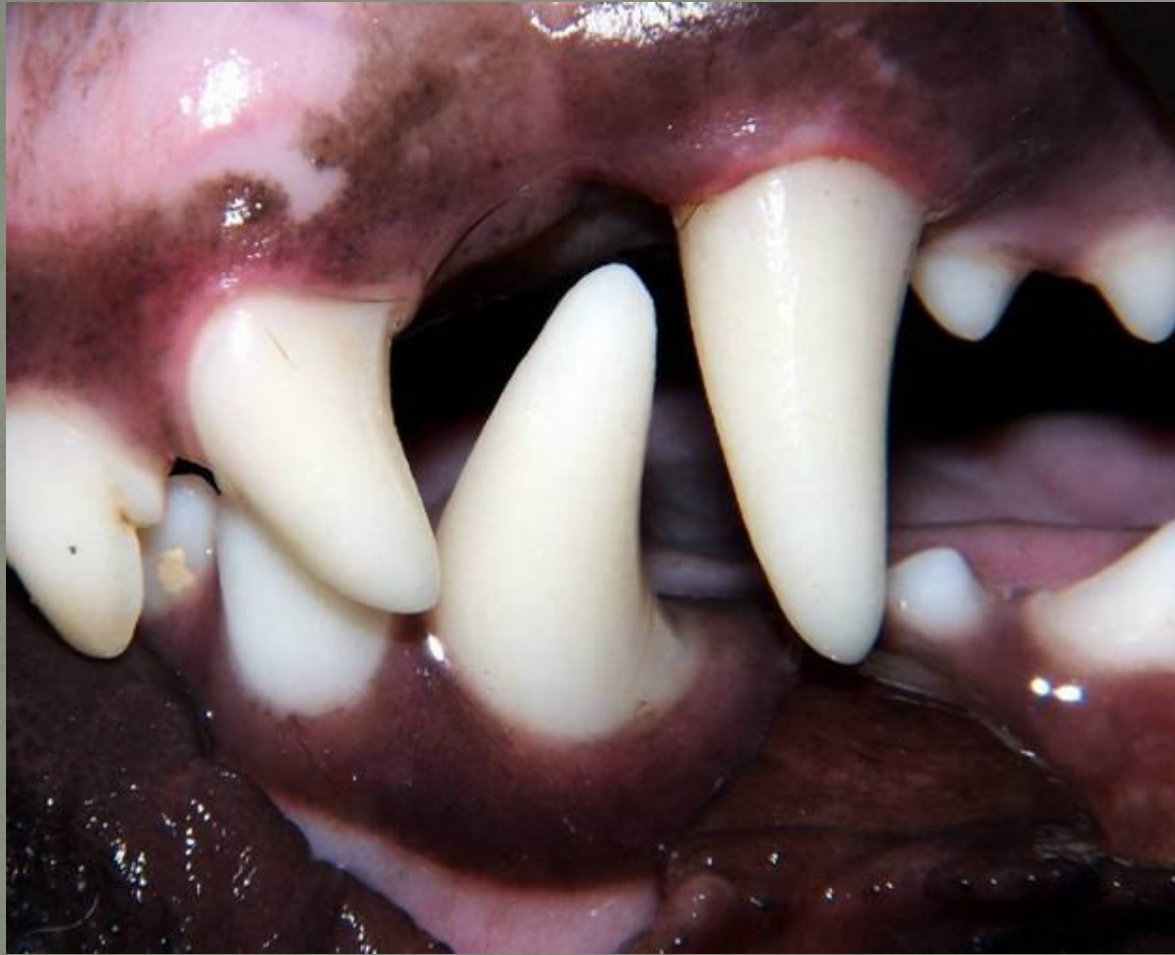Left side button and elastics



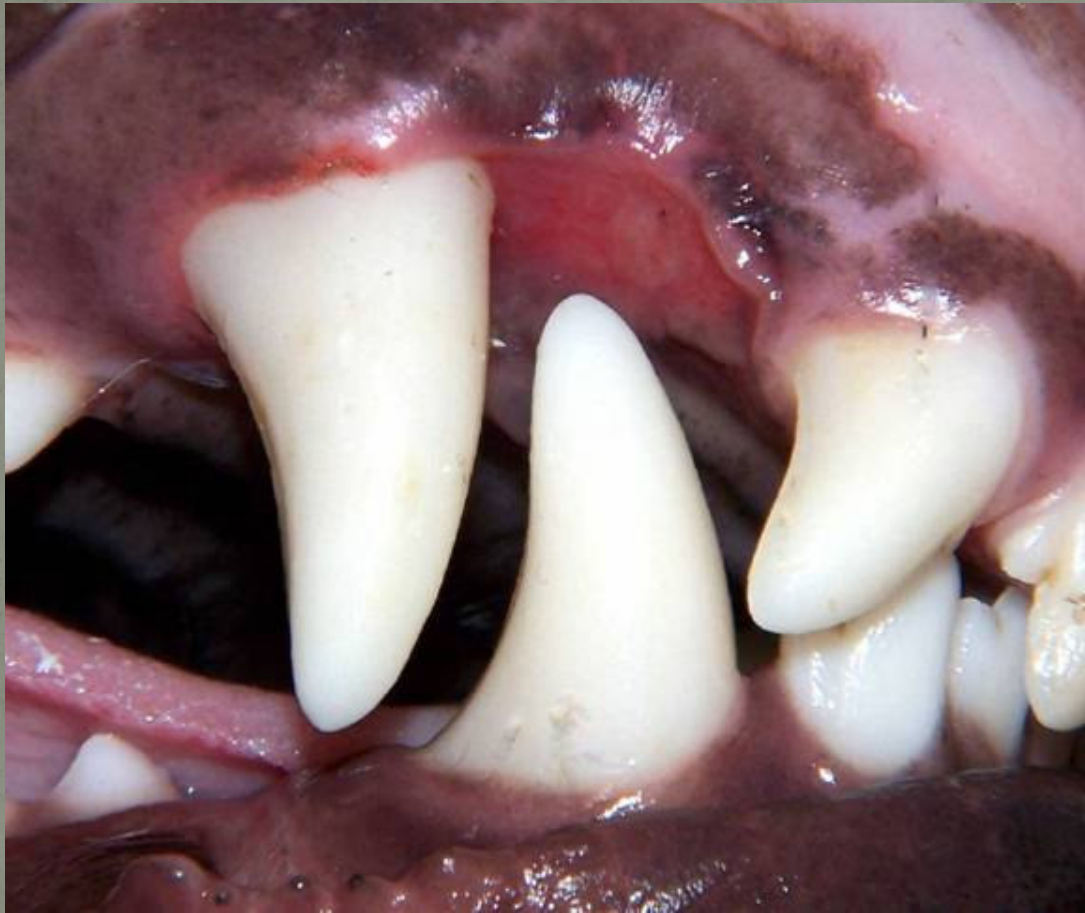After the elastics moved the maxillary canines caudally, we cemented a telescoping inclined plane on the maxillary canines to move the mandibular canines laterally



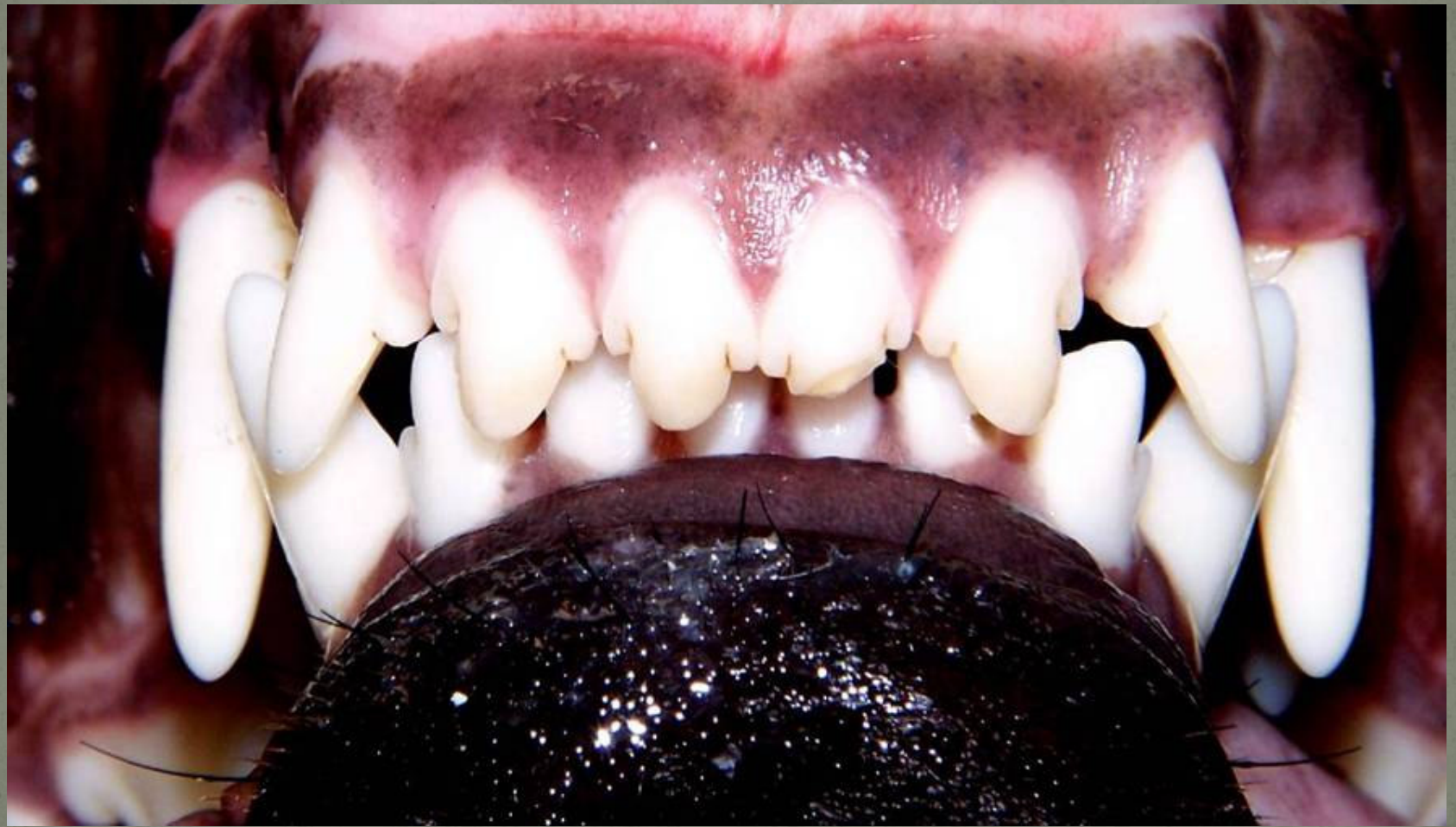finished

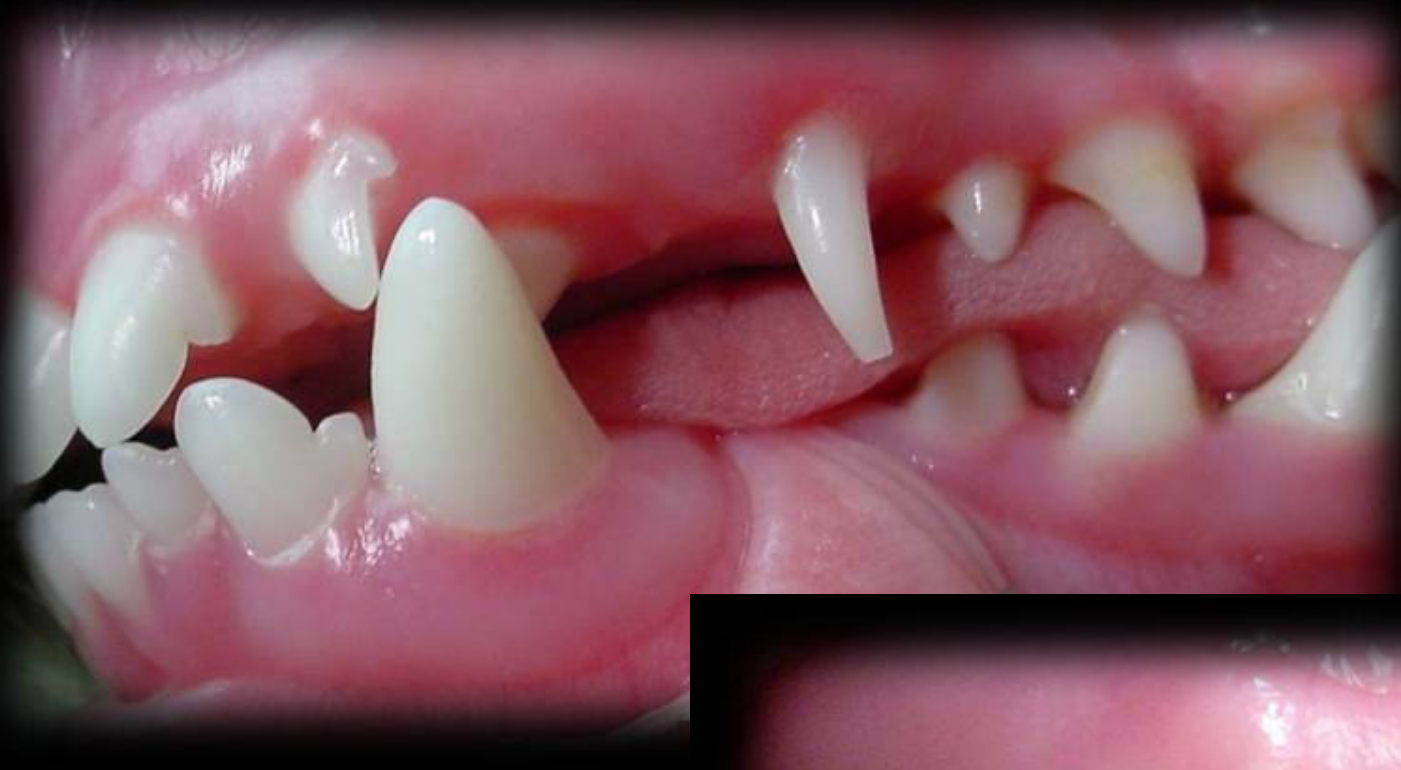



Right side

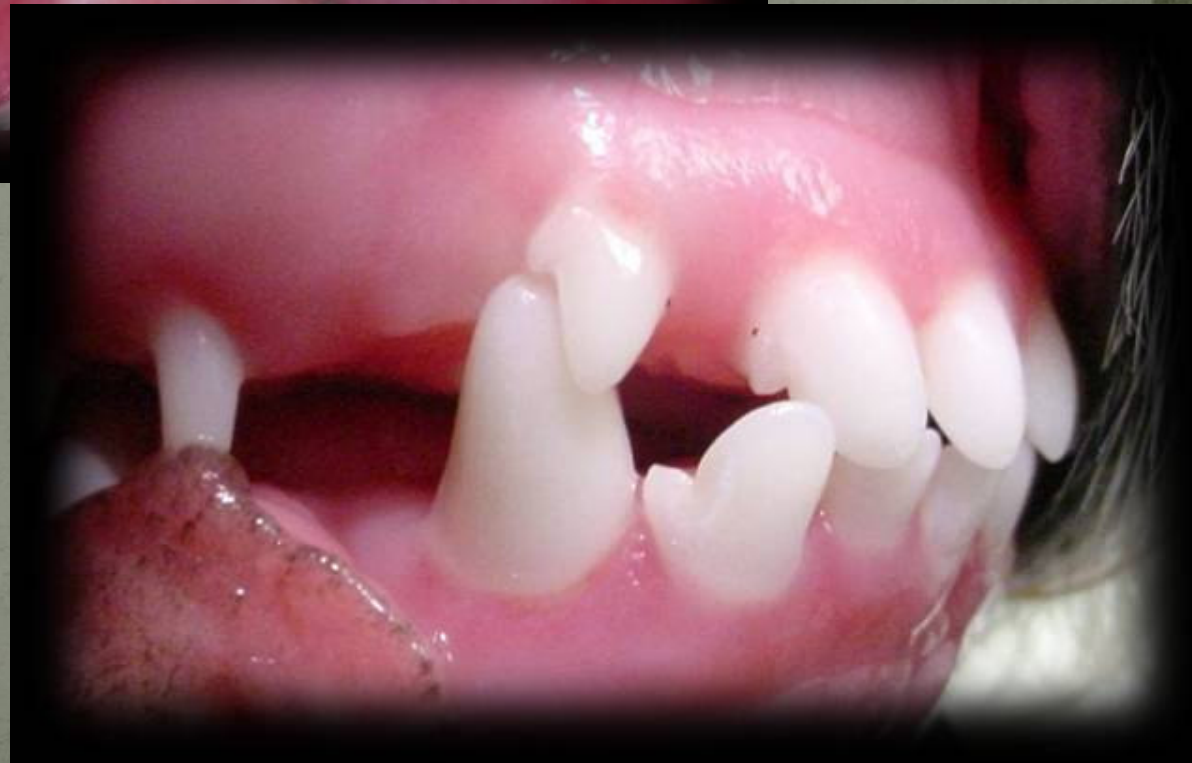

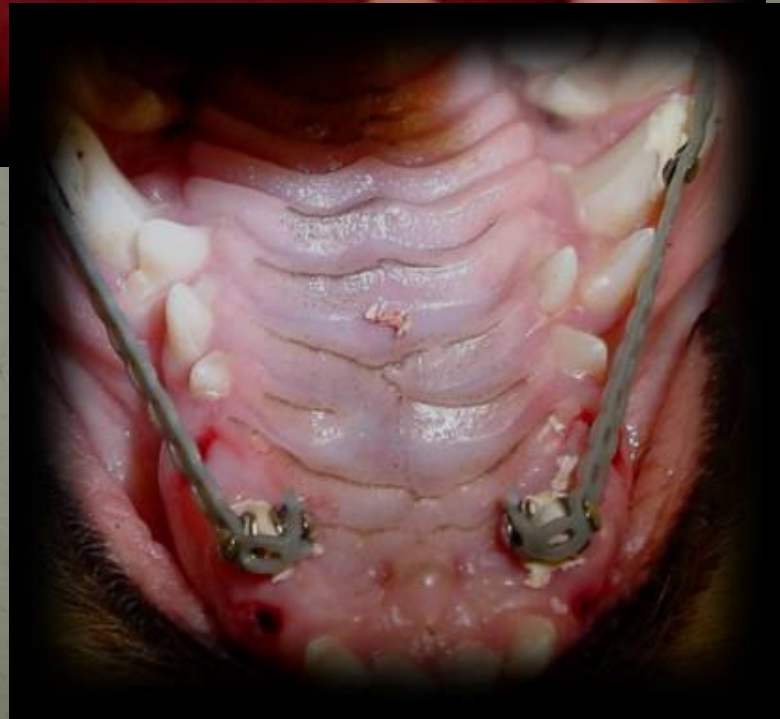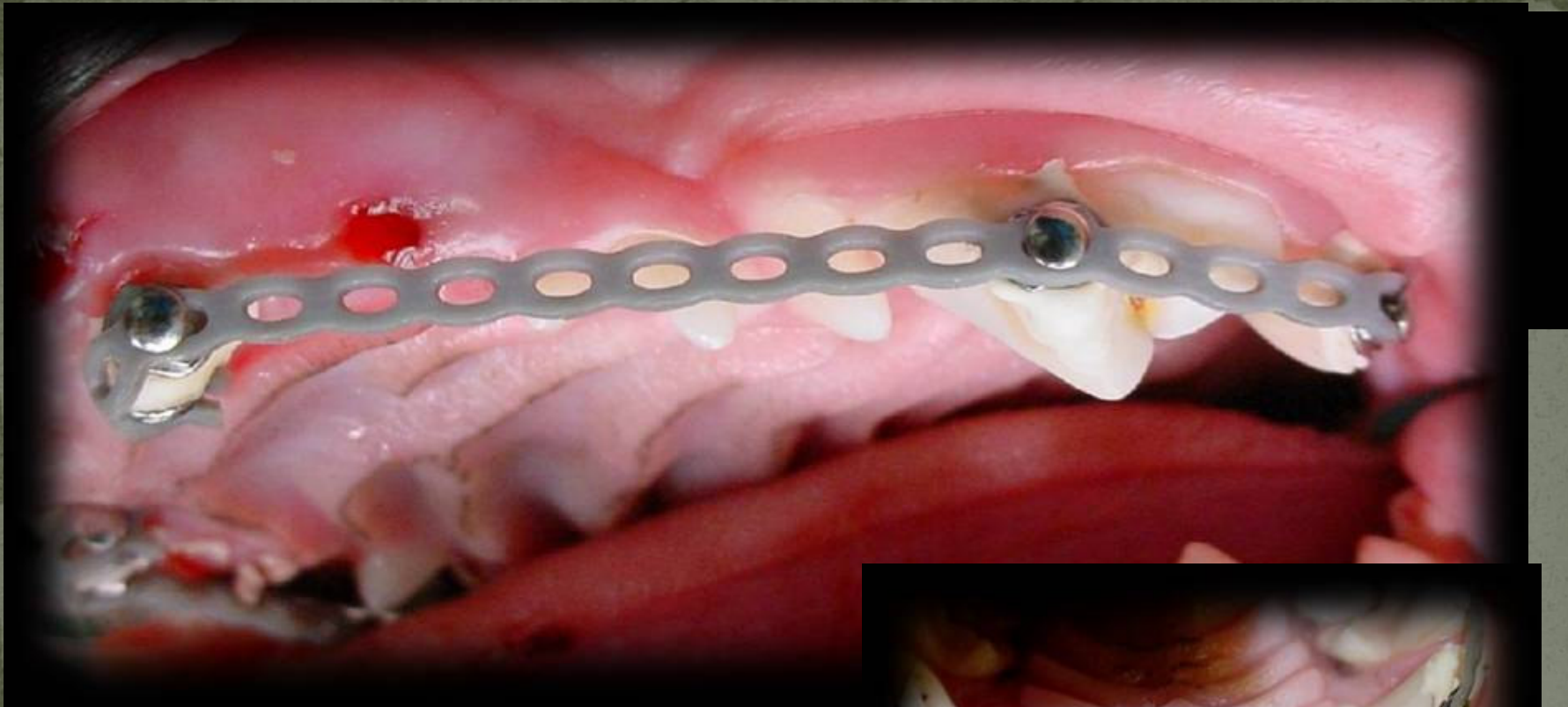Completed case



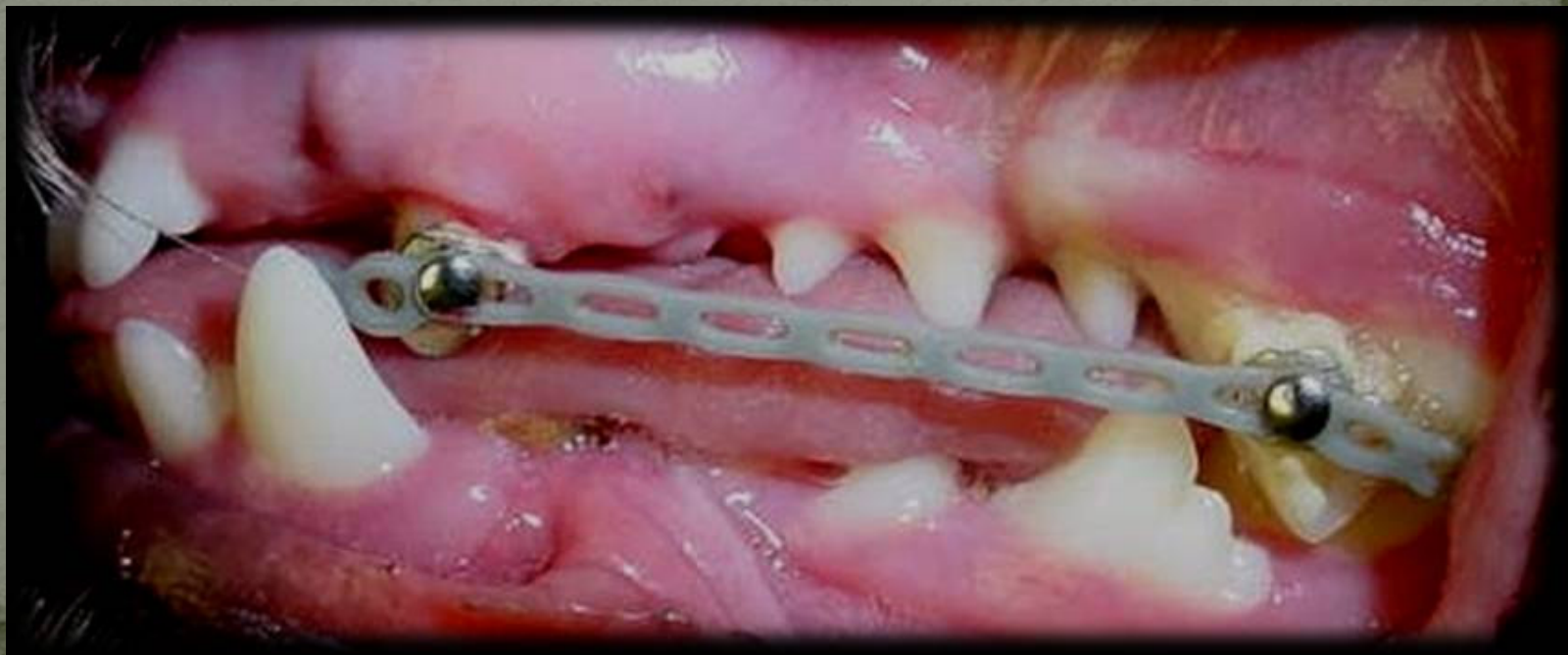

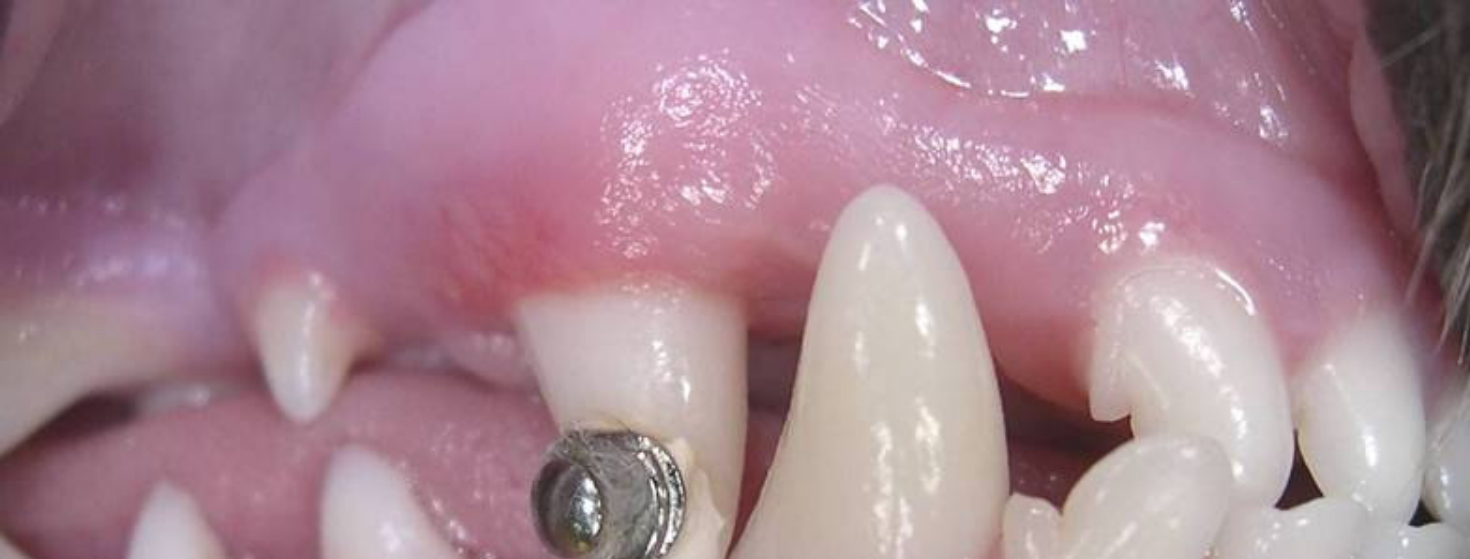Diagnosis?
Therapy options?



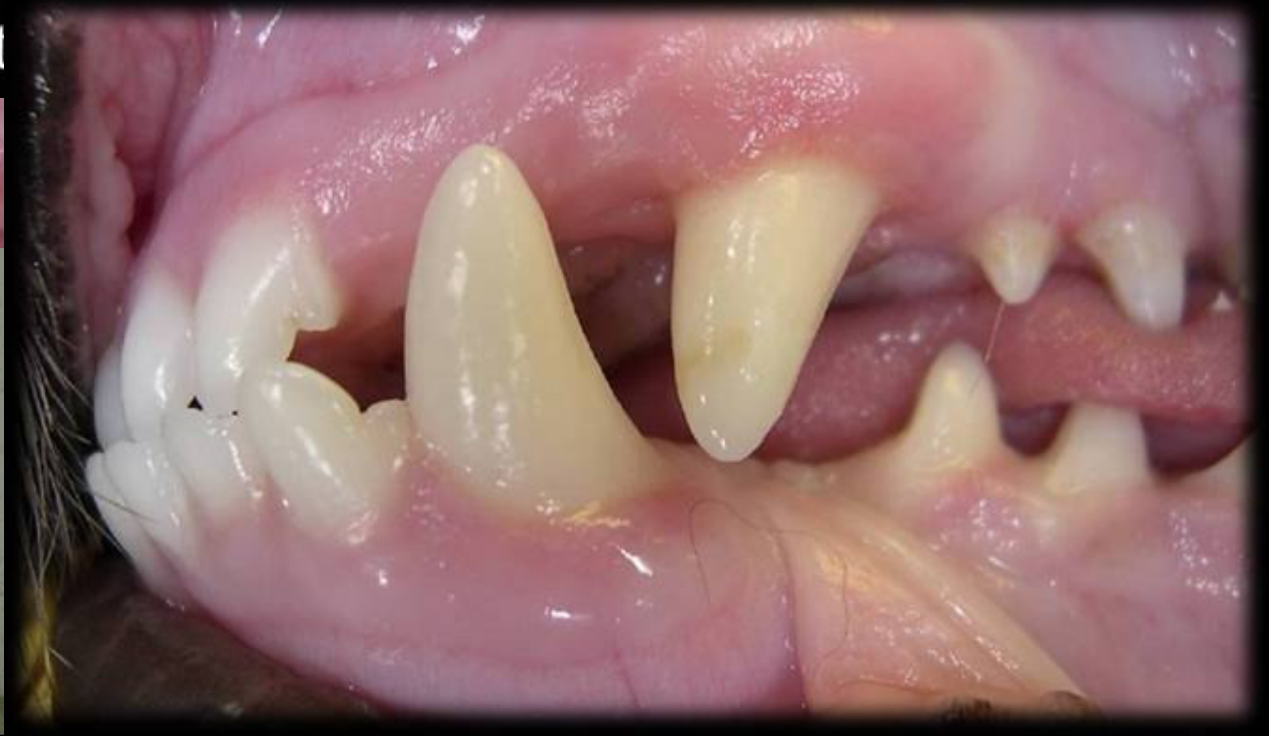




Two weeks after application of buttons and
elastics- canines moving caudally





Good resolution at



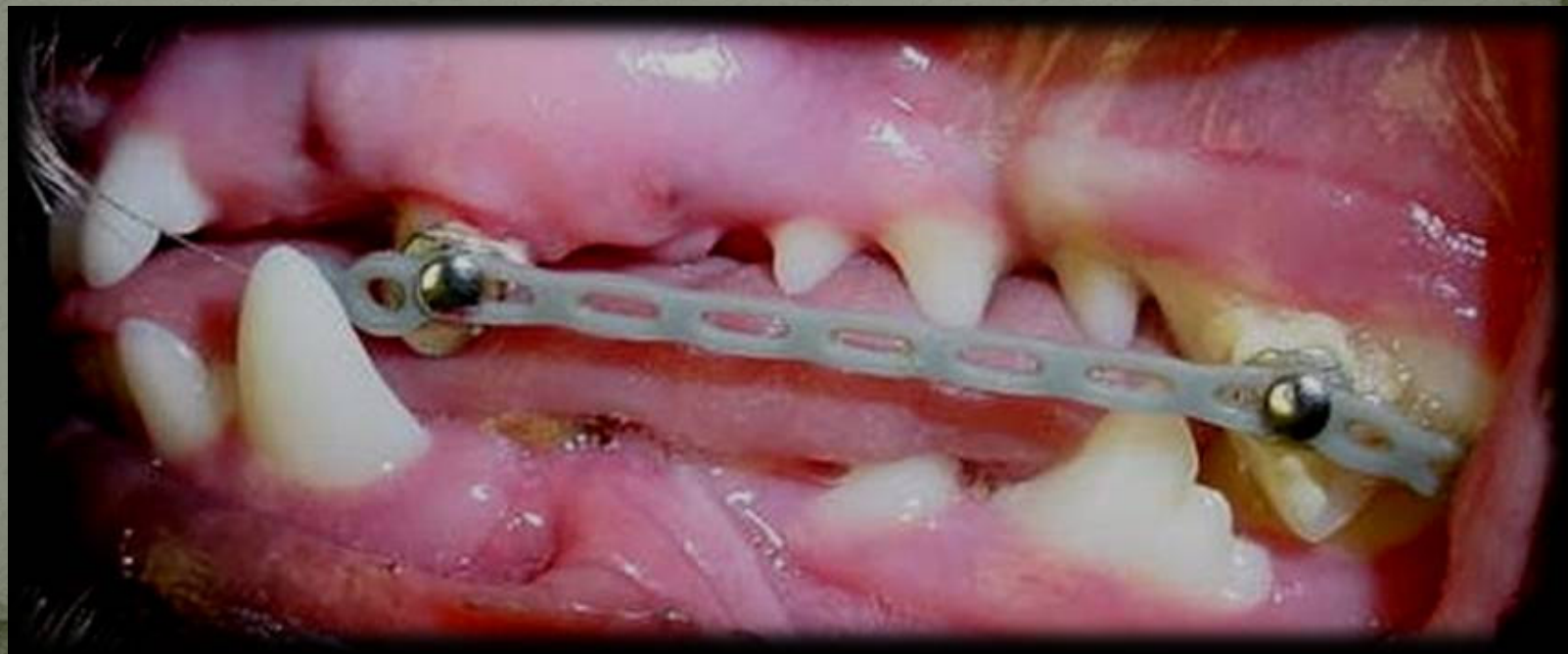
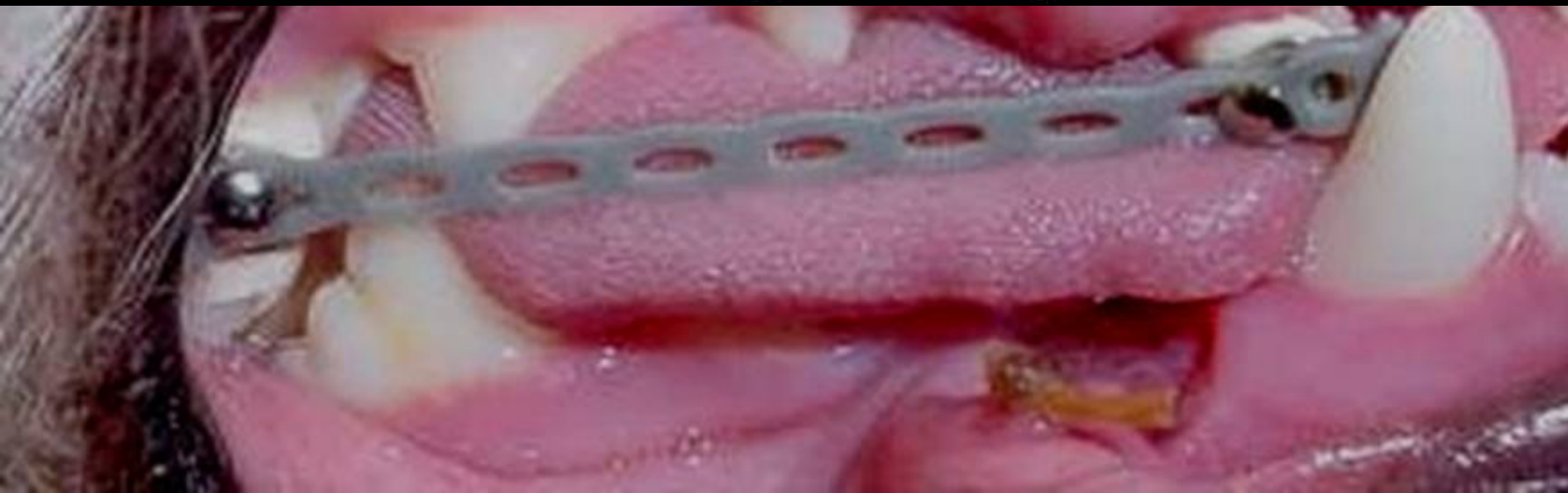
Diagnosis?
Therapy options?







Two weeks after application of buttons and
elastics- canines moving caudally








Good resolution at

















Malpositioned premolars

