

Wading through the quagmire of thoracic radiographs

PART 2

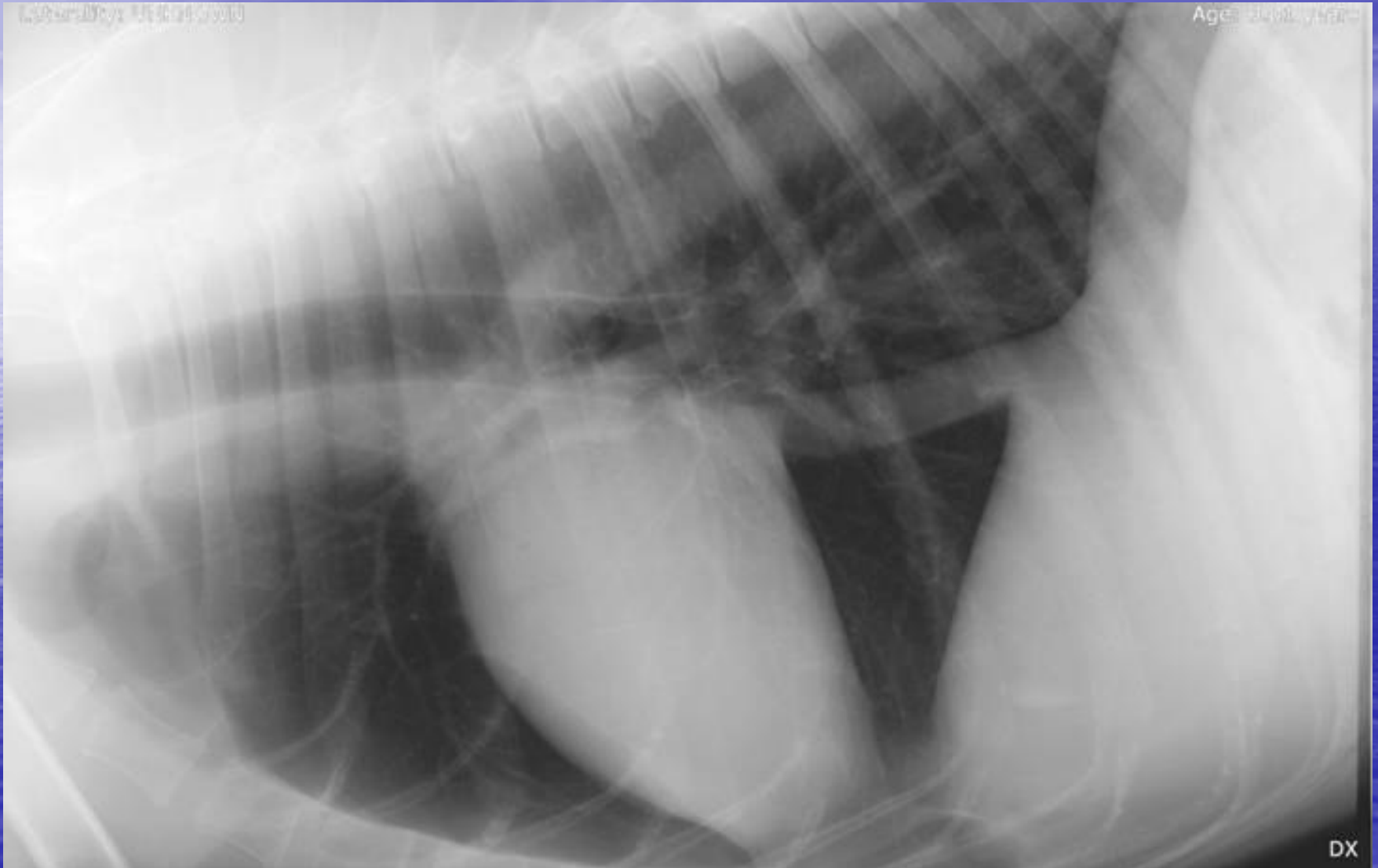
Leila T. Worth
VMD, PhD
DACVR



Questions before the test?



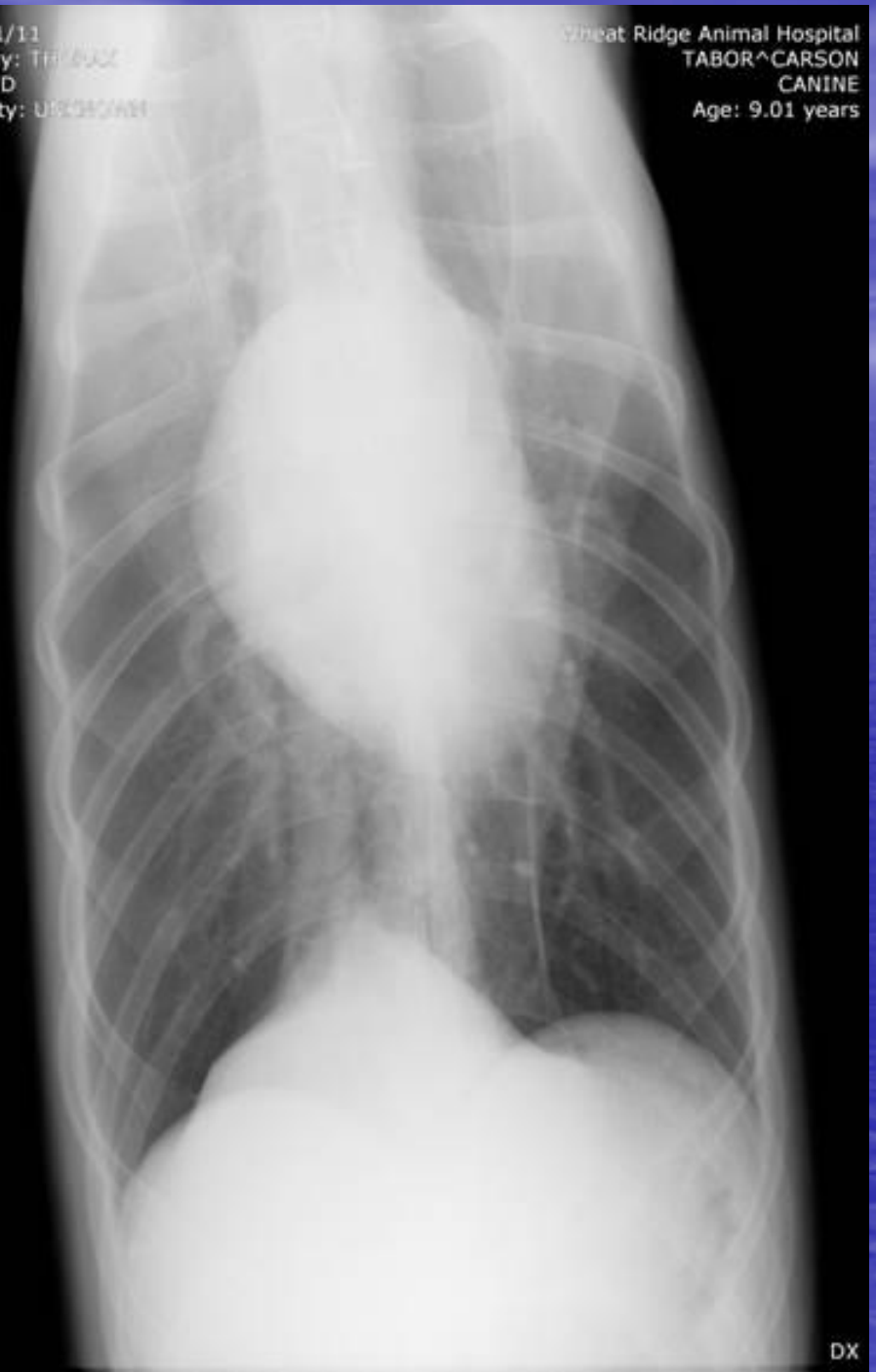Right or left lateral?



Img: 11/11
Anatomy: THORAX
View: VD
Laterality: UNKNOWN

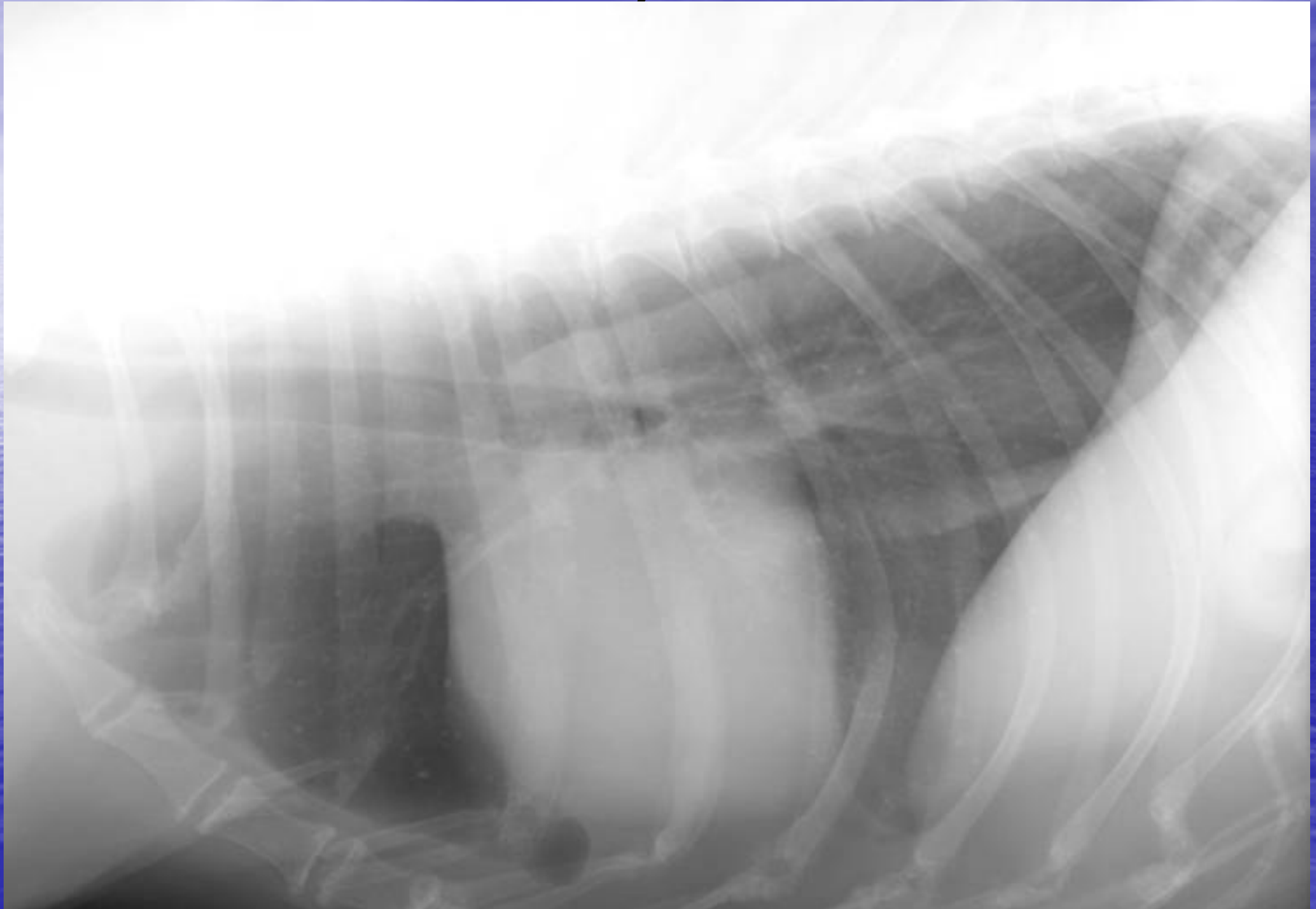
Wheat Ridge Animal Hospital
TABOR^CARSON
CANINE
Age: 9.01 years

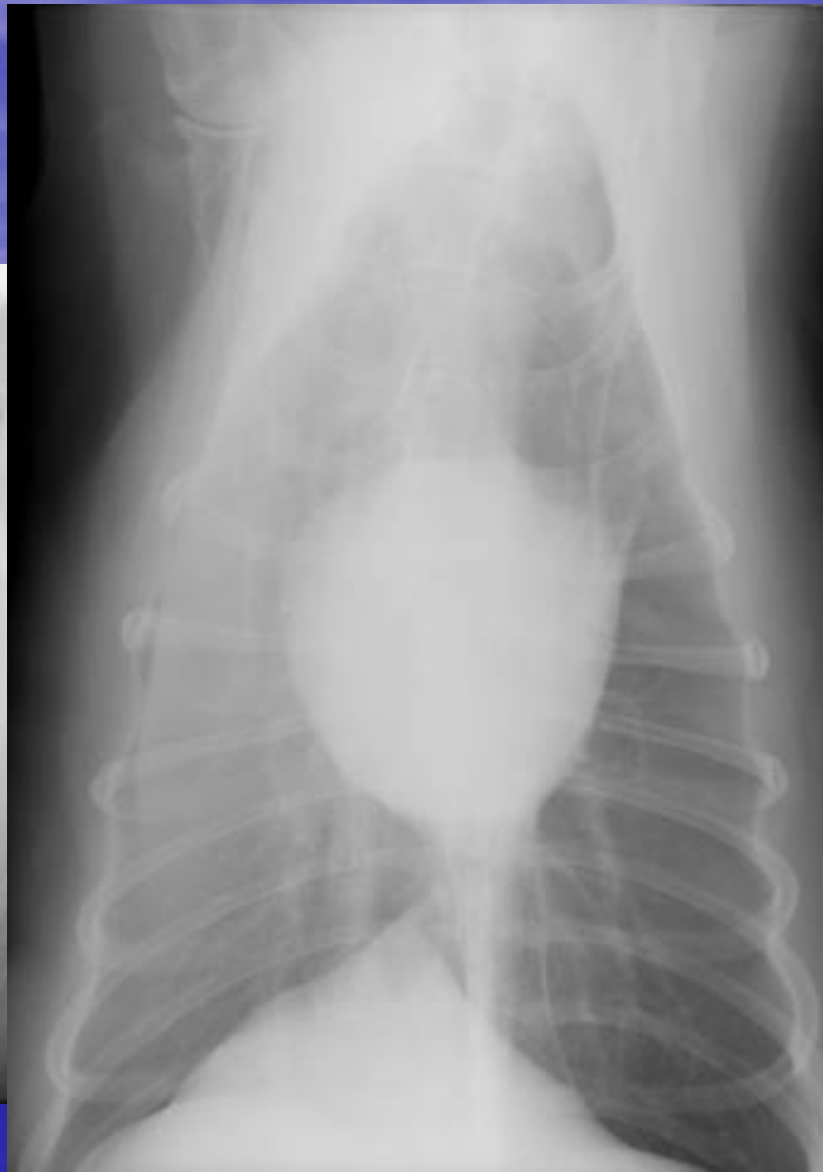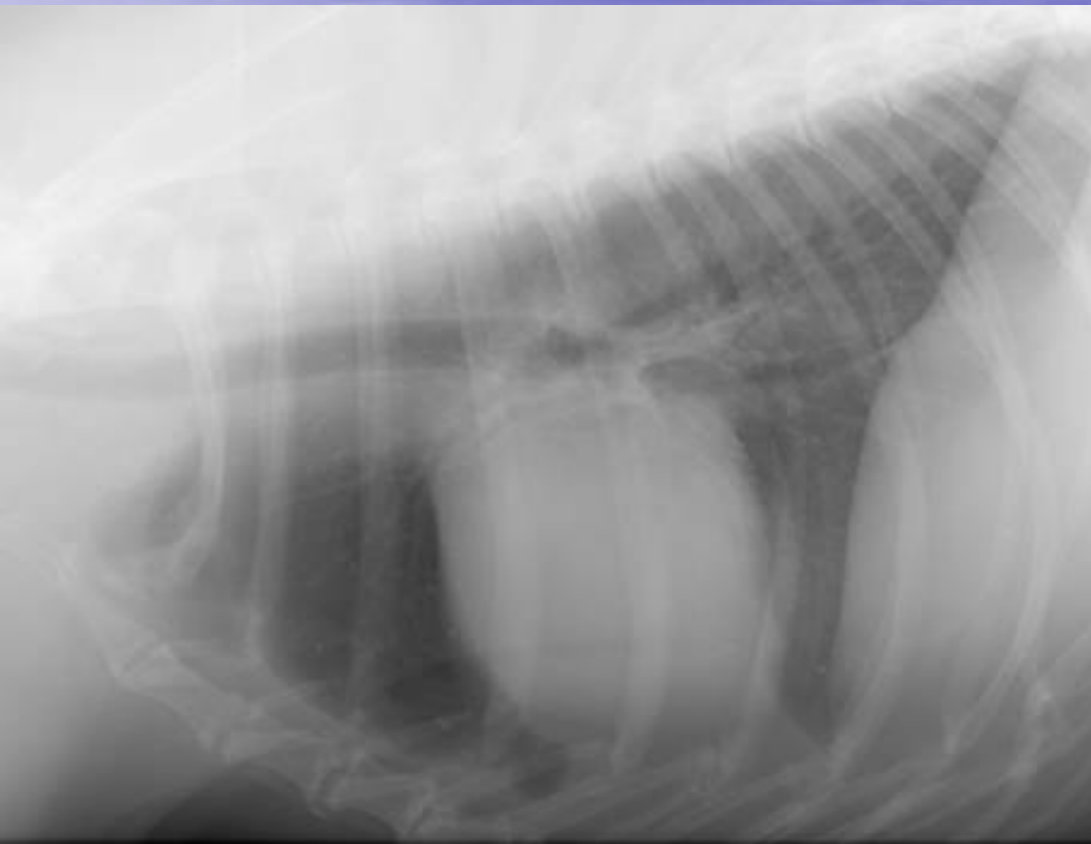
Up correctly?



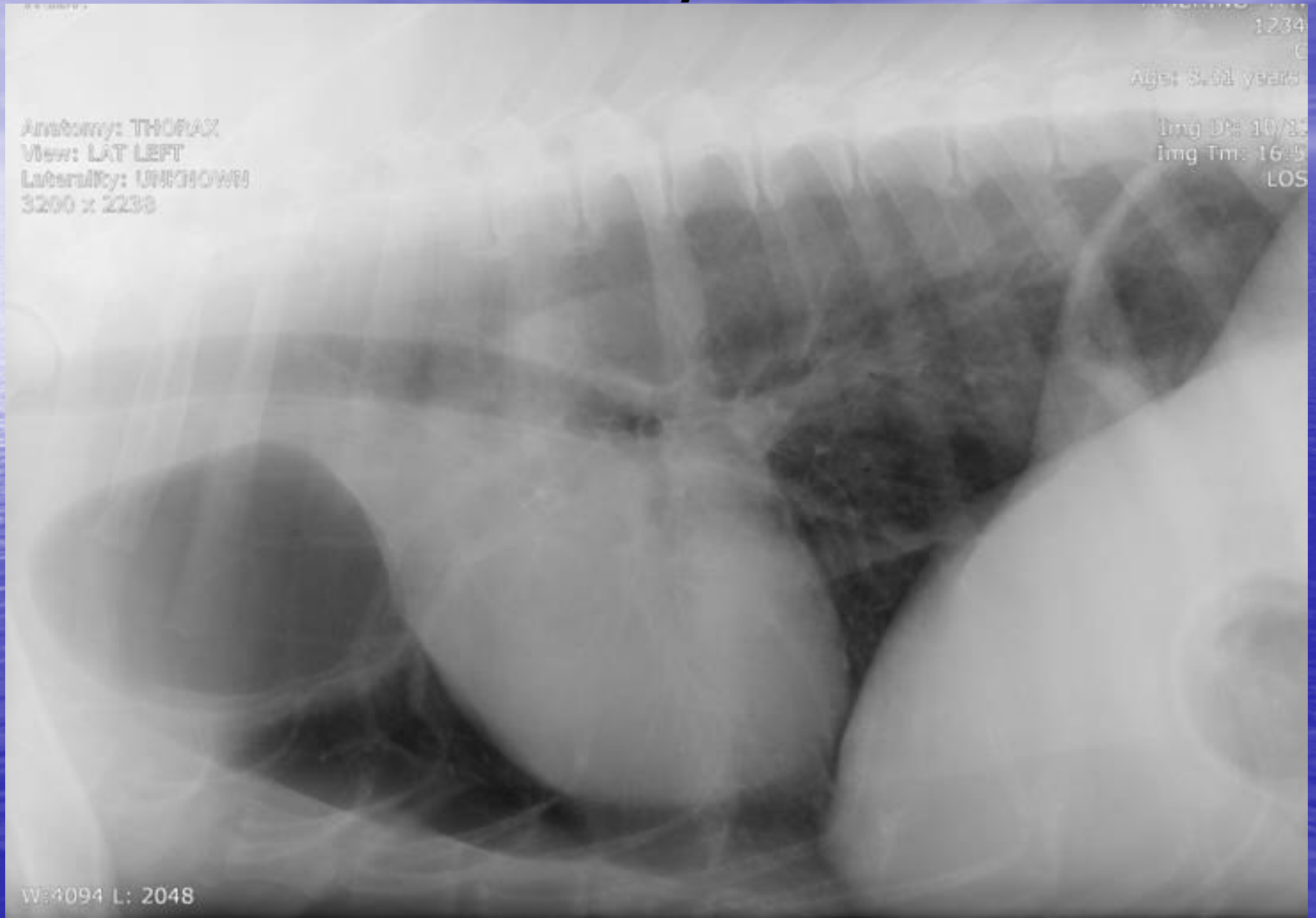DX

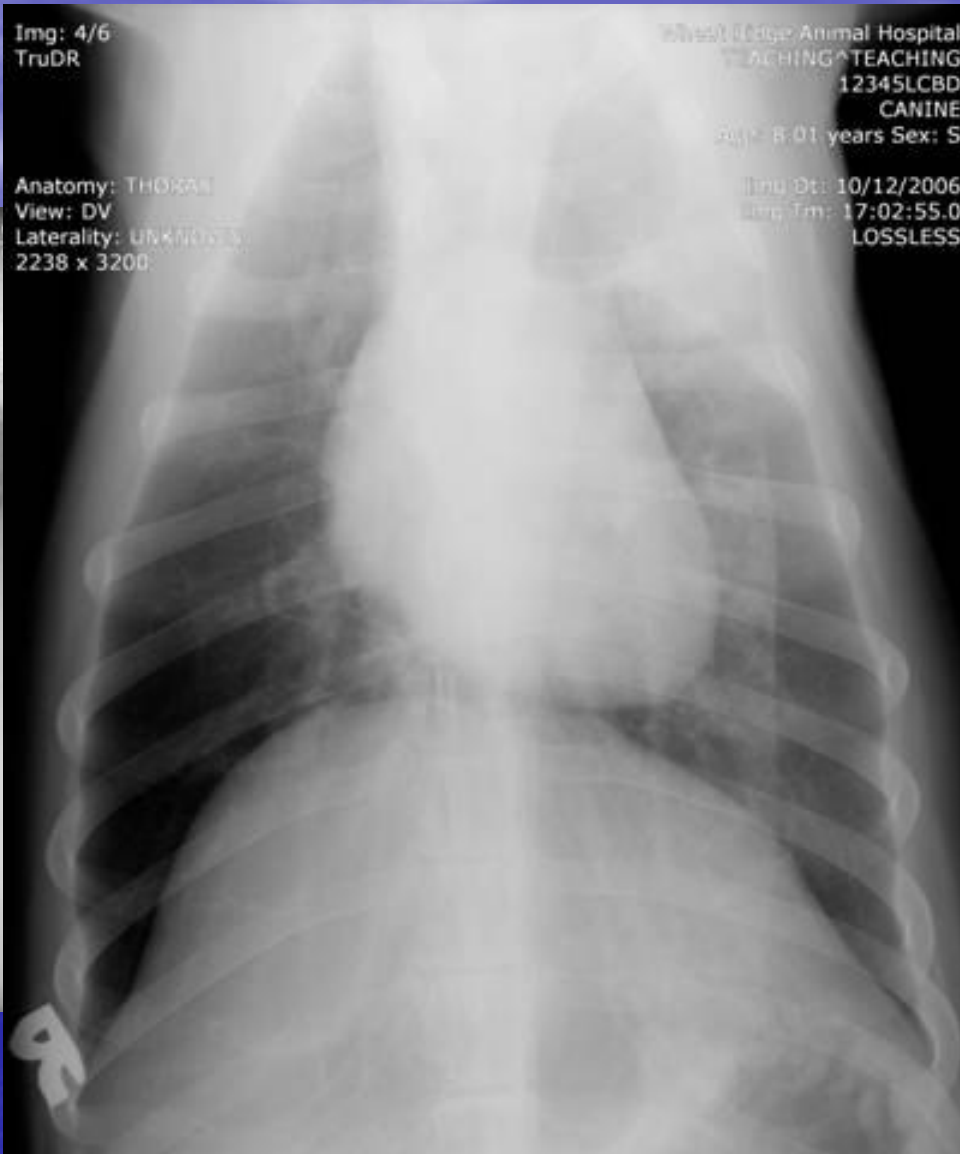
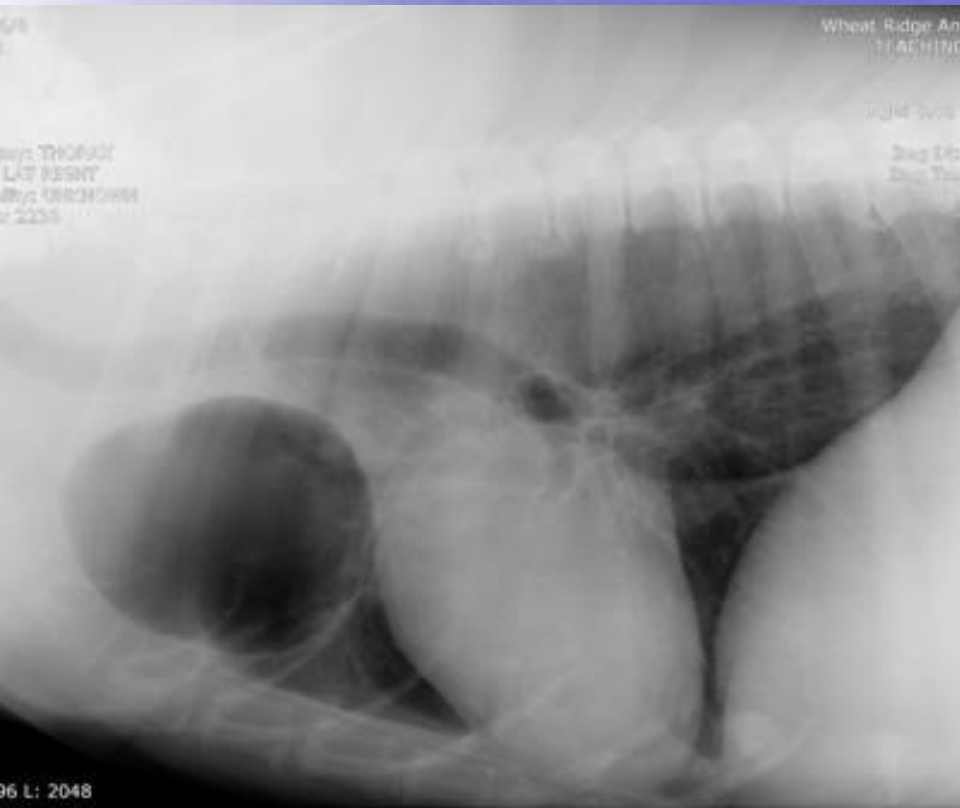Bella- 9 yr Lab FS





Alex – 8 yr Germ



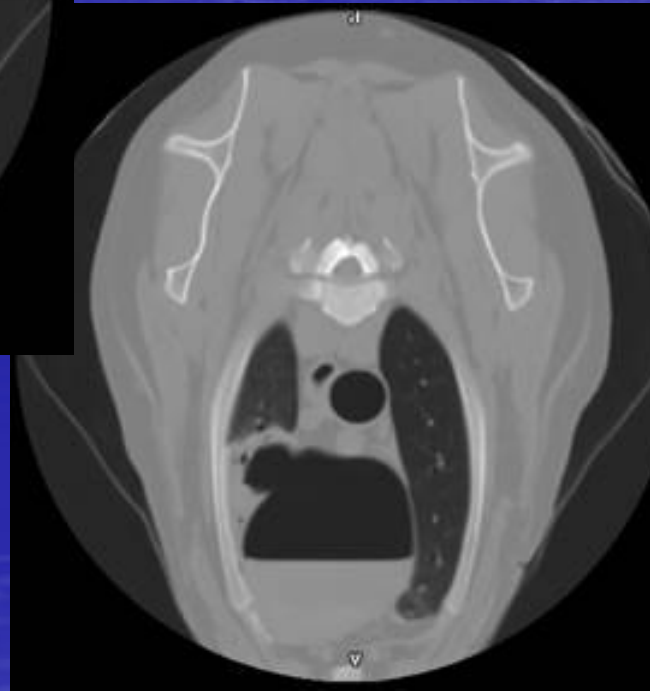
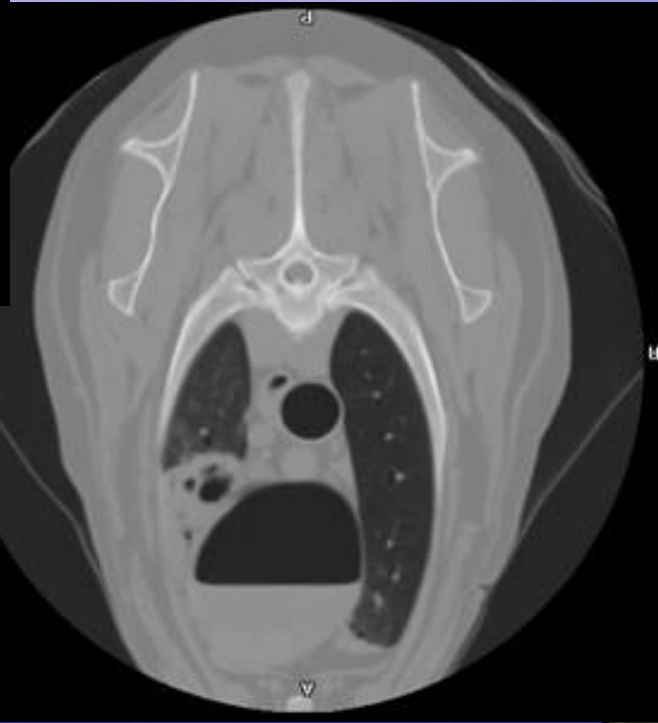
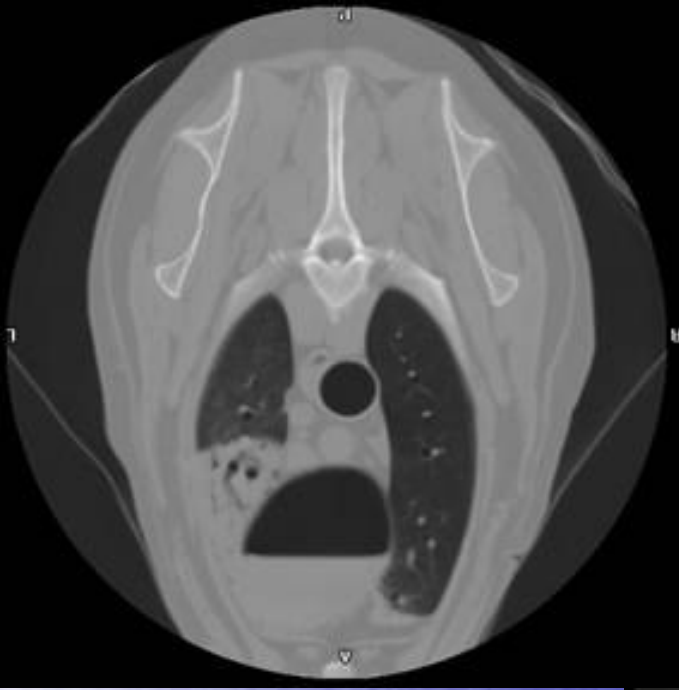


Img: 4/6
TruDR

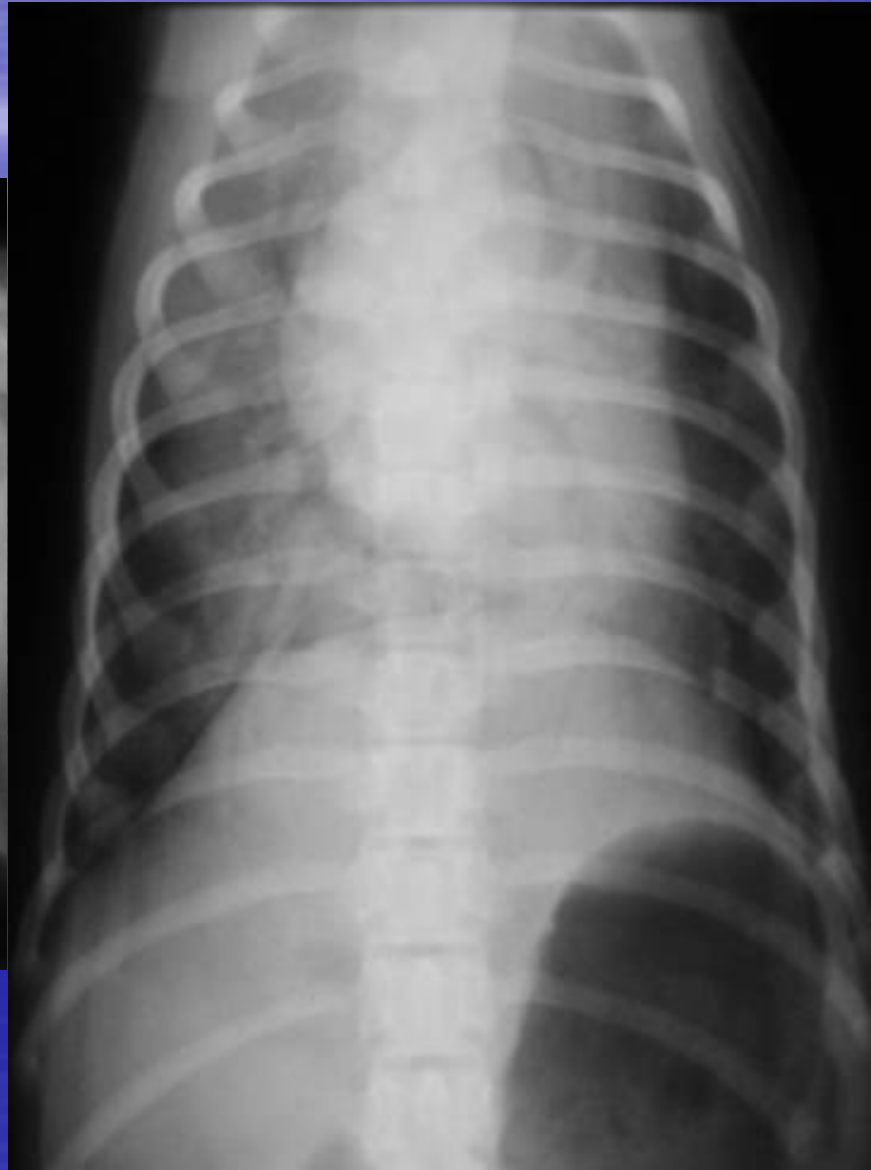
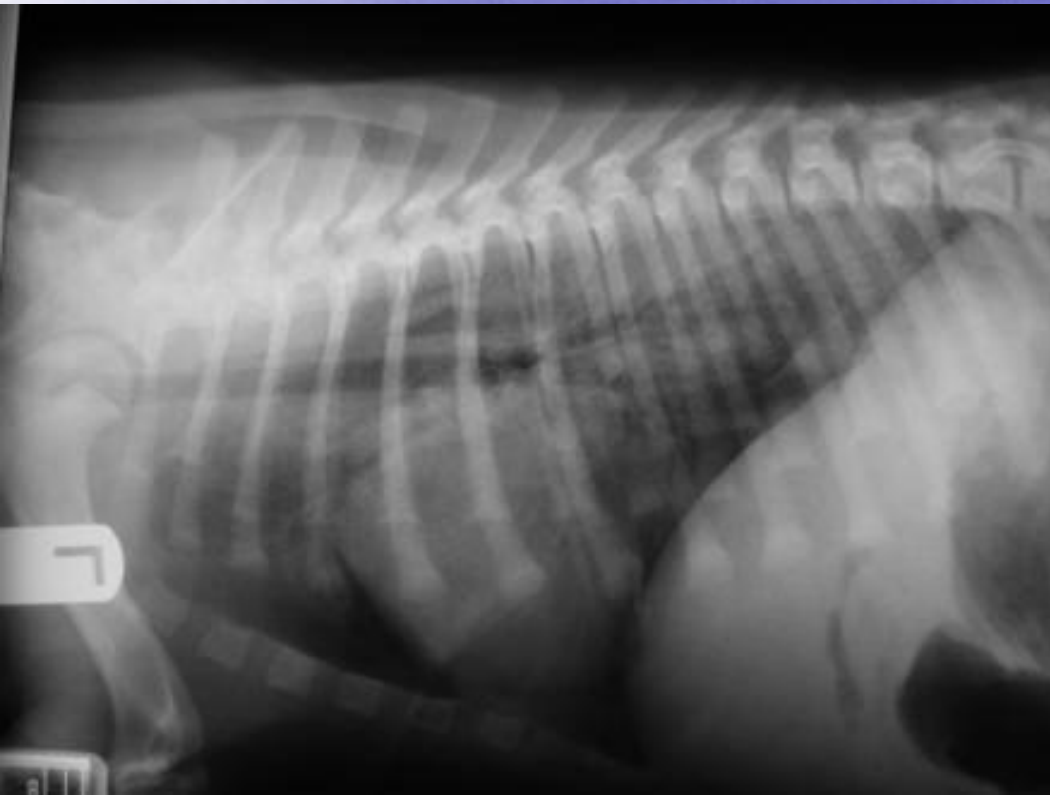
Anatomy: THORAX
View: DV
Laterality: UNKNOWN
2238 x 3200

Wheat Ridge Animal Hospital
TEACHING
12345LCBD
CANINE
Age: 8-01 years Sex: S

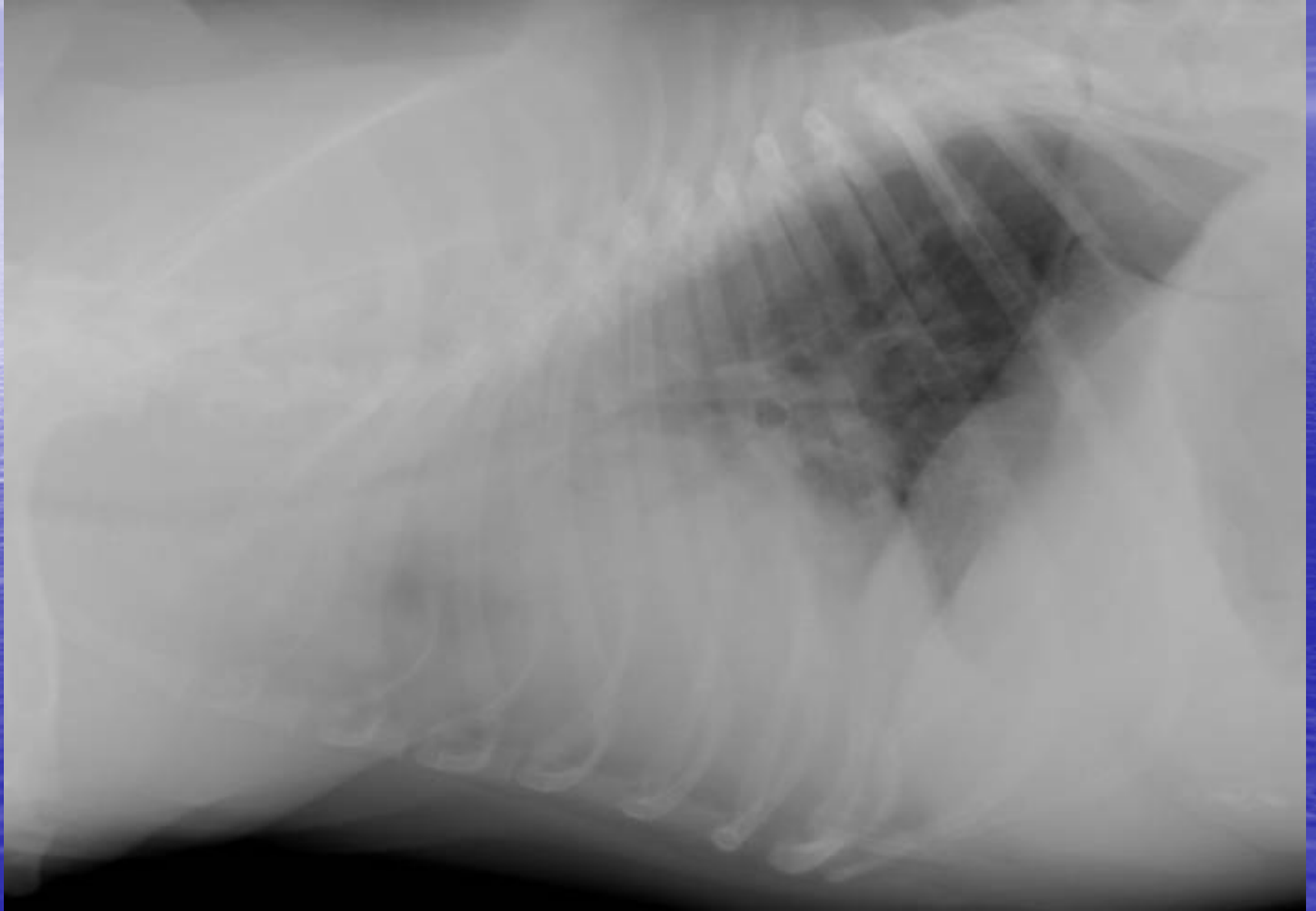
Img Dt: 10/12/2006
Img Tm: 17:02:55.0
LOSSLESS

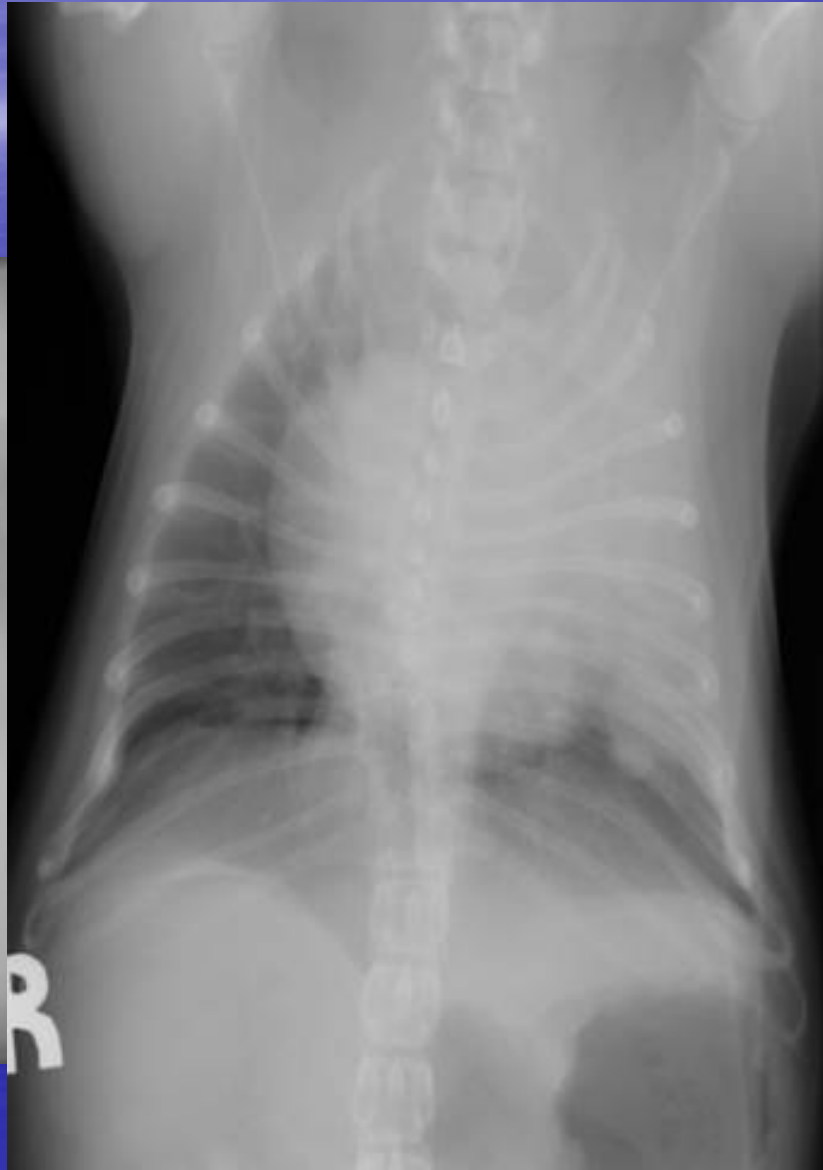
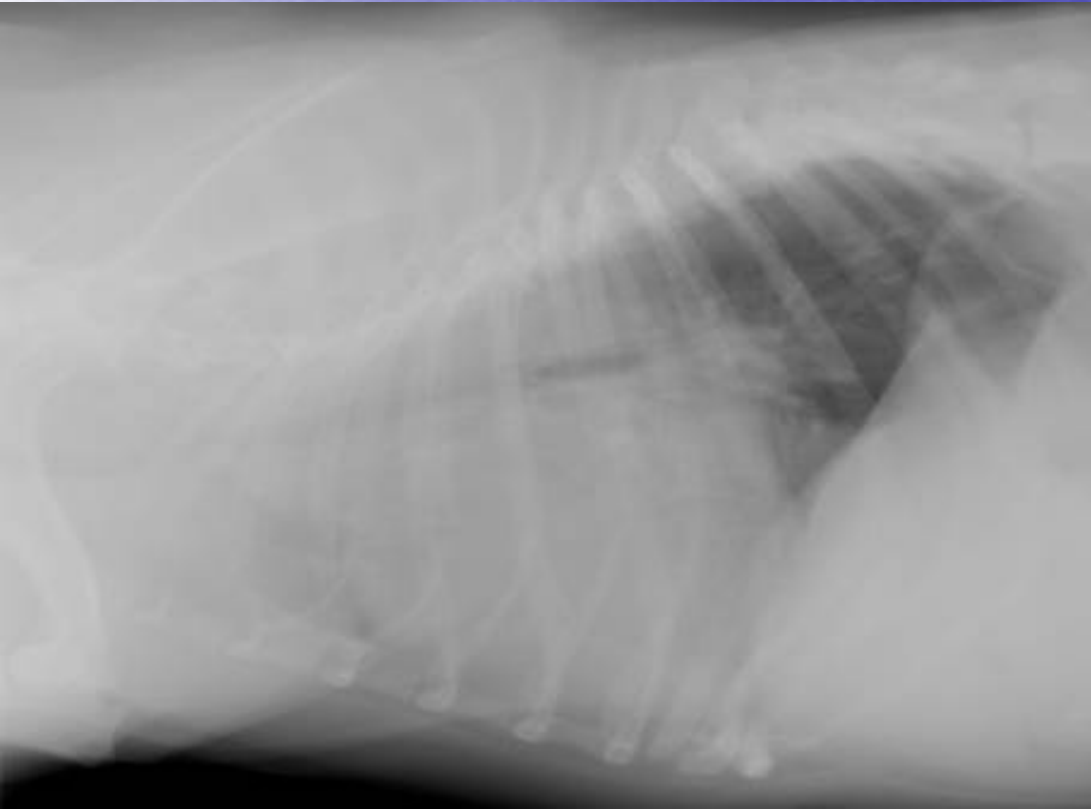
Puppy

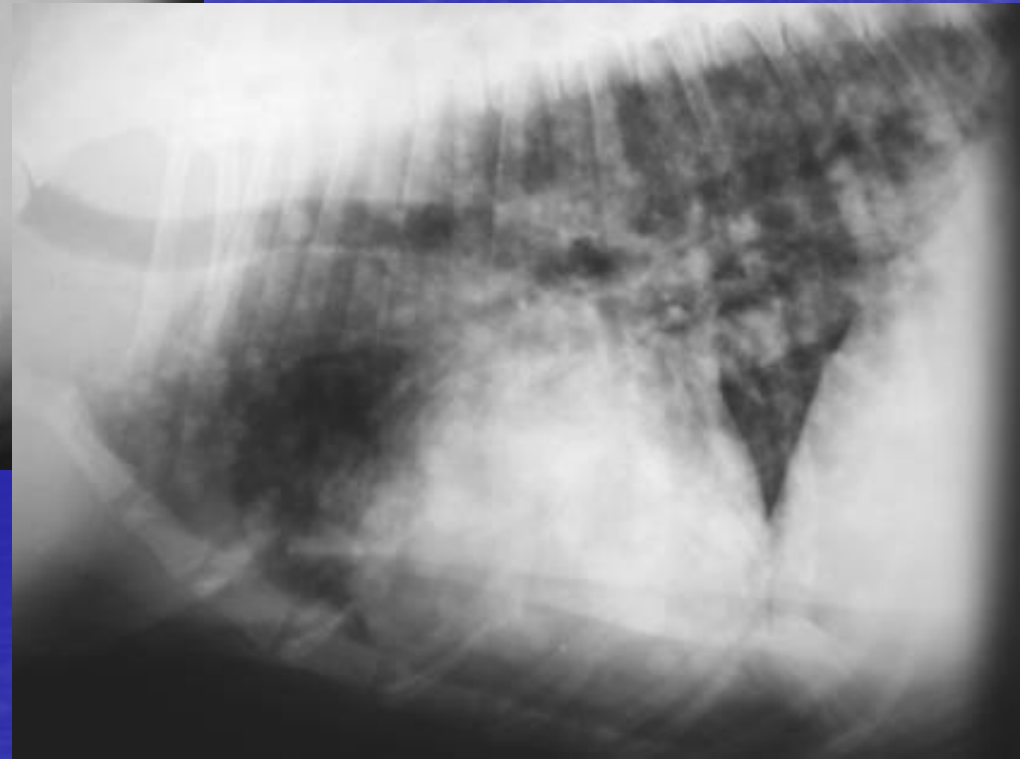
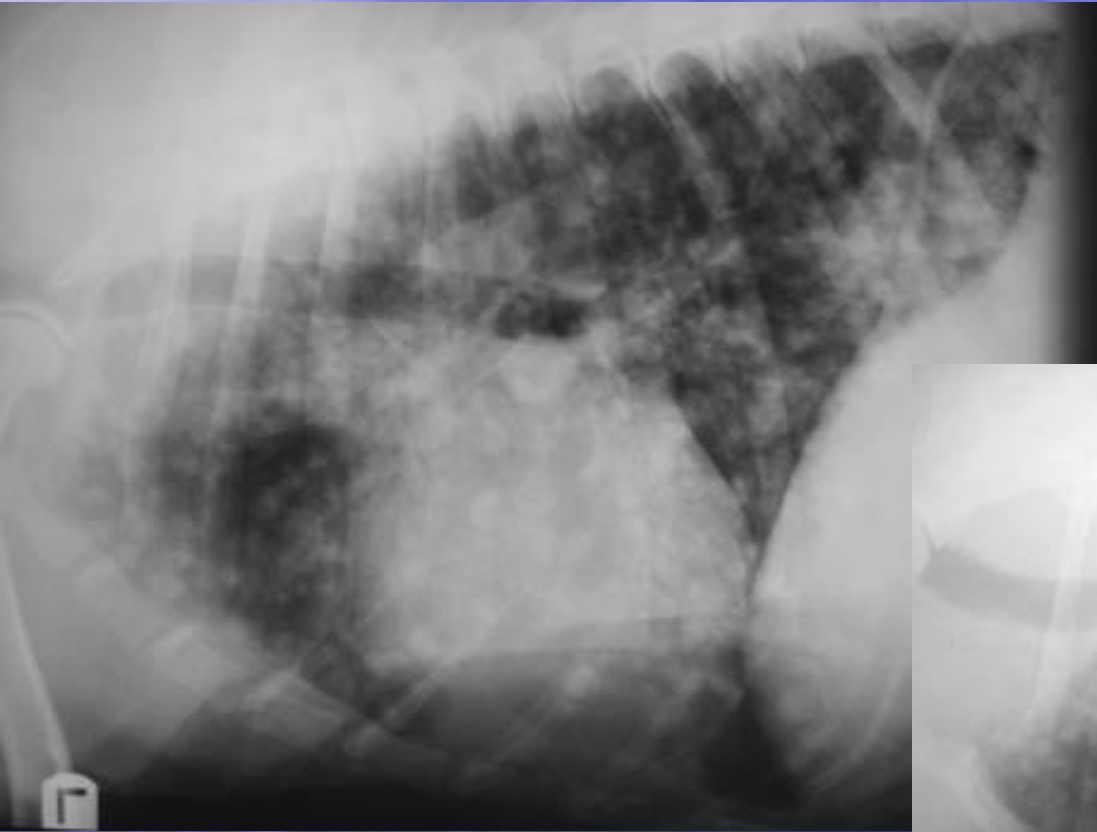


Bridgett – 2 yr Eng Bull

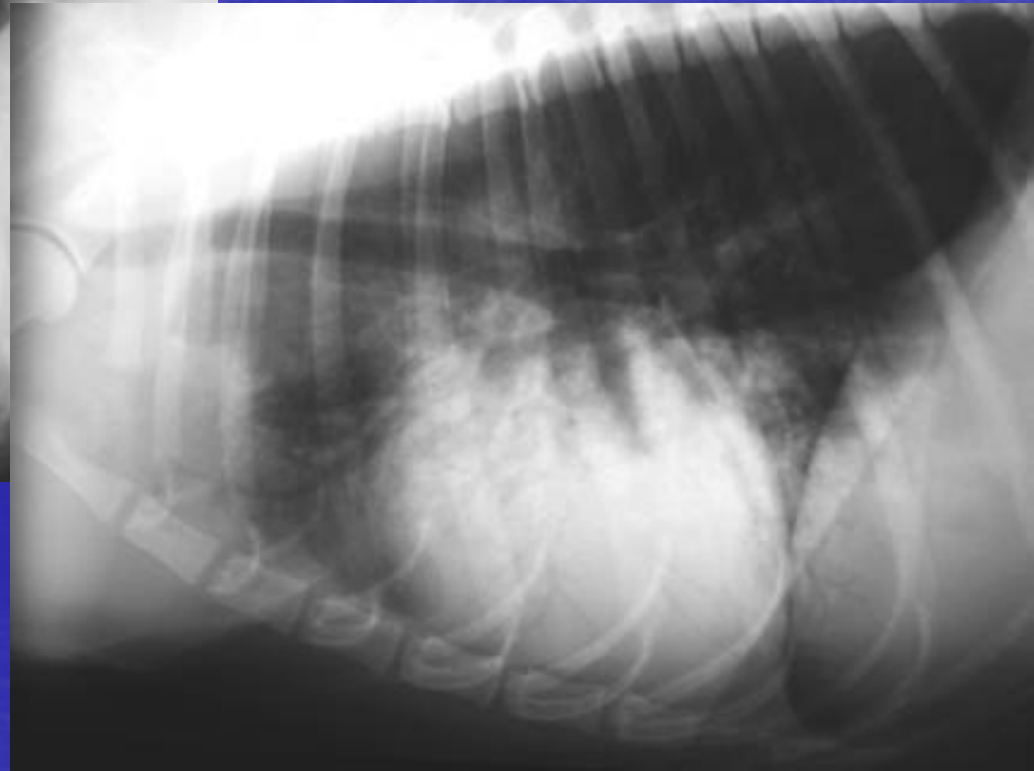
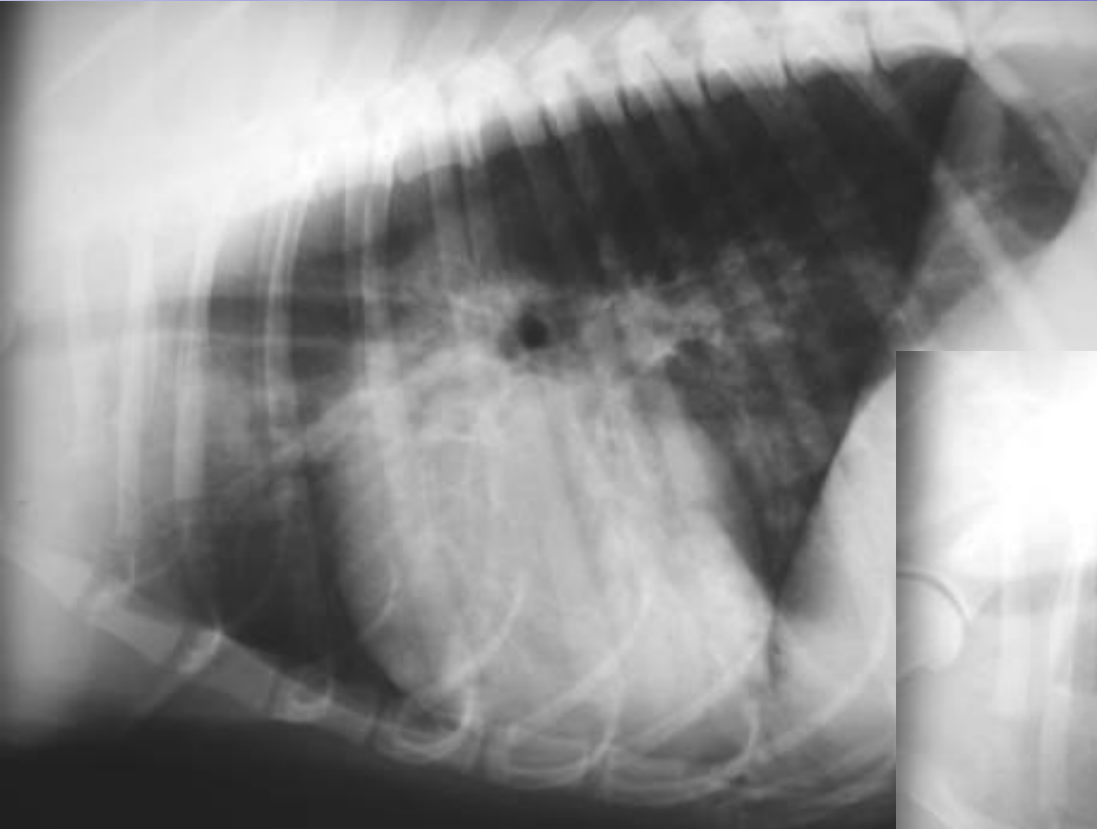




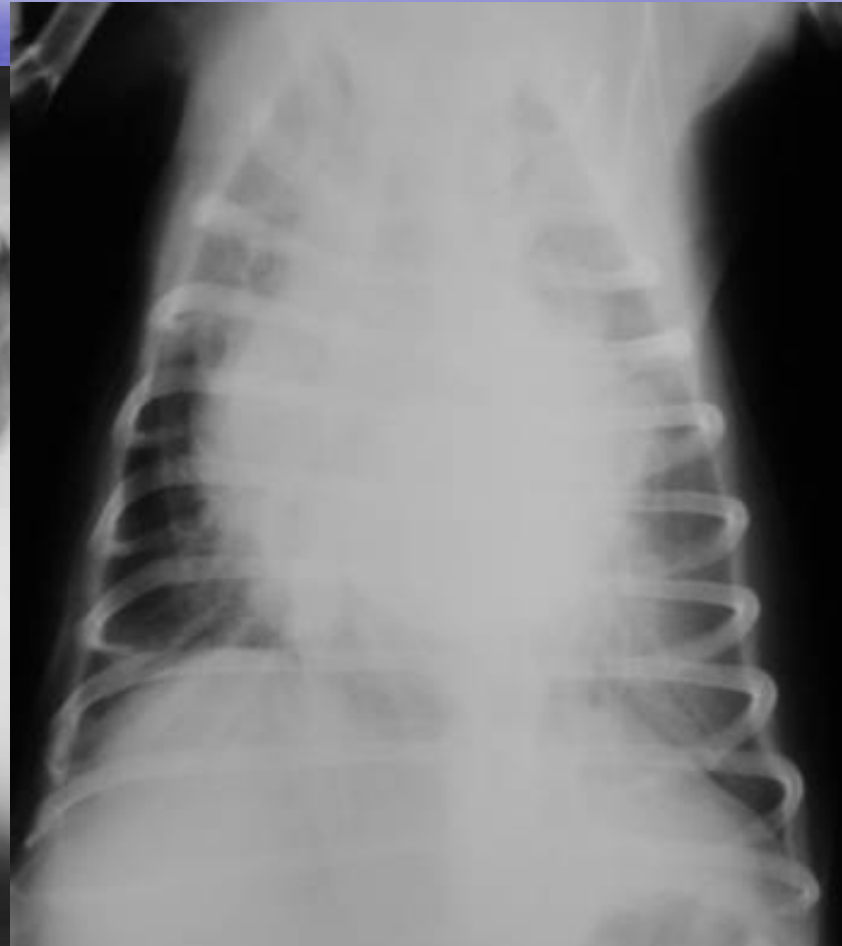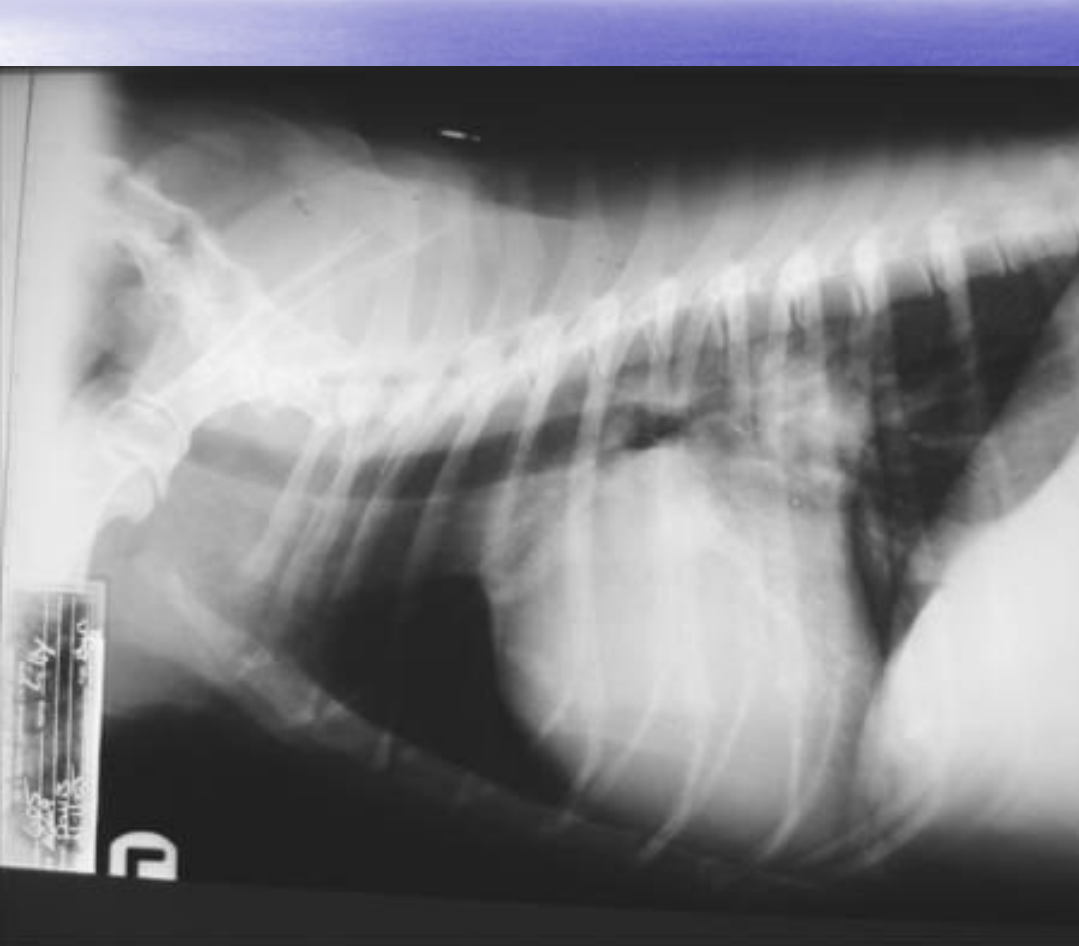Flag – 10 yr GLDR



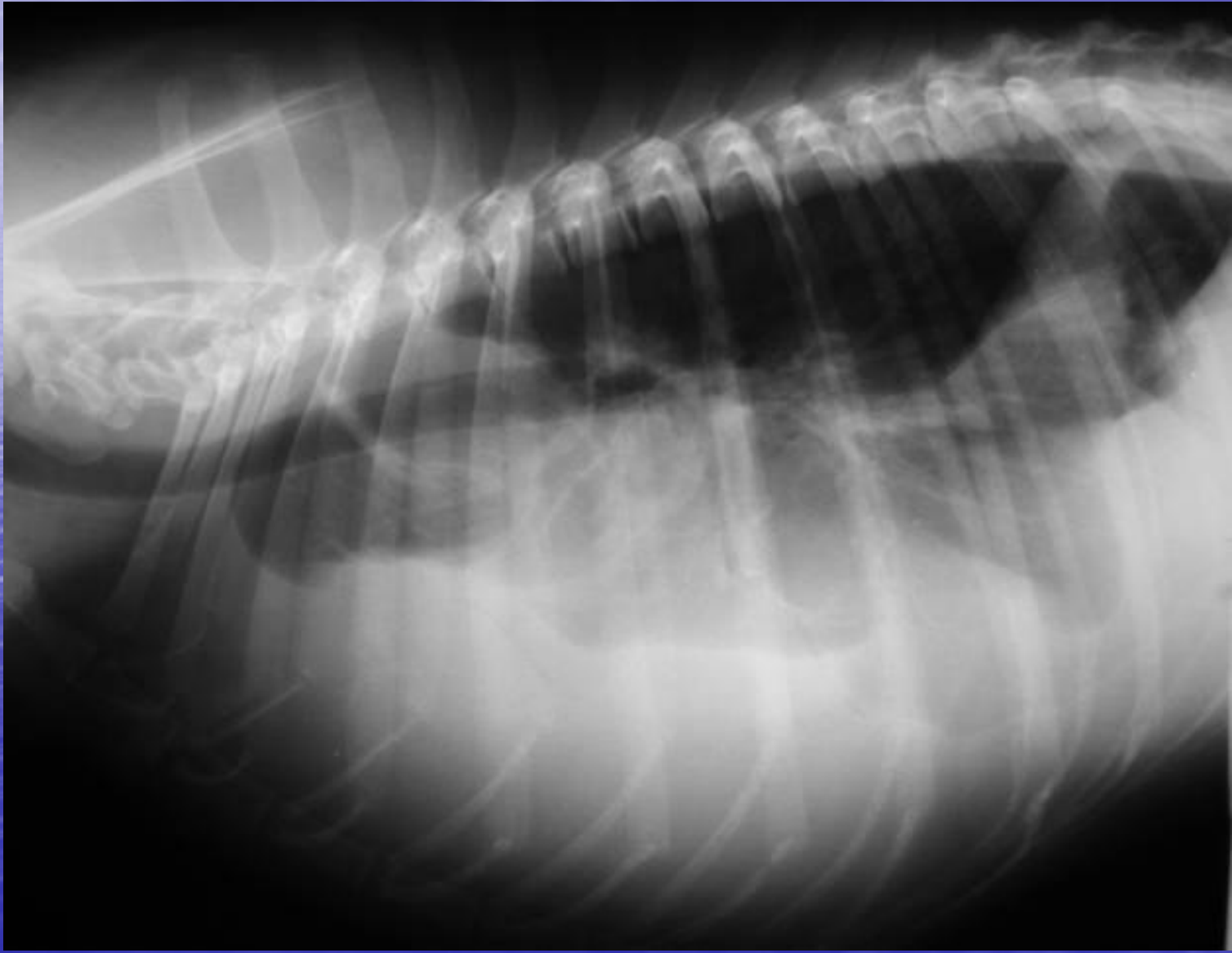
Lady Bird – 2 yr lab



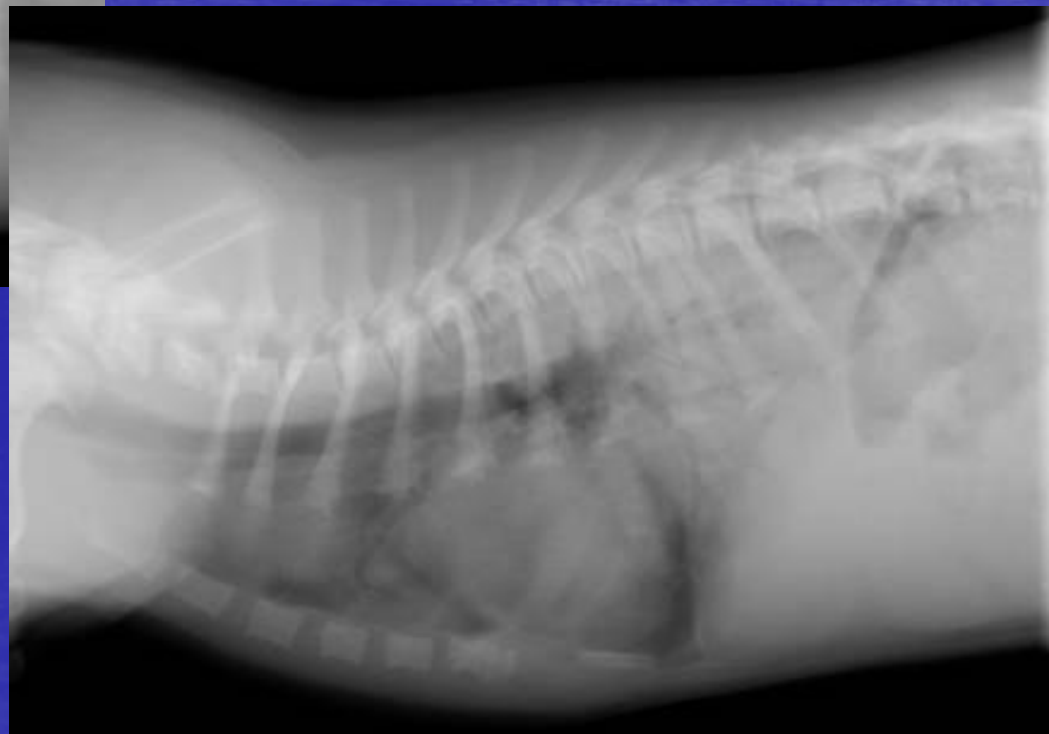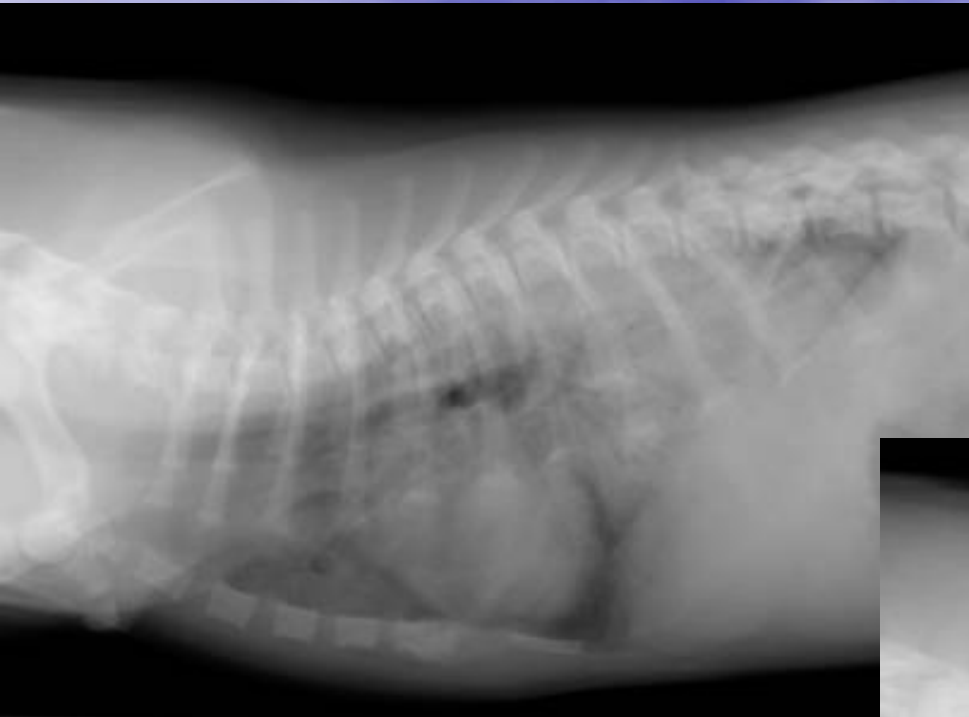Lily – 13yr old canine



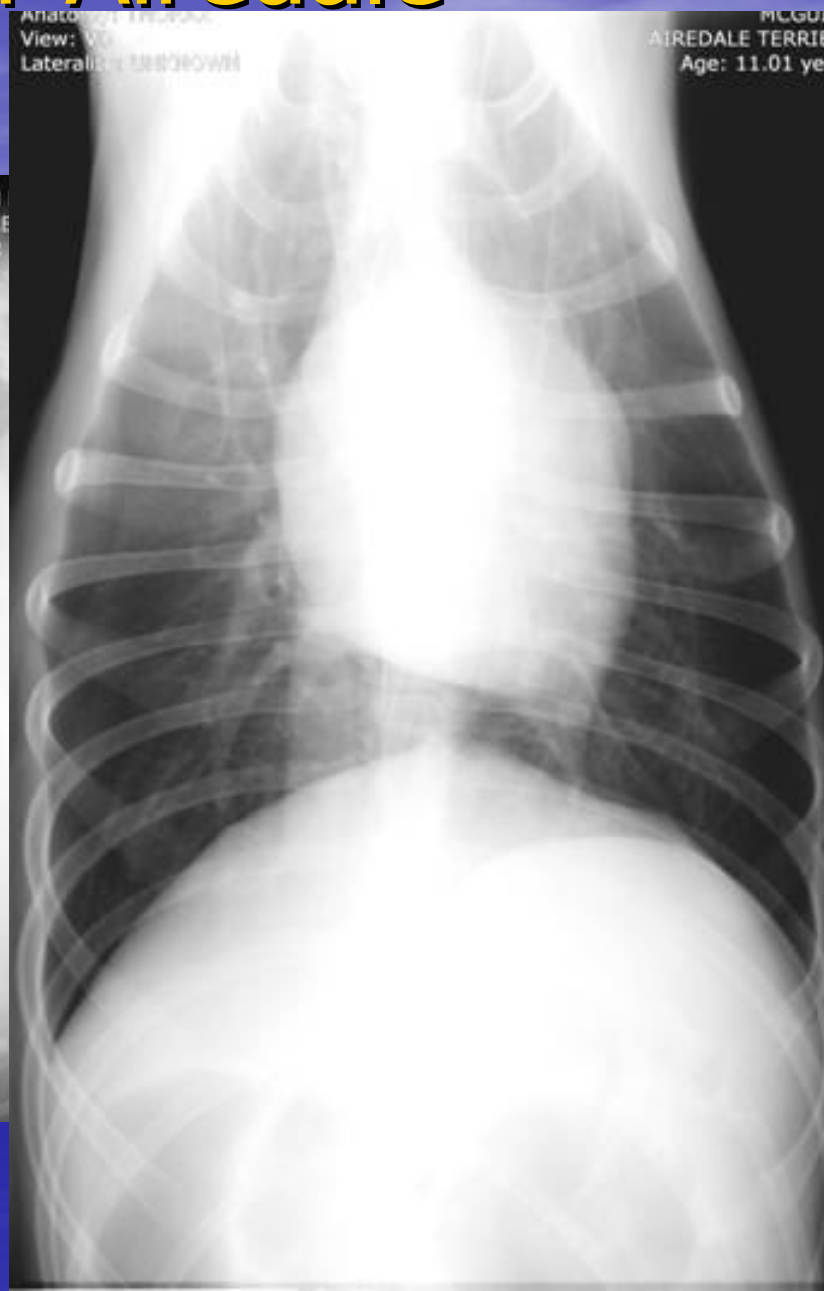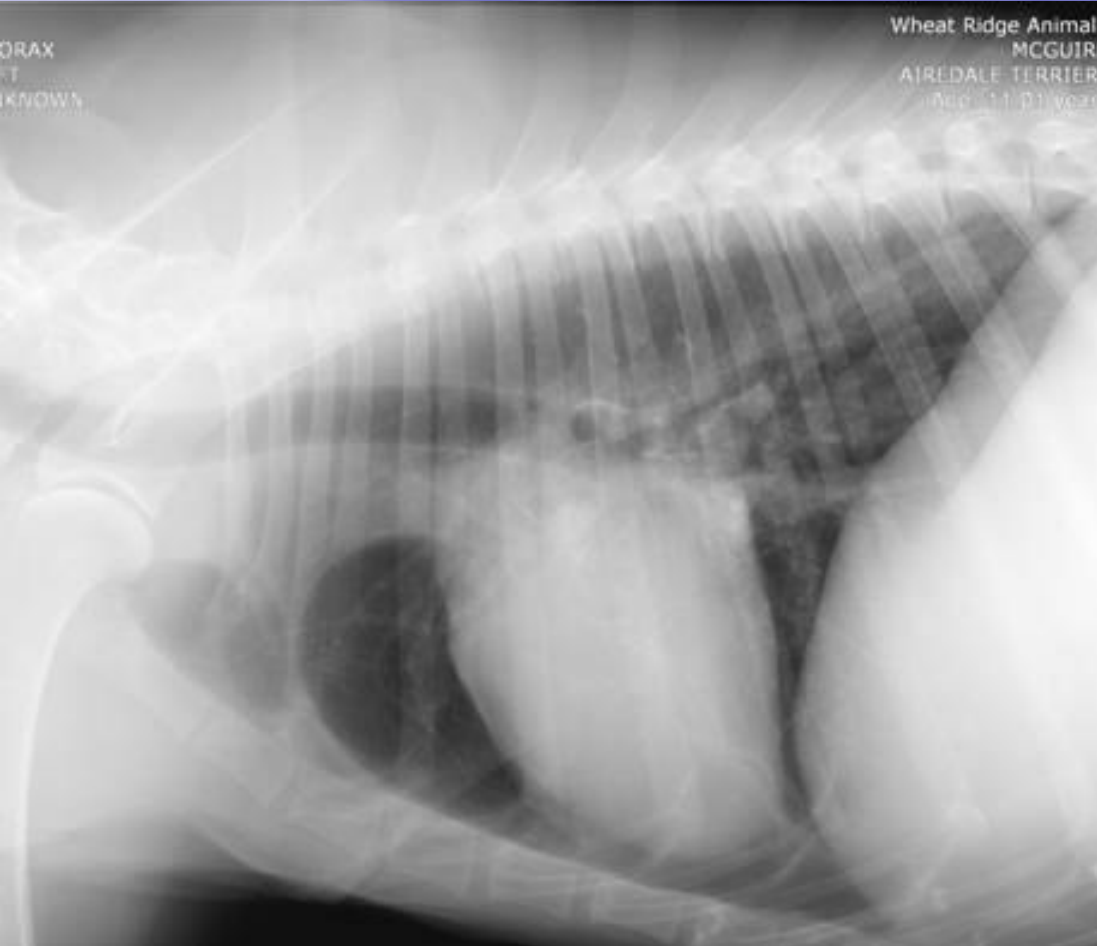Kaili – 12 yr GLDR



Cowboy – 18 wk Corgi

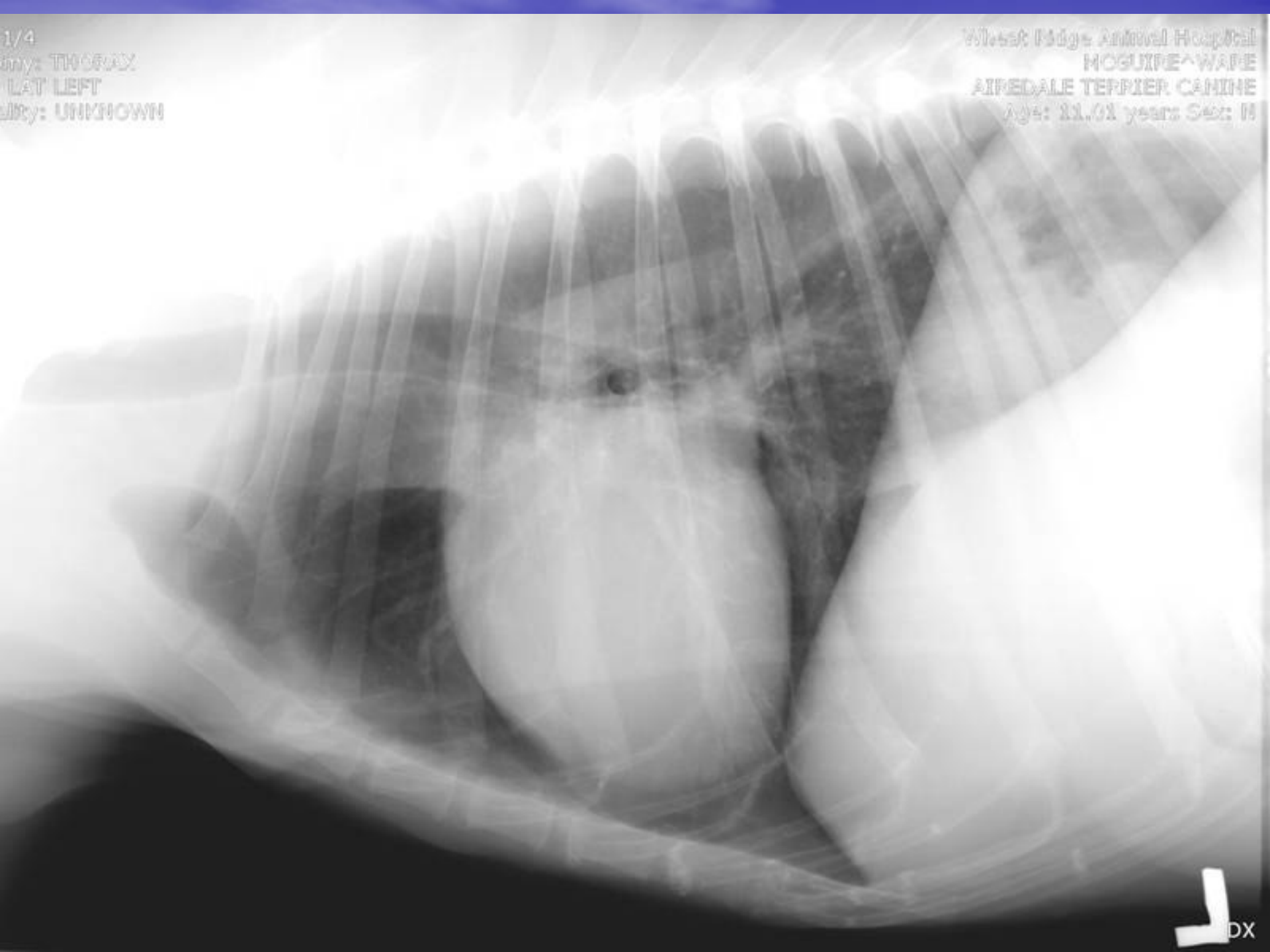


McGuire – 11 yr Airedale



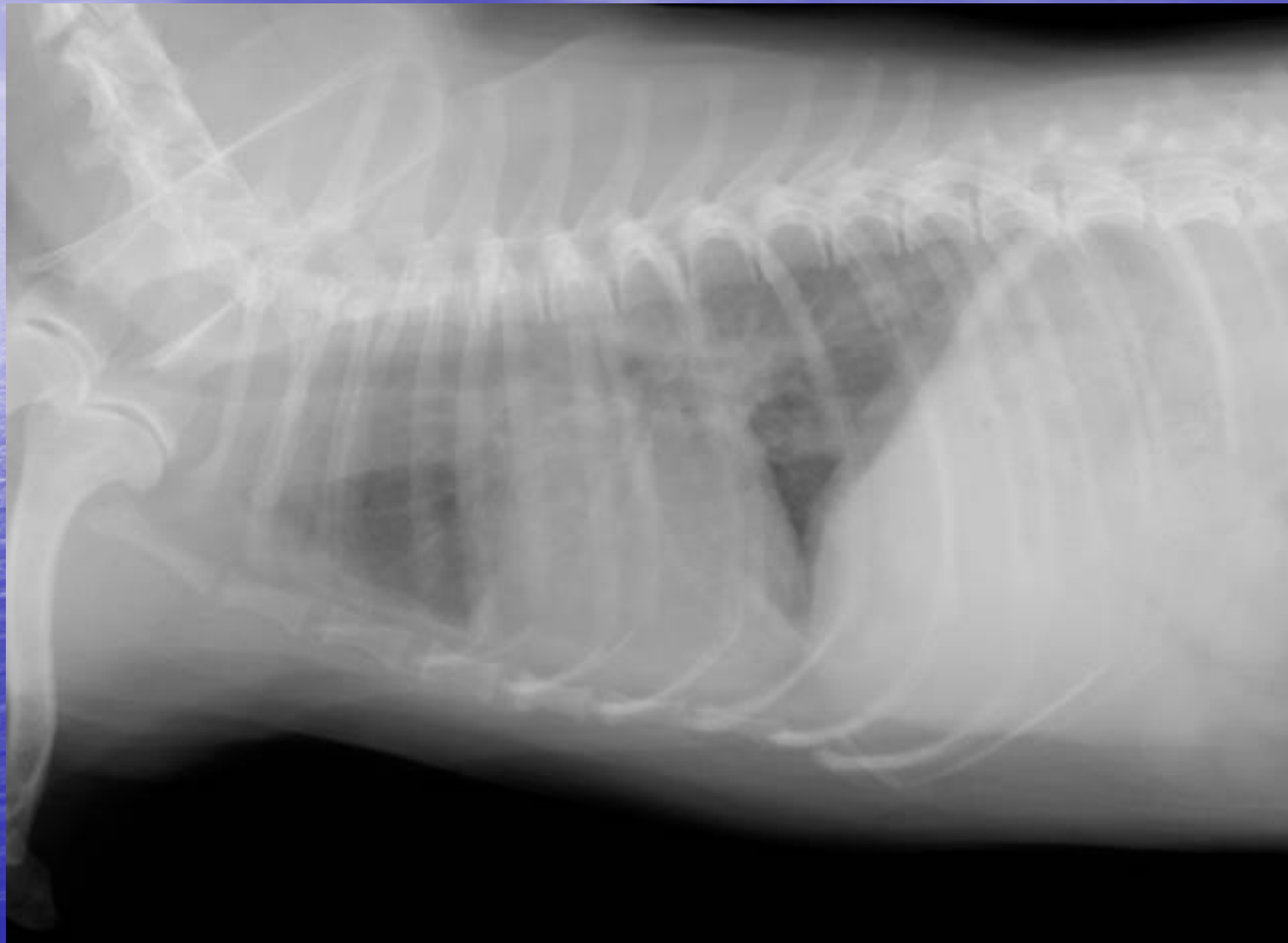1/4
Date: 11/06/03
LAT LEFT
Breed: UNKNOWN

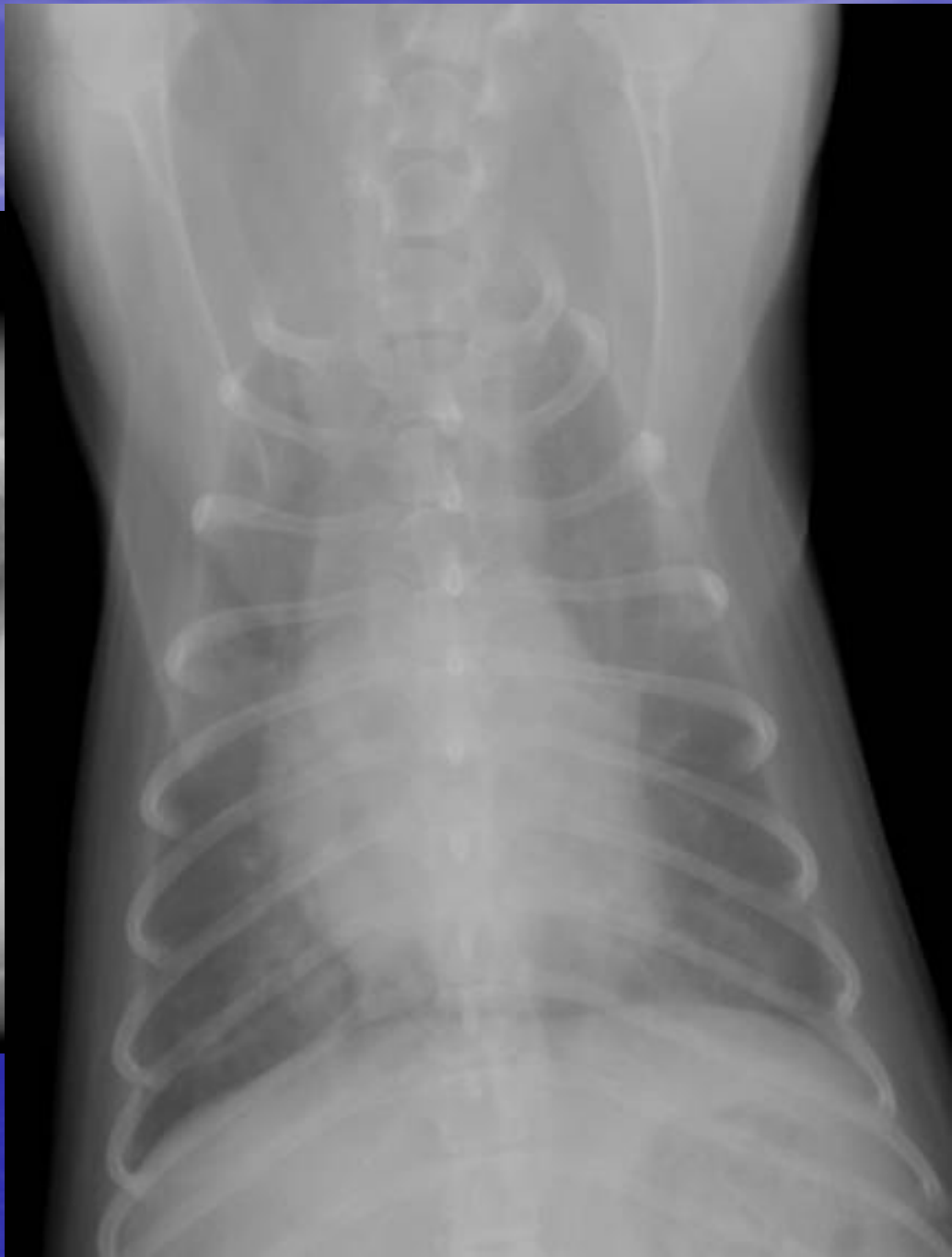
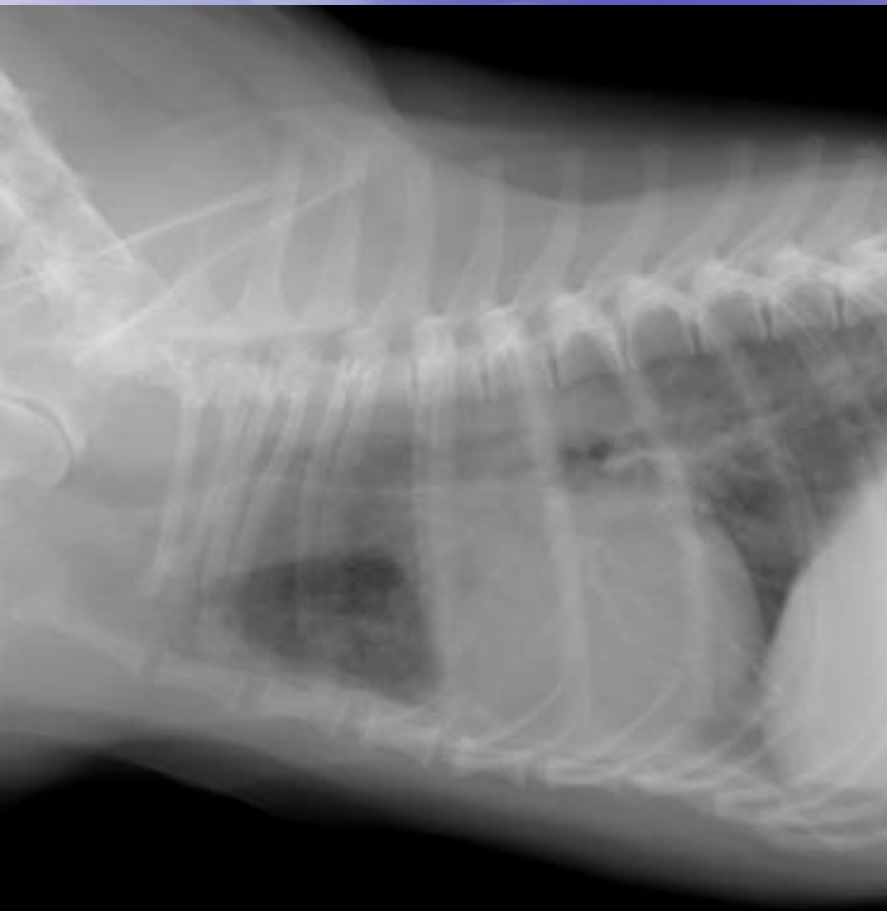Wheat Ridge Animal Hospital
MOQUINE^WAPE
Airedale Terrier Canine
Age: 11.01 years Sex: M



DX

Theo – 14 yr Shih Tzu





Aly – 12 yr Germ

Img 2/5
TruDR

Wheat Ridge Animal Hospital
ALY WILLIS
BUSHBY
WISCONSIN
Age: 13:00 years

Anatomy: THORAX
View: UNKNOWN
Laterality: UNKNOWN
3200 X 2228

Img Dt: 09/22/2006
Img Tm: 22:47:28.0
LOSSLESS

W:4095 L: 2048

DX

Img: 3/5
TruDR

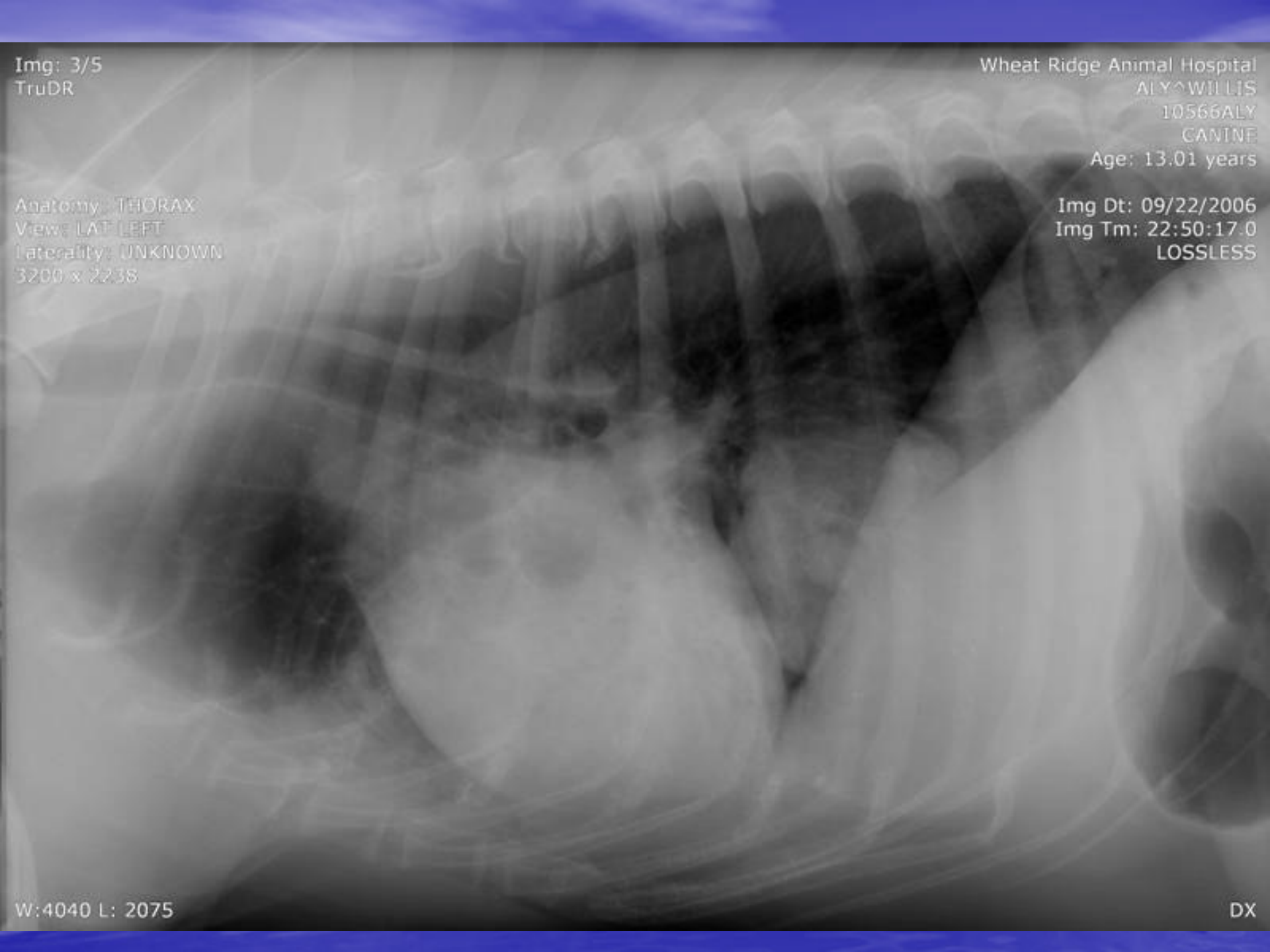Wheat Ridge Animal Hospital
ALY WILLIS
10566ALY
CANINE
Age: 13.01 years

Anatomy: THORAX
View: LAT LEFT
Laterality: UNKNOWN
3200 x 2238

Img Dt: 09/22/2006
Img Tm: 22:50:17.0
LOSSLESS

W:4040 L: 2075

DX

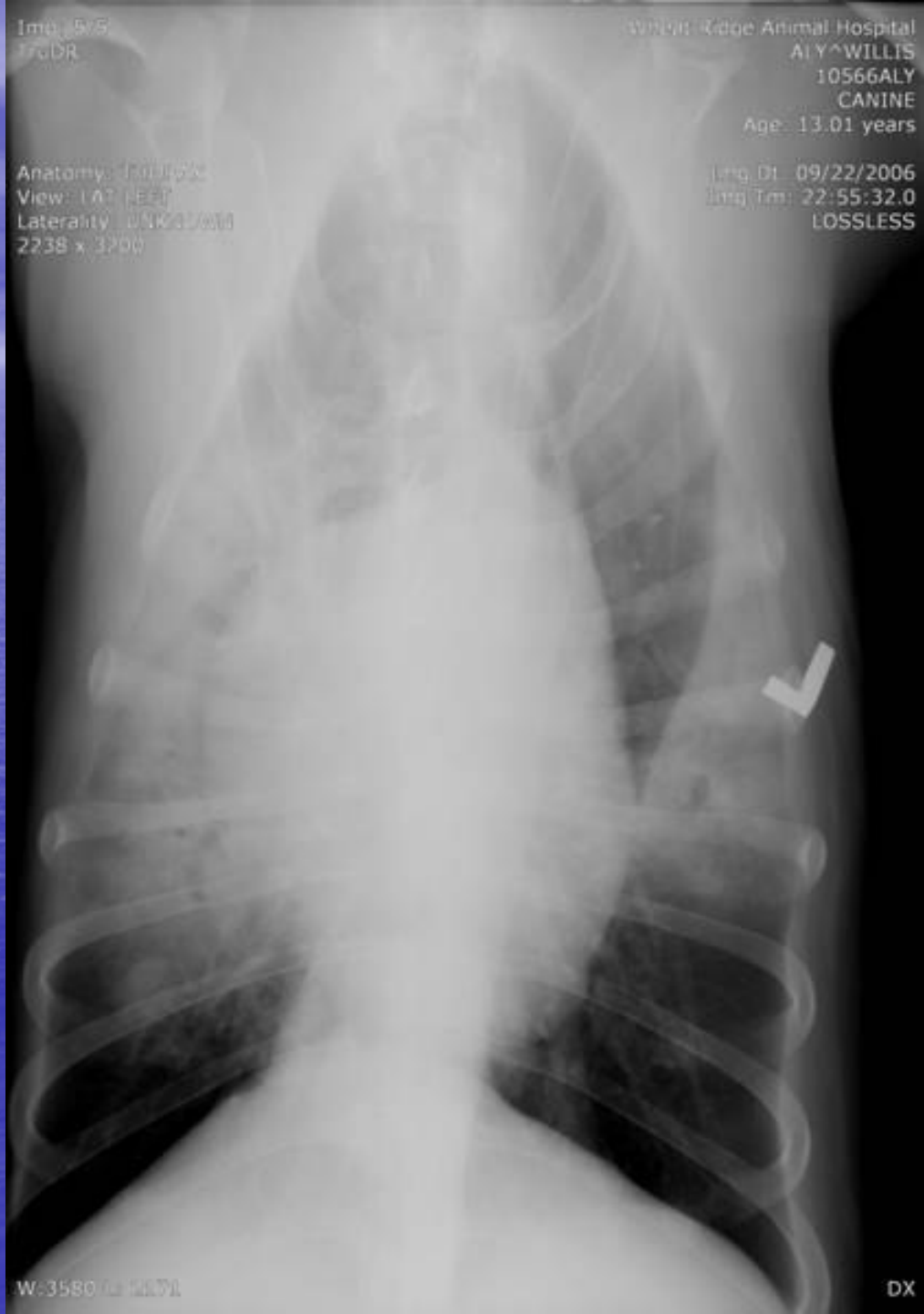

Img: 15/5
170DR

Willis Edge Animal Hospital
ALY^WILLIS
10566ALY
CANINE
Age: 13.01 years

Anatomy: 15031000
View: 107 (LEFT)
Laterality: UNKNOWN
2238 x 3200

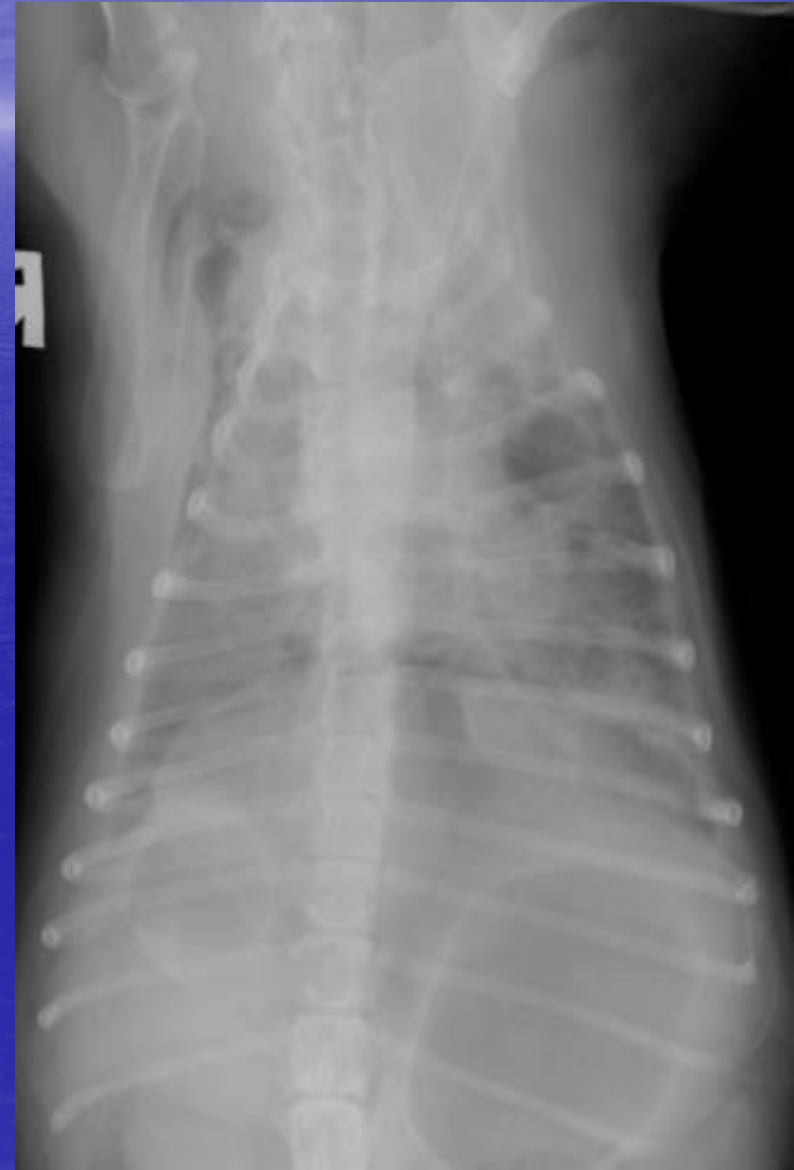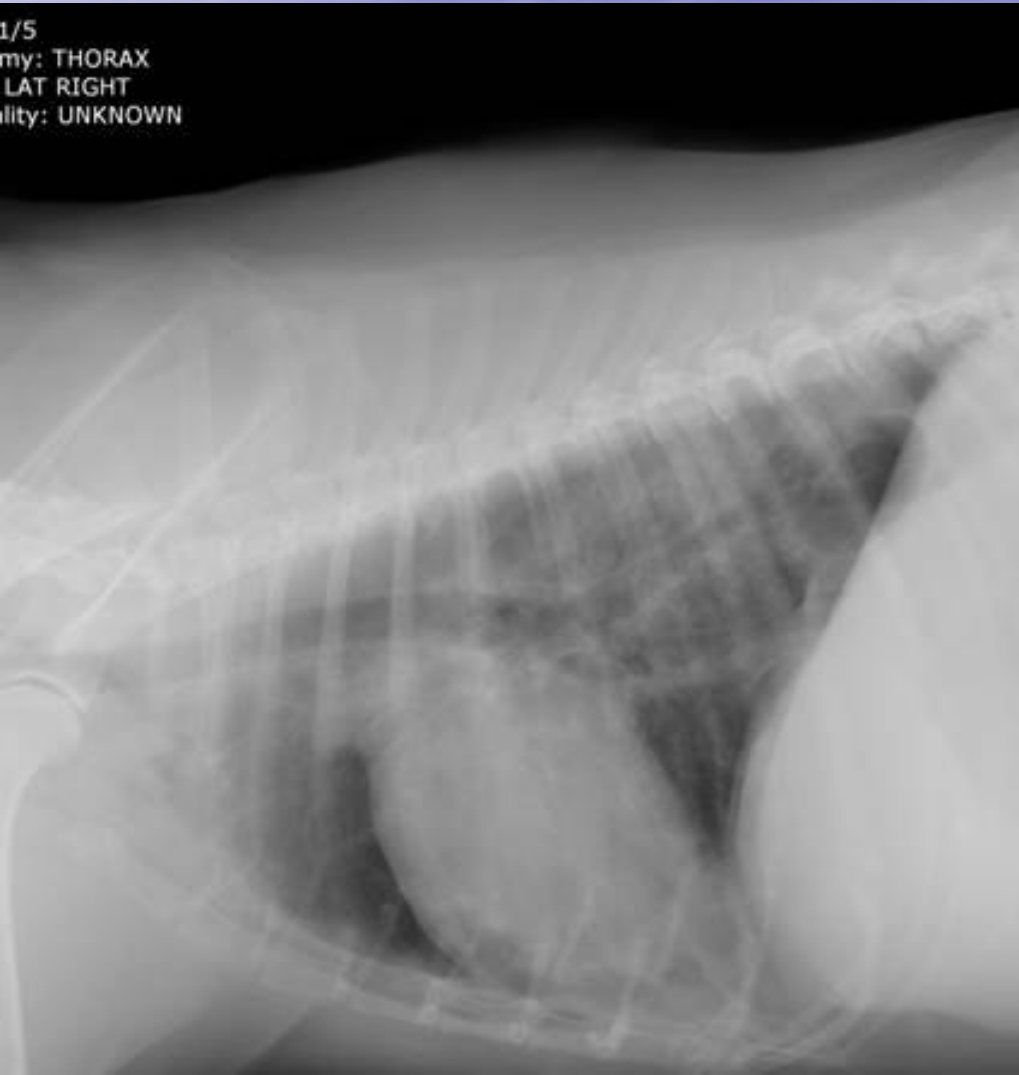Img Dt: 09/22/2006
Img Tm: 22:55:32.0
LOSSLESS



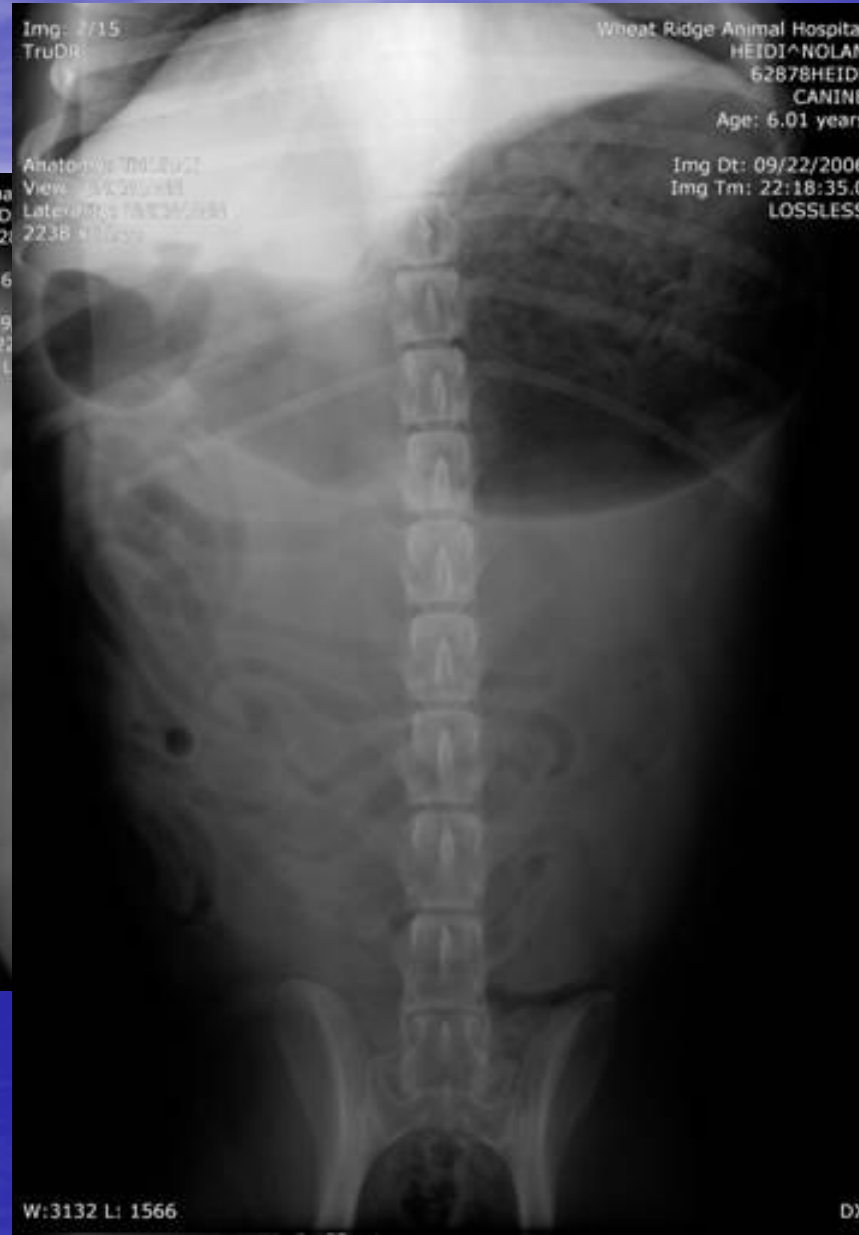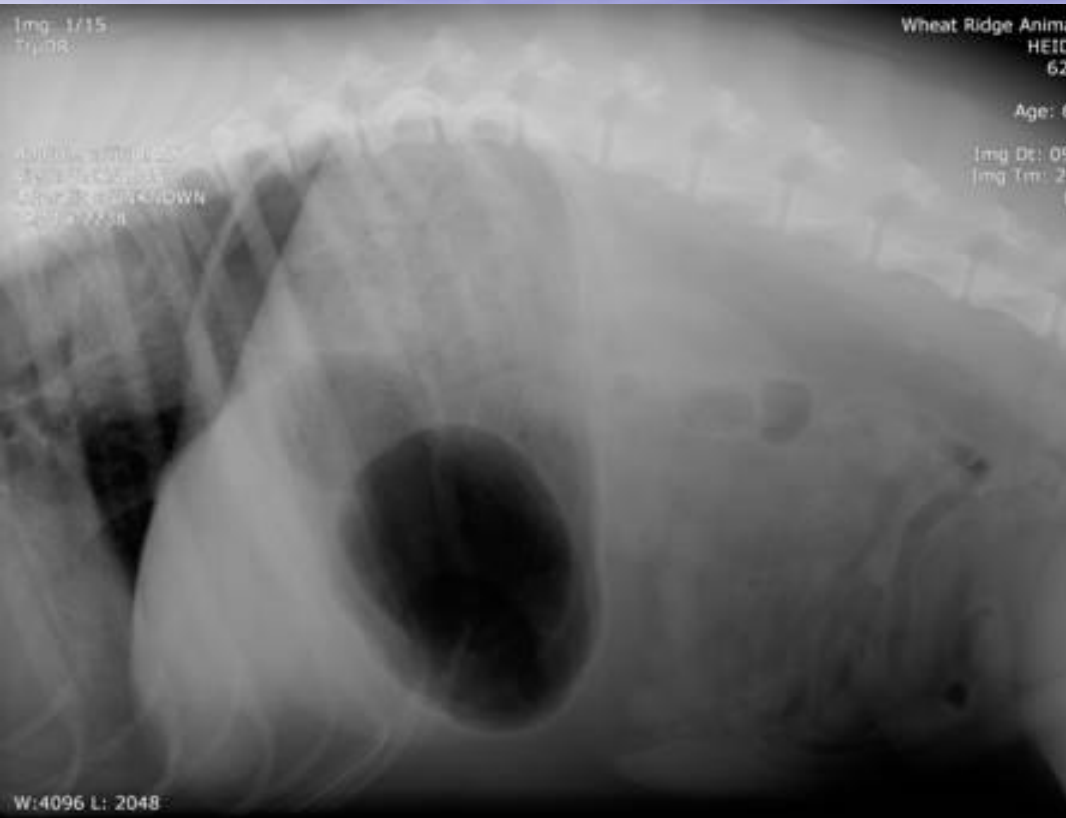W:3580 H:4471

DX

Dagney – 12yr Am Esk - HBC



Heidi – 6yr Cattle dog

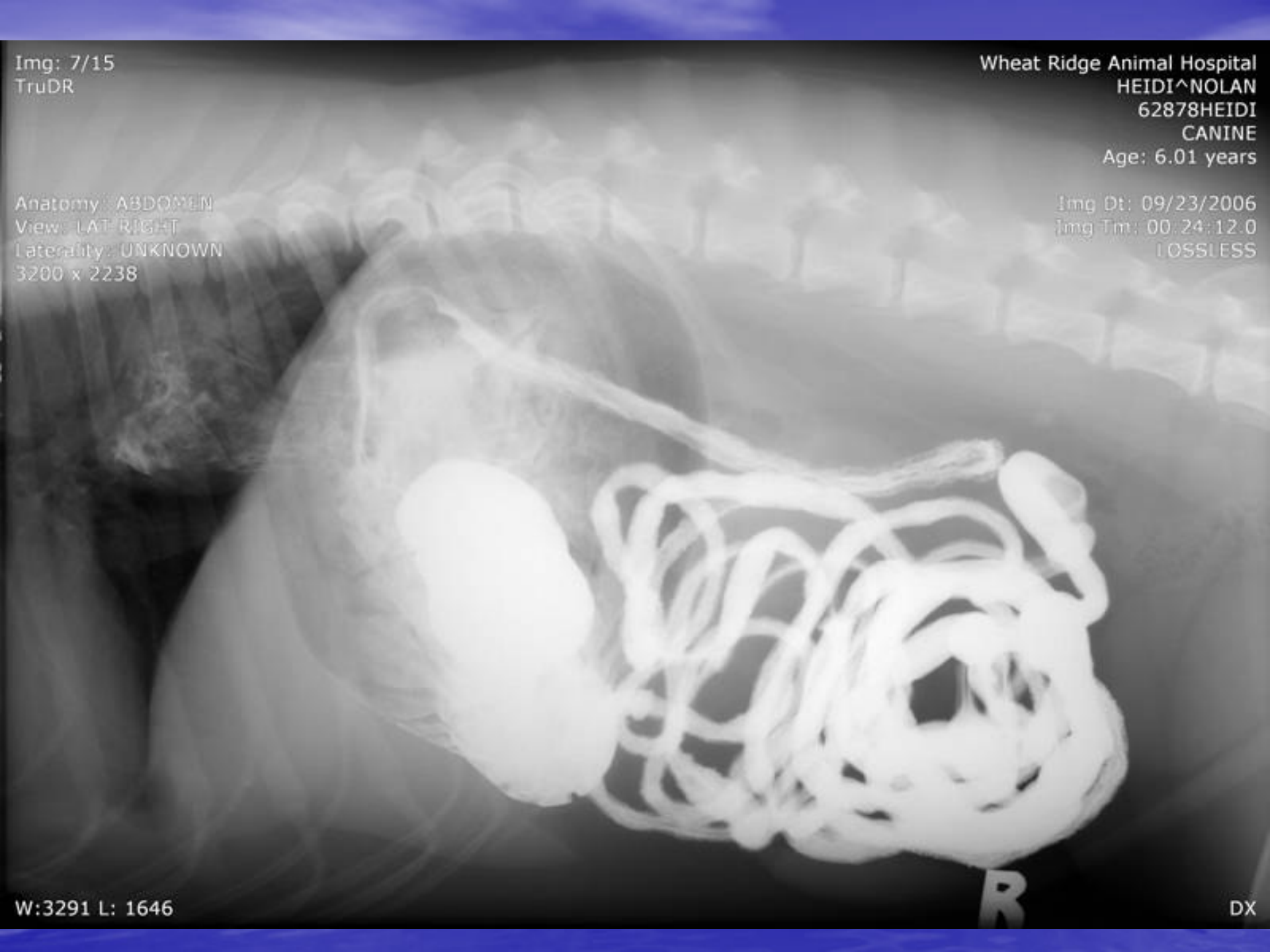


Img: 7/15
TruDR

Wheat Ridge Animal Hospital
HEIDI^NOLAN
62878HEIDI
CANINE
Age: 6.01 years

Anatomy: ABDOMEN
View: LAT RIGHT
Laterality: UNKNOWN
3200 x 2238

Img Dt: 09/23/2006
Img Tm: 00:24:12.0
LOSSLESS

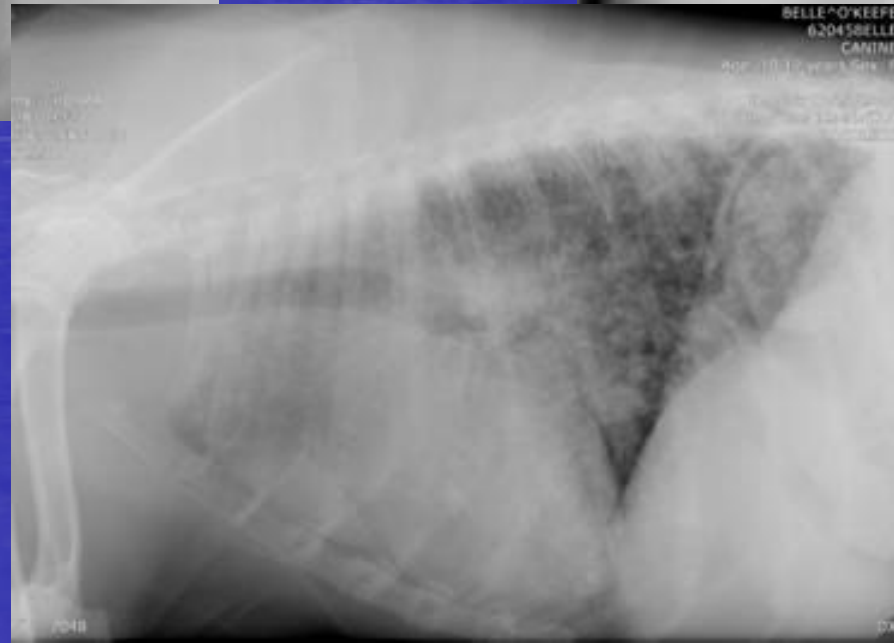
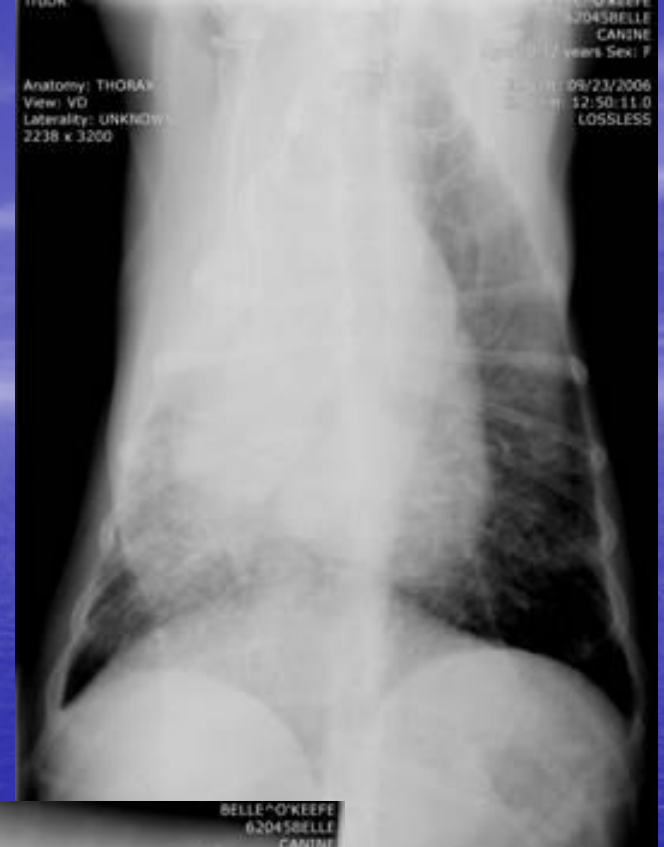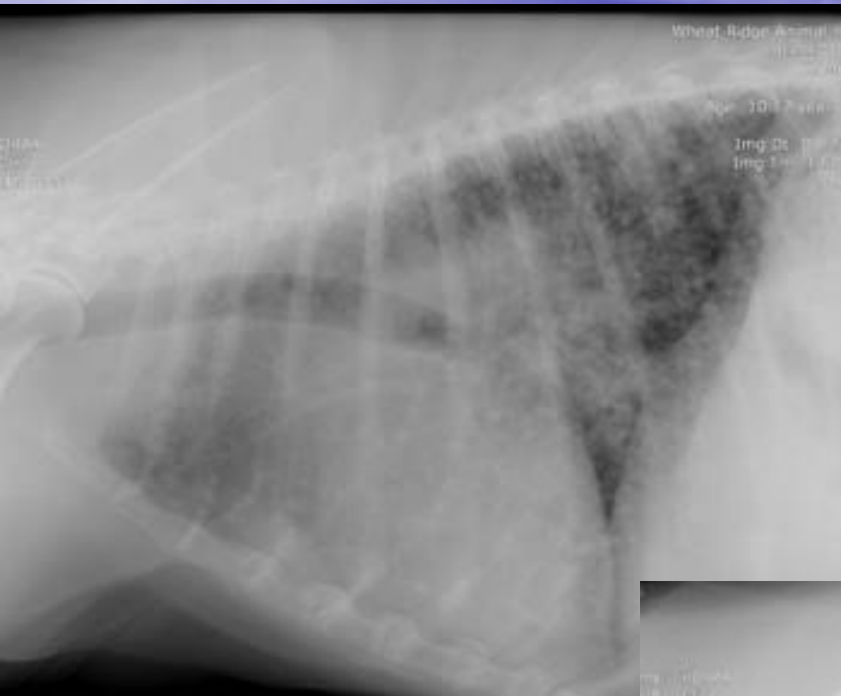


W:3291 L: 1646

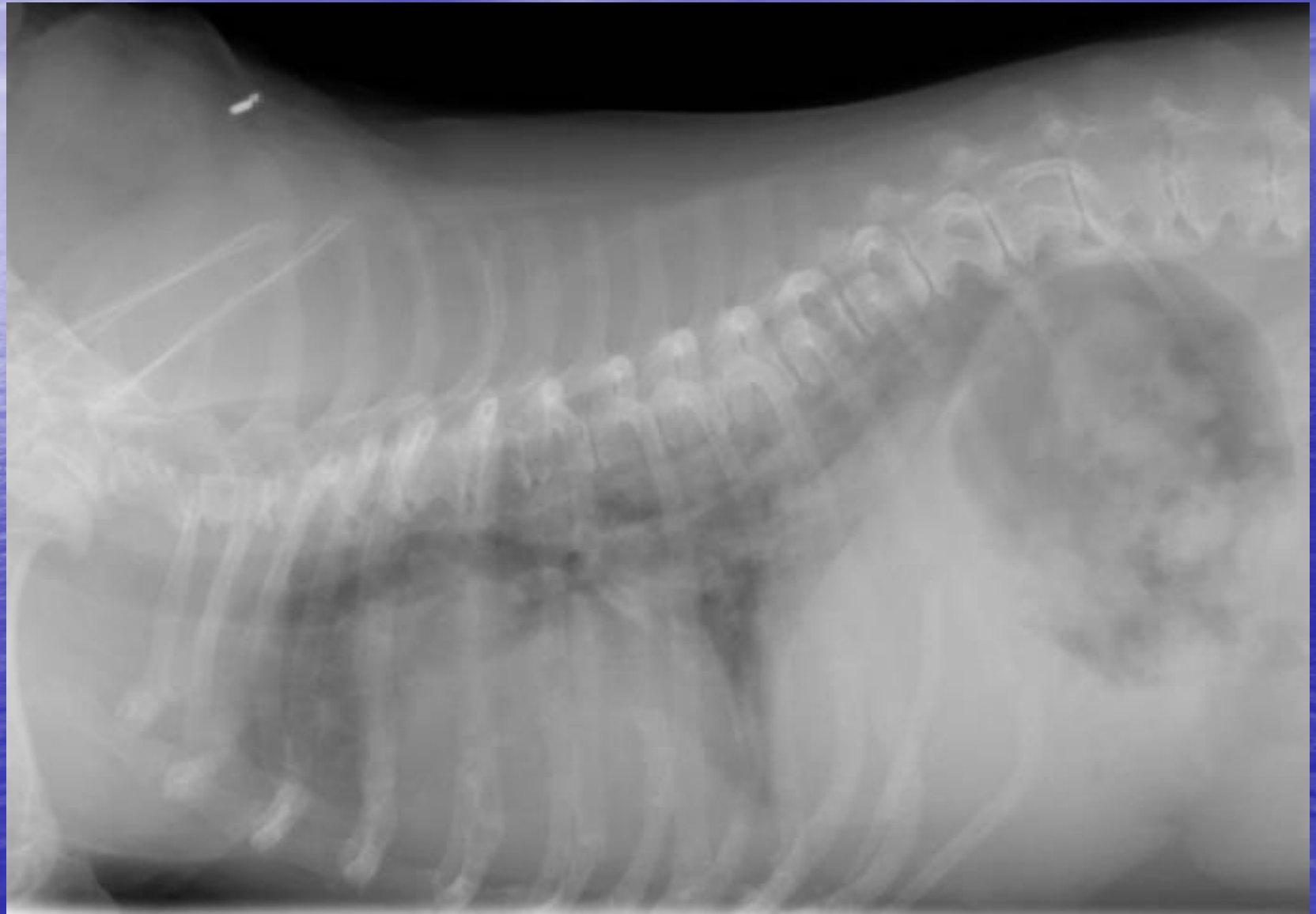R

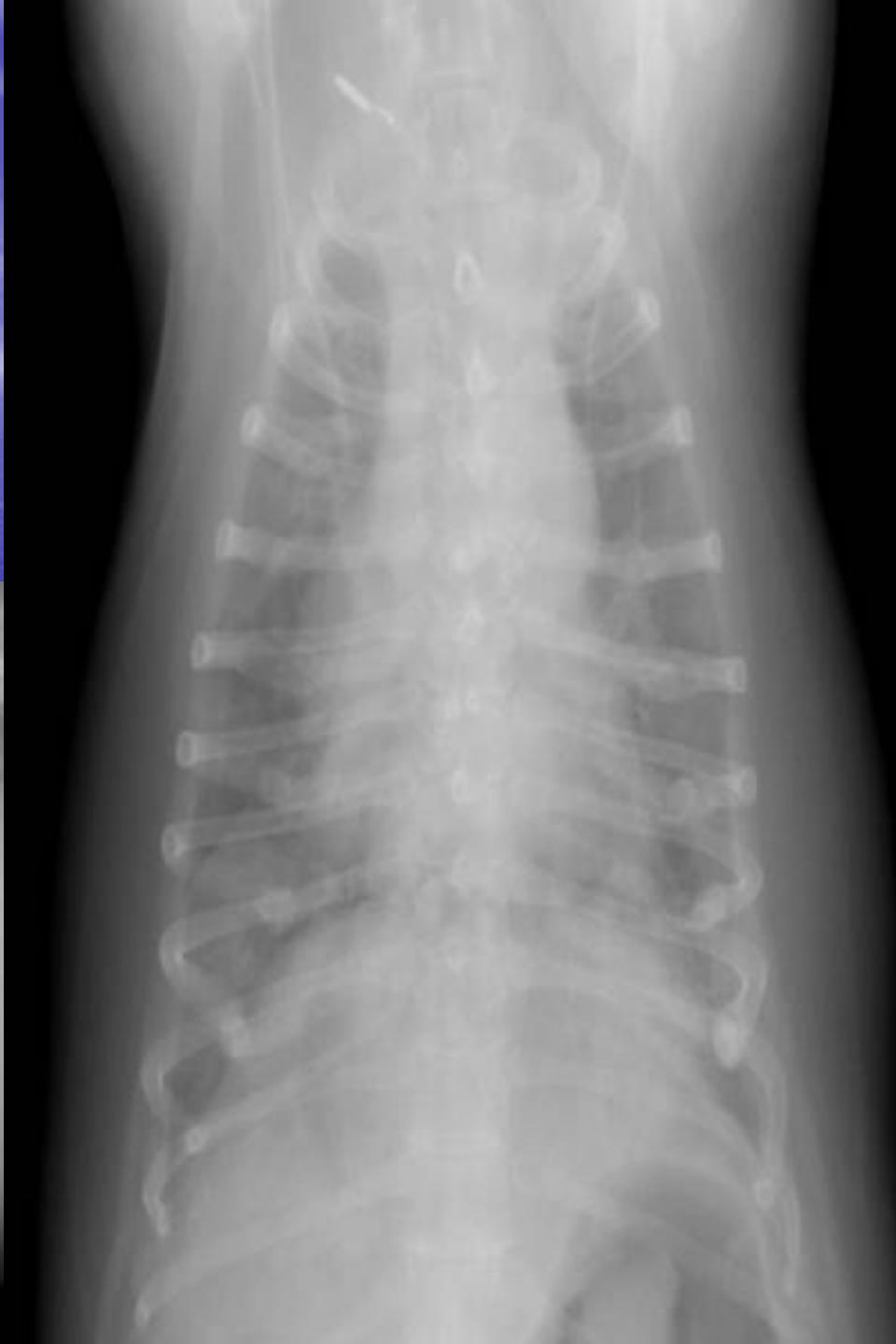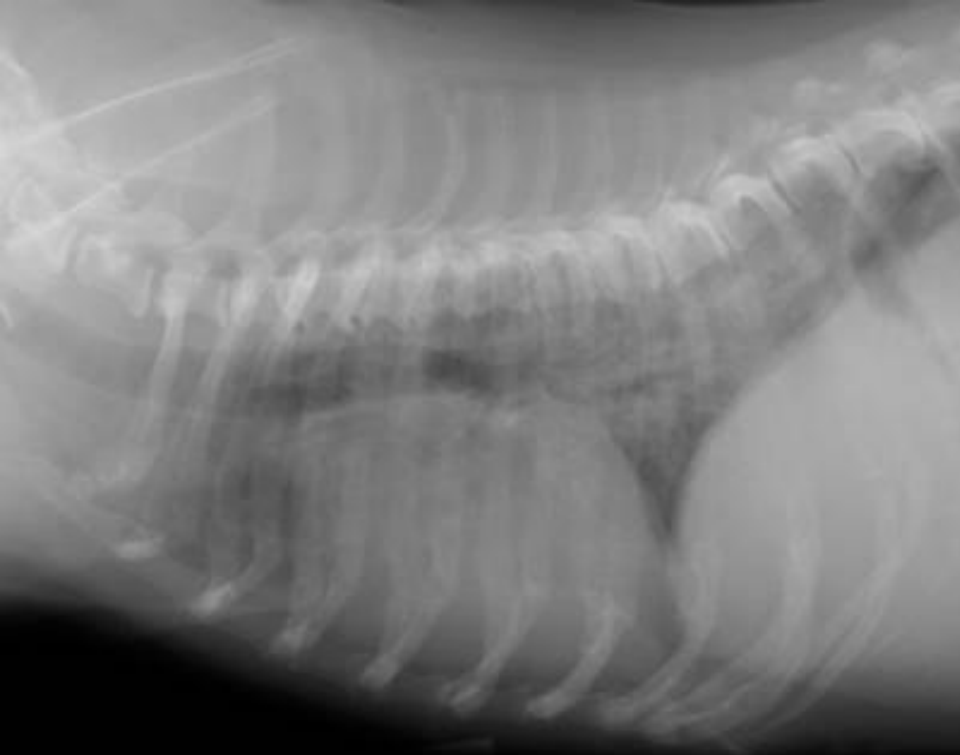DX

Belle – 10yr Lab

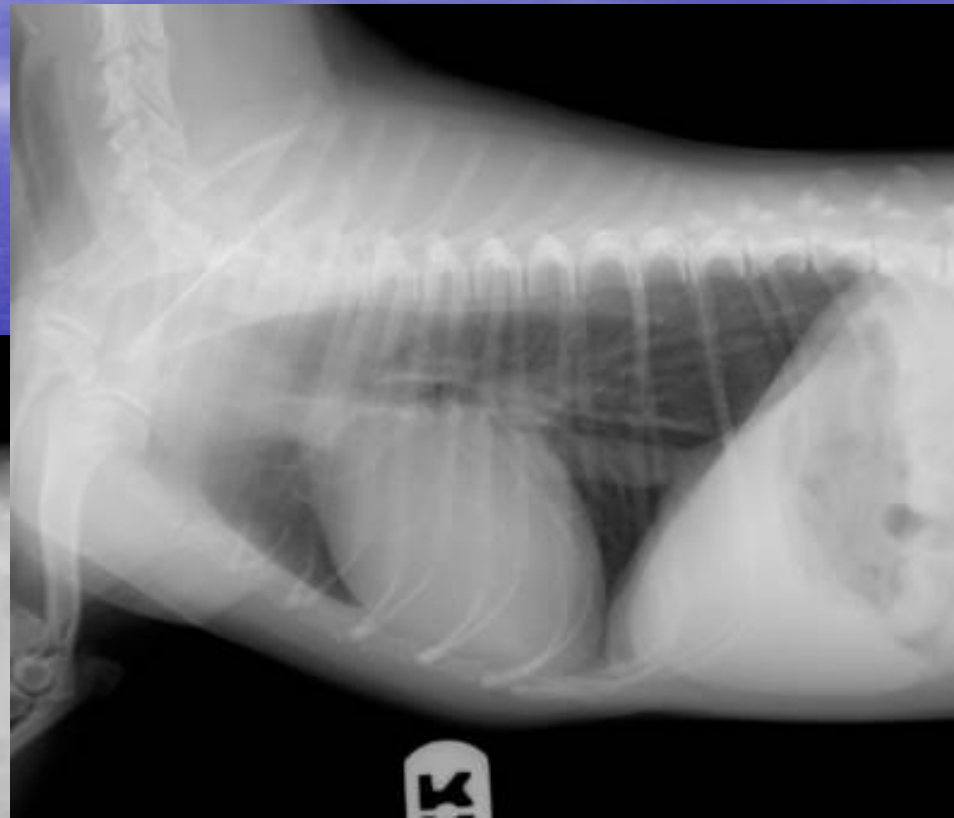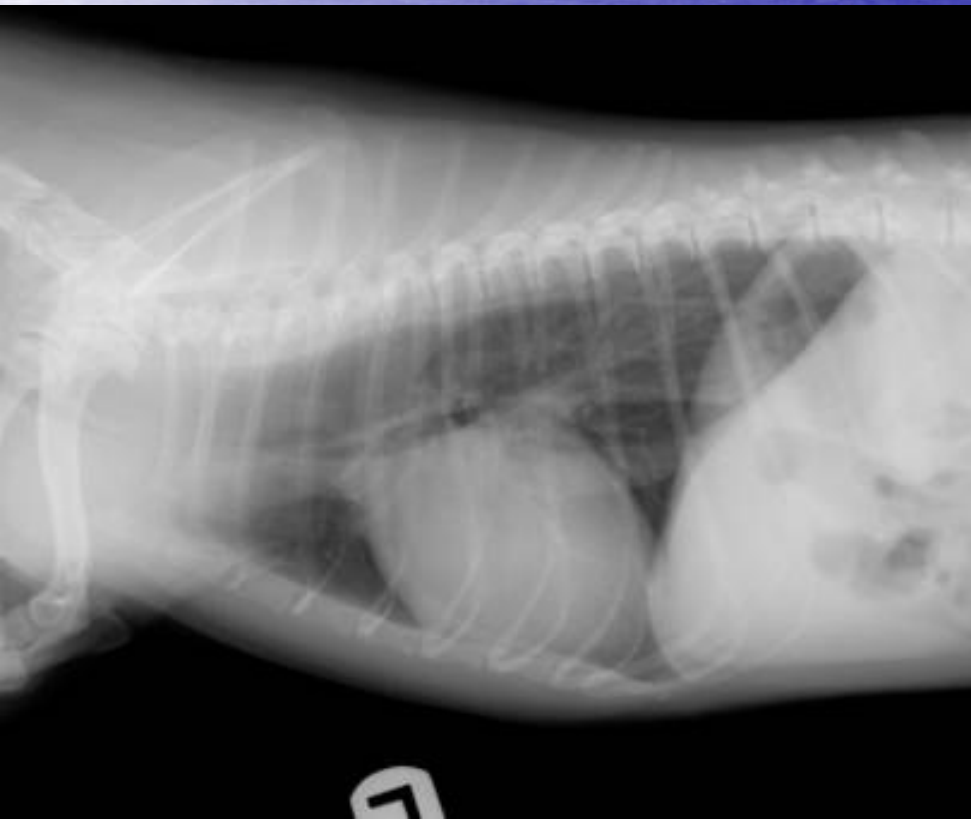


Molly – 15yr Bichon Frise

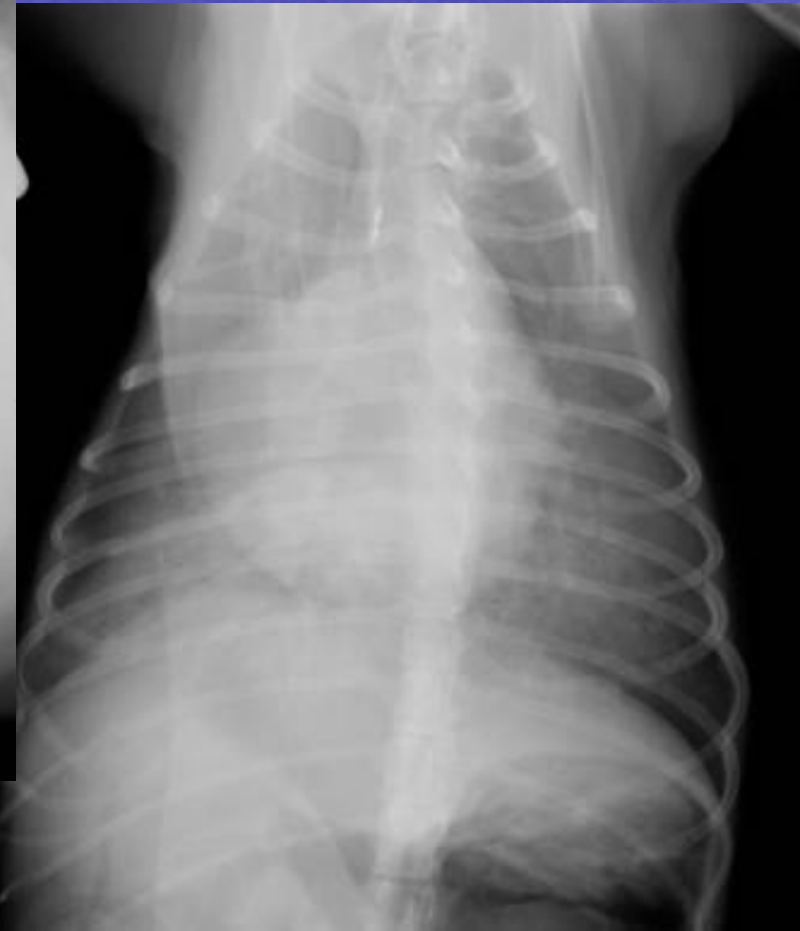
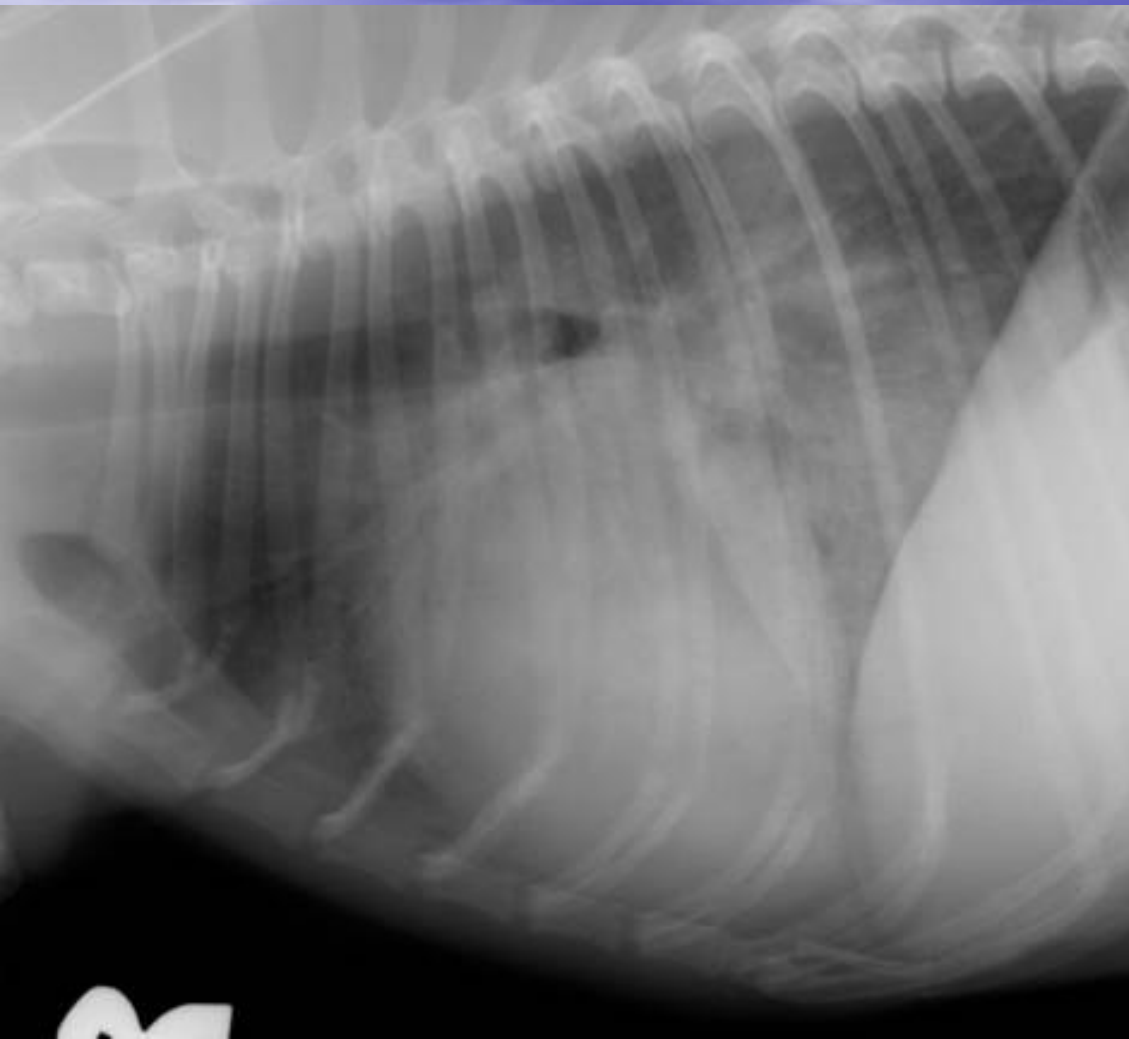


Bear – 14 yr Yorkie

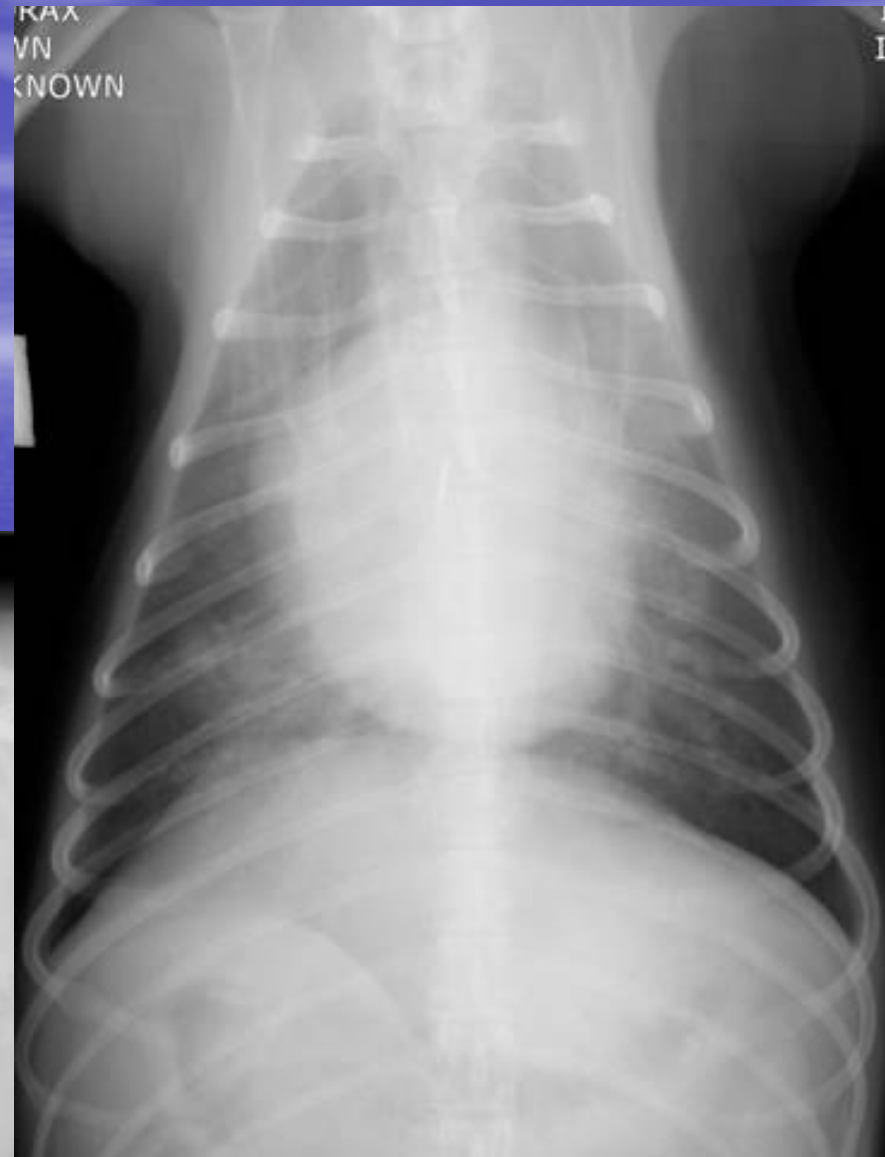

Heidi – 8 yr FS Shn

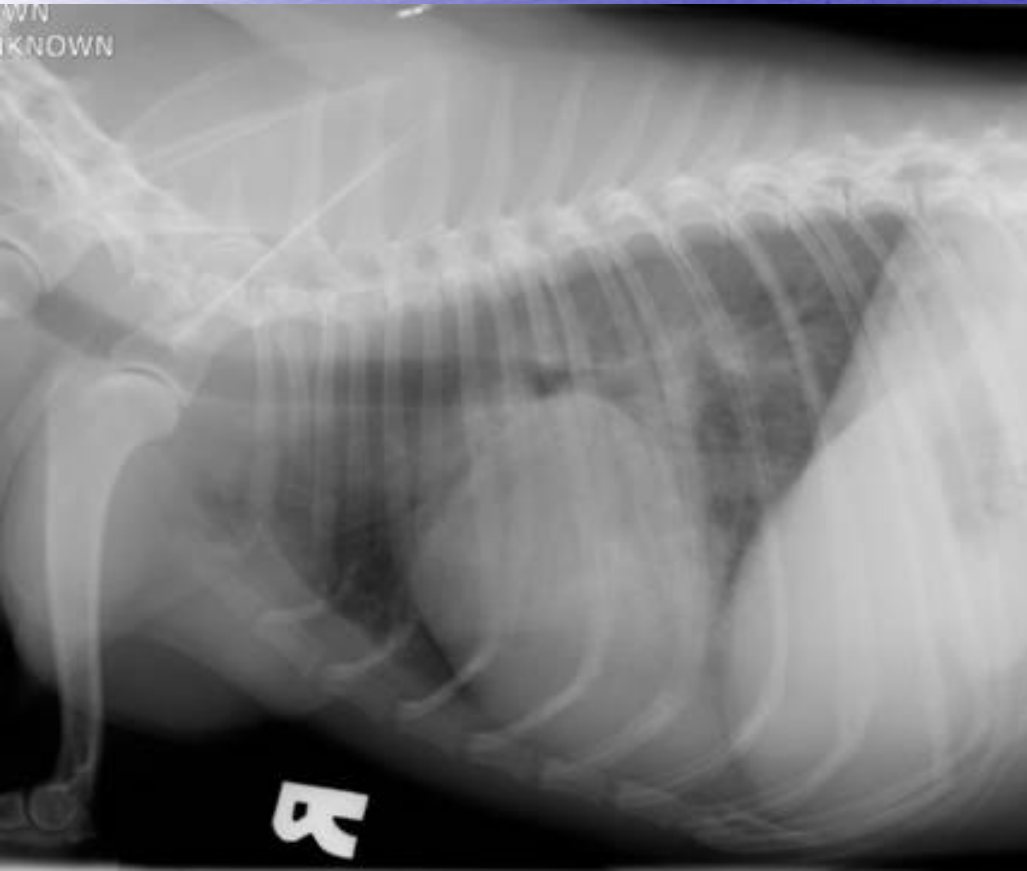


Fixed?

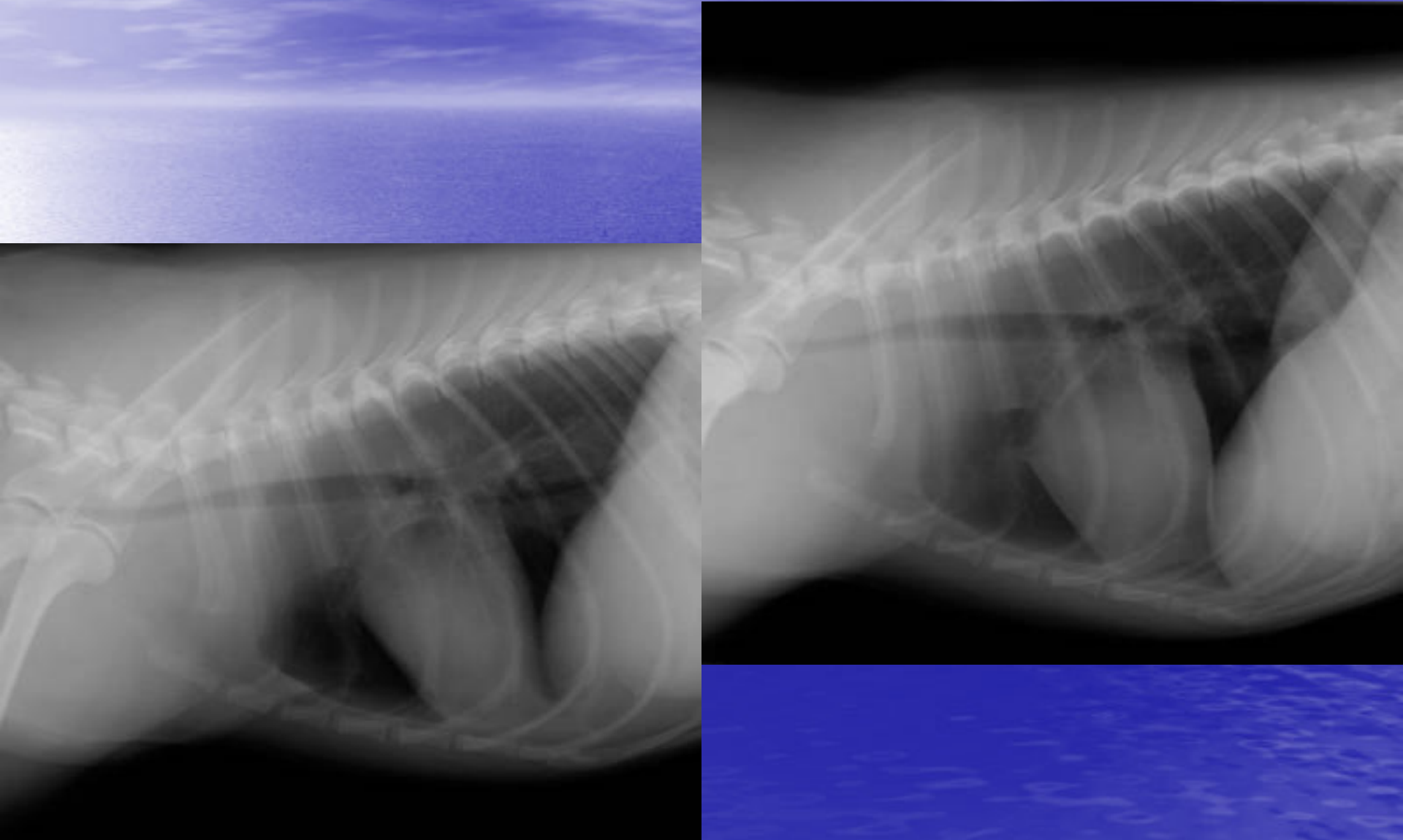
KAX
VN
KNOWN

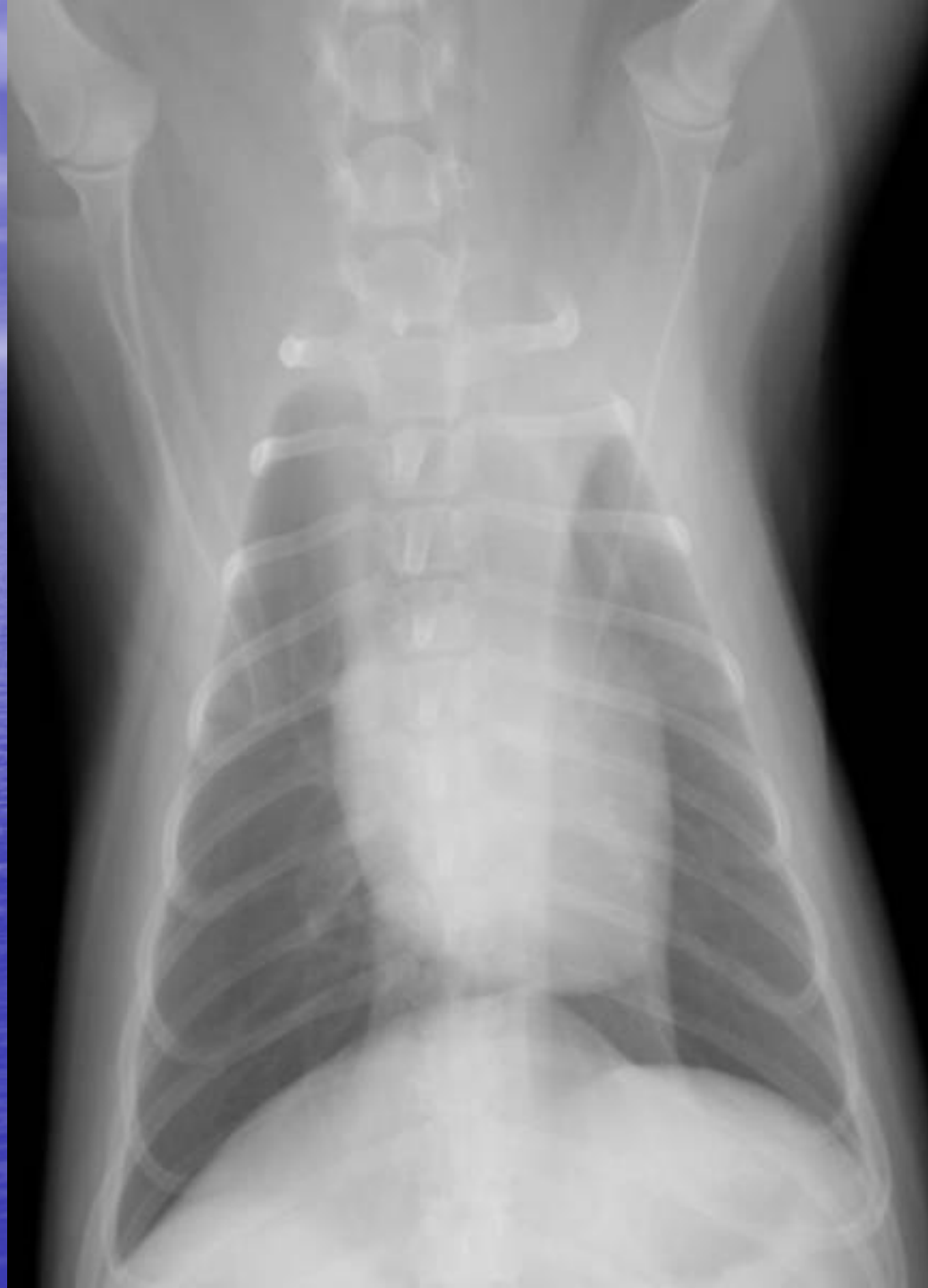

WN
KNOWN

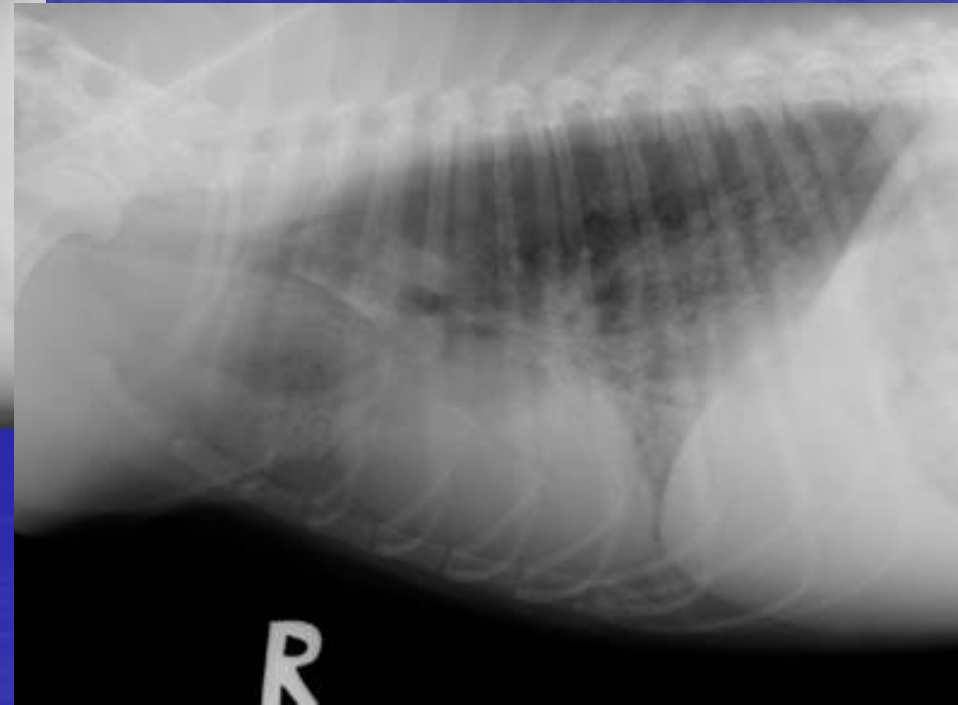
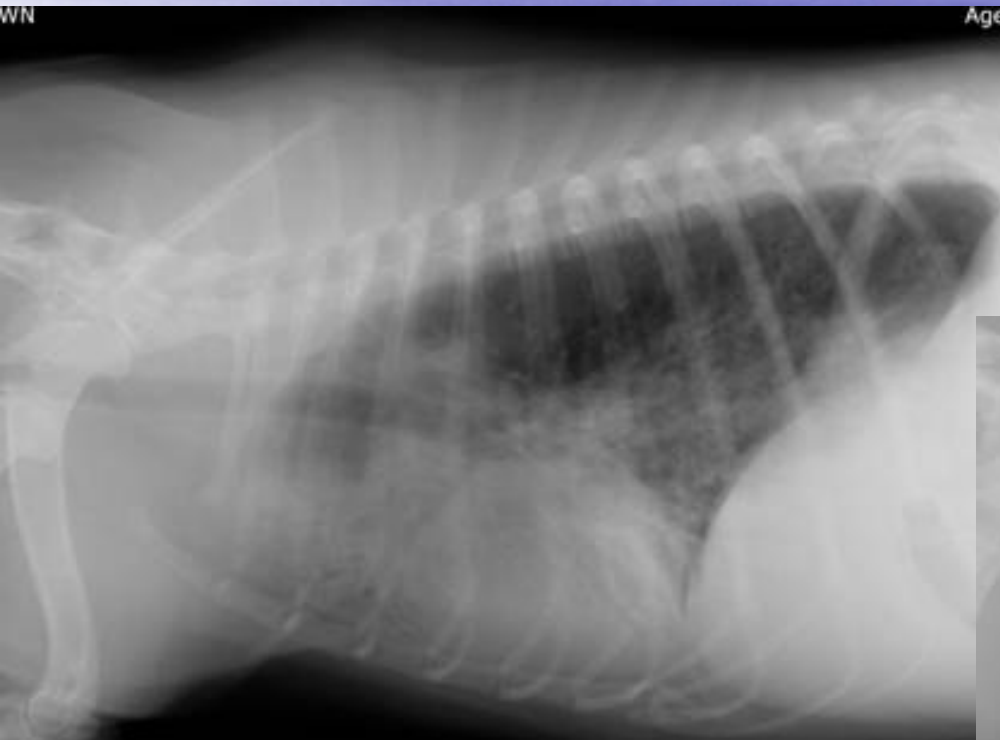

Tiki – 11 yr Pom

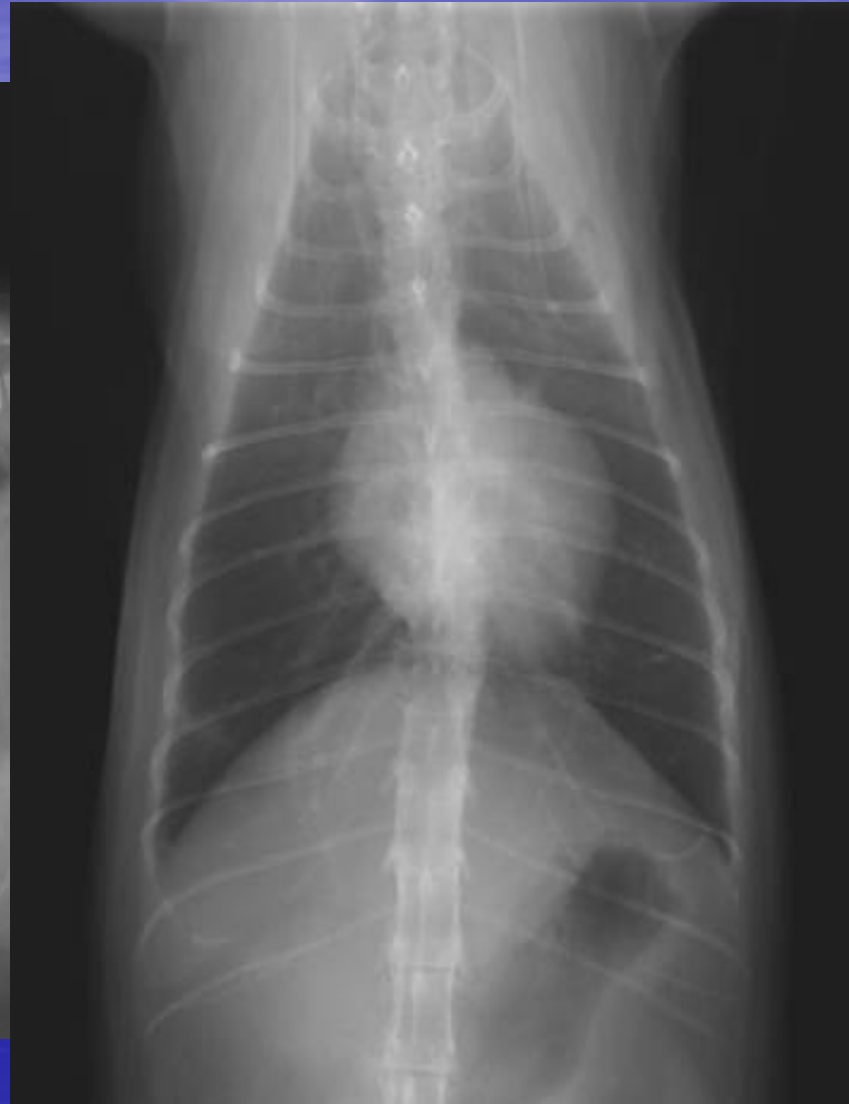
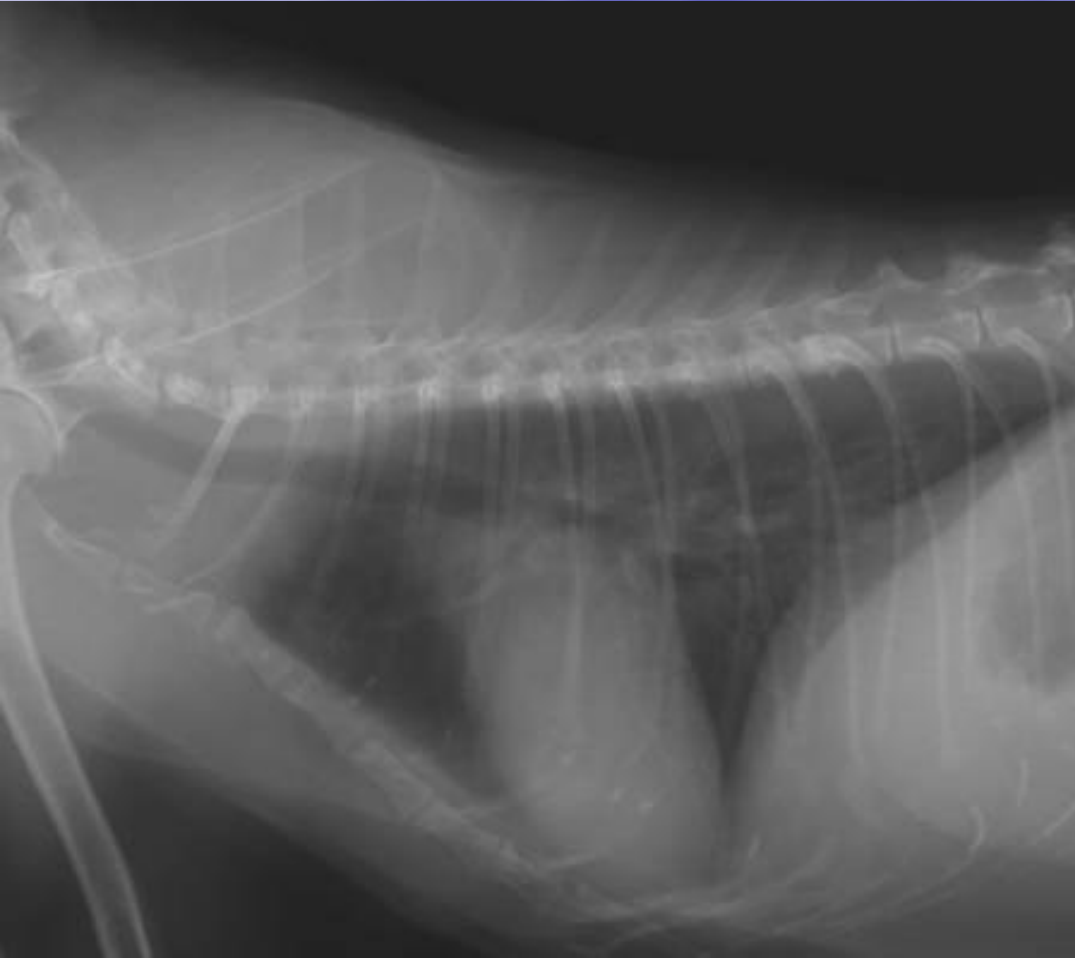


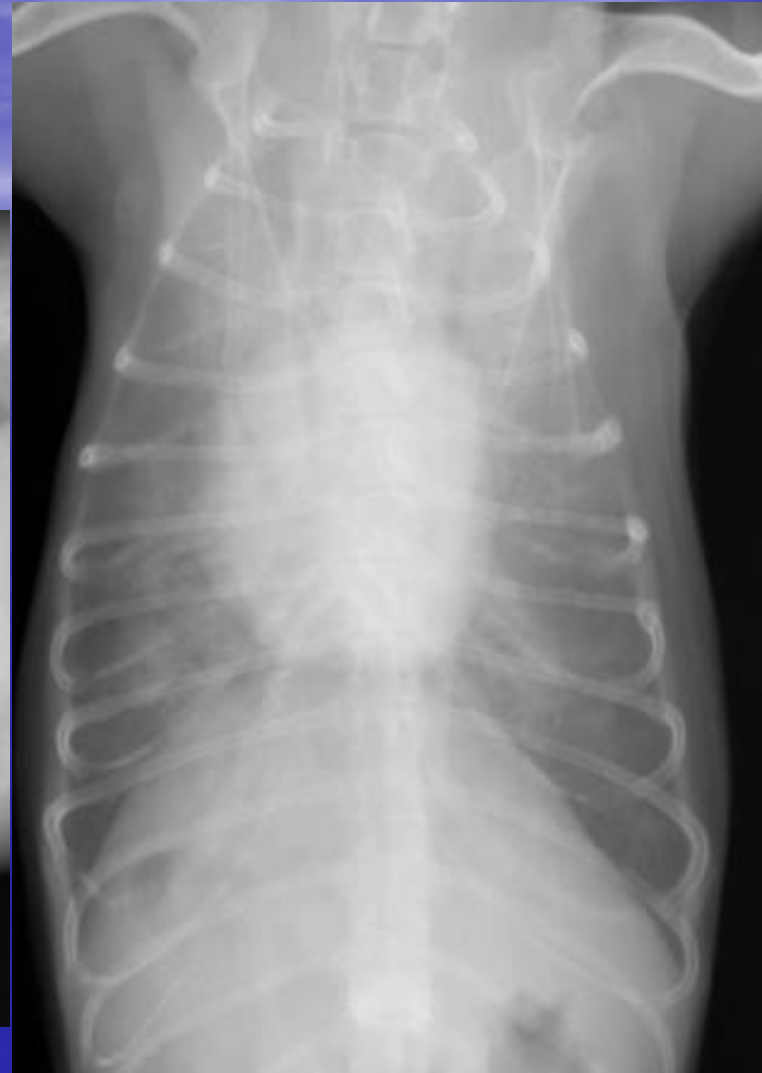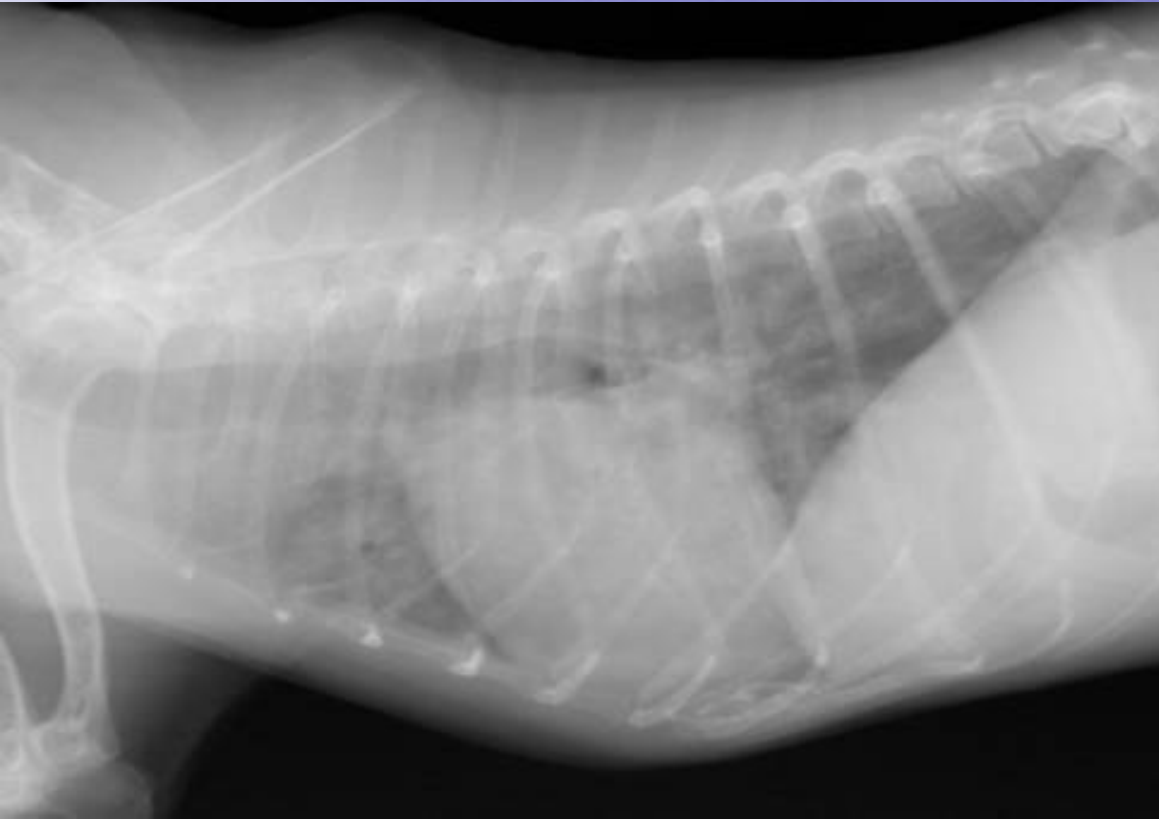Orion – 18 mo Cocker



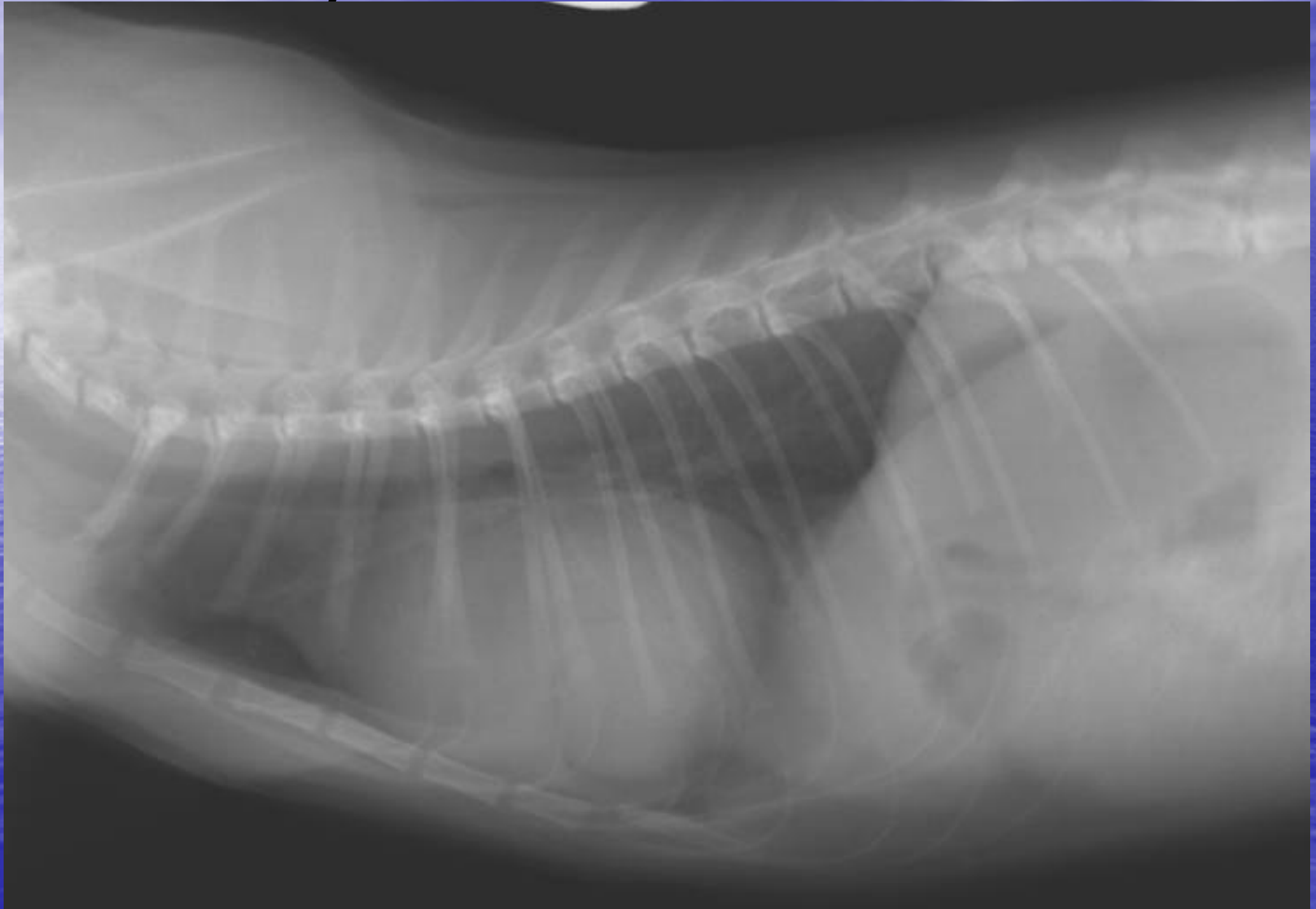Hermie – 18 yr Himalayan

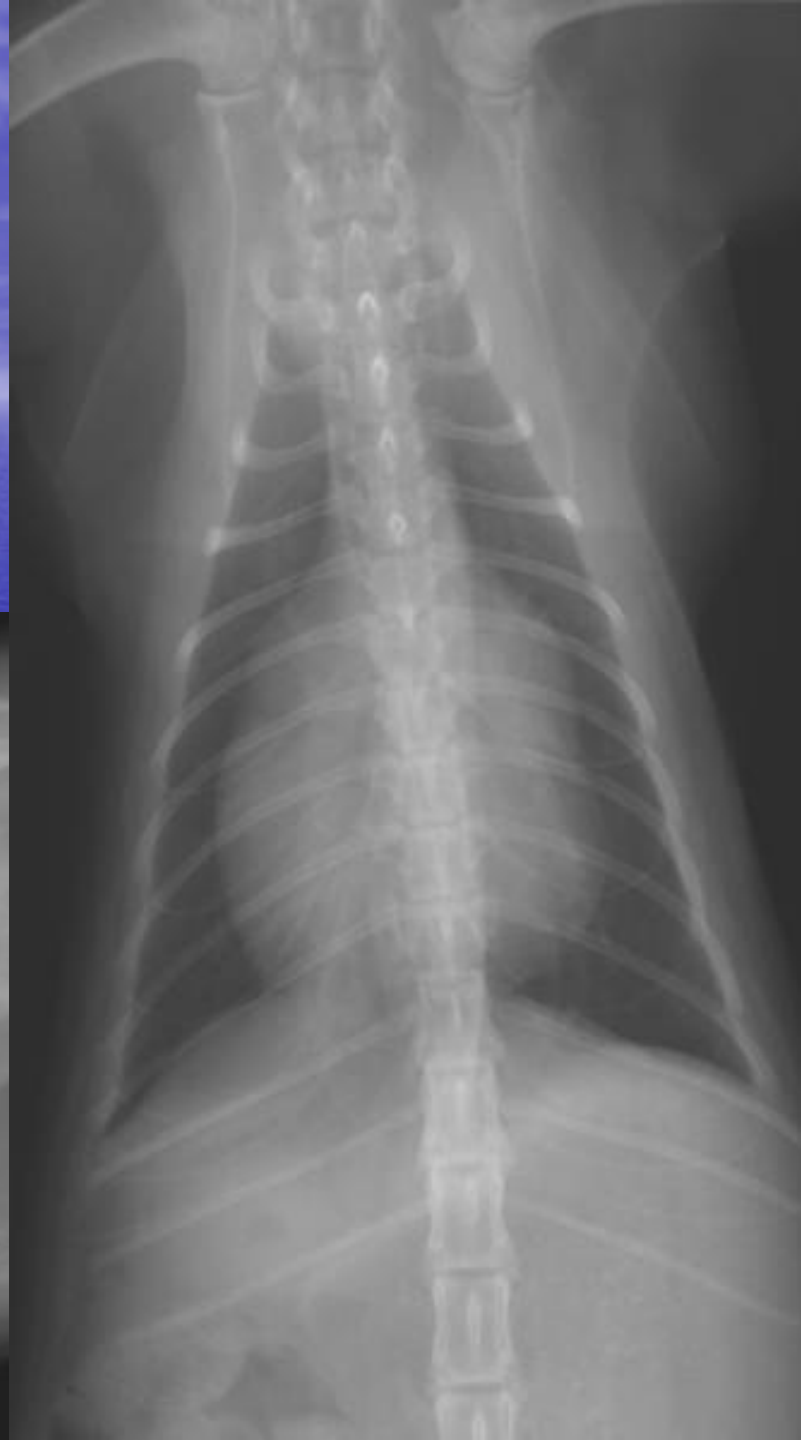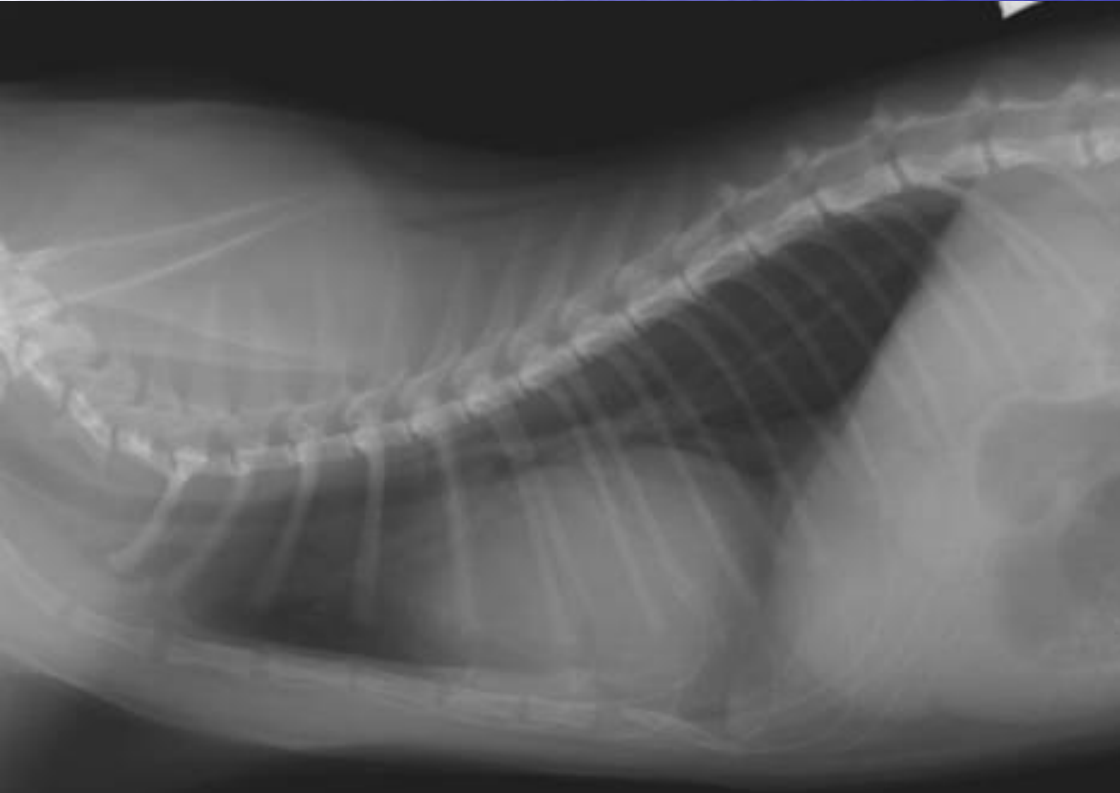


Lady – 13yr Poodle

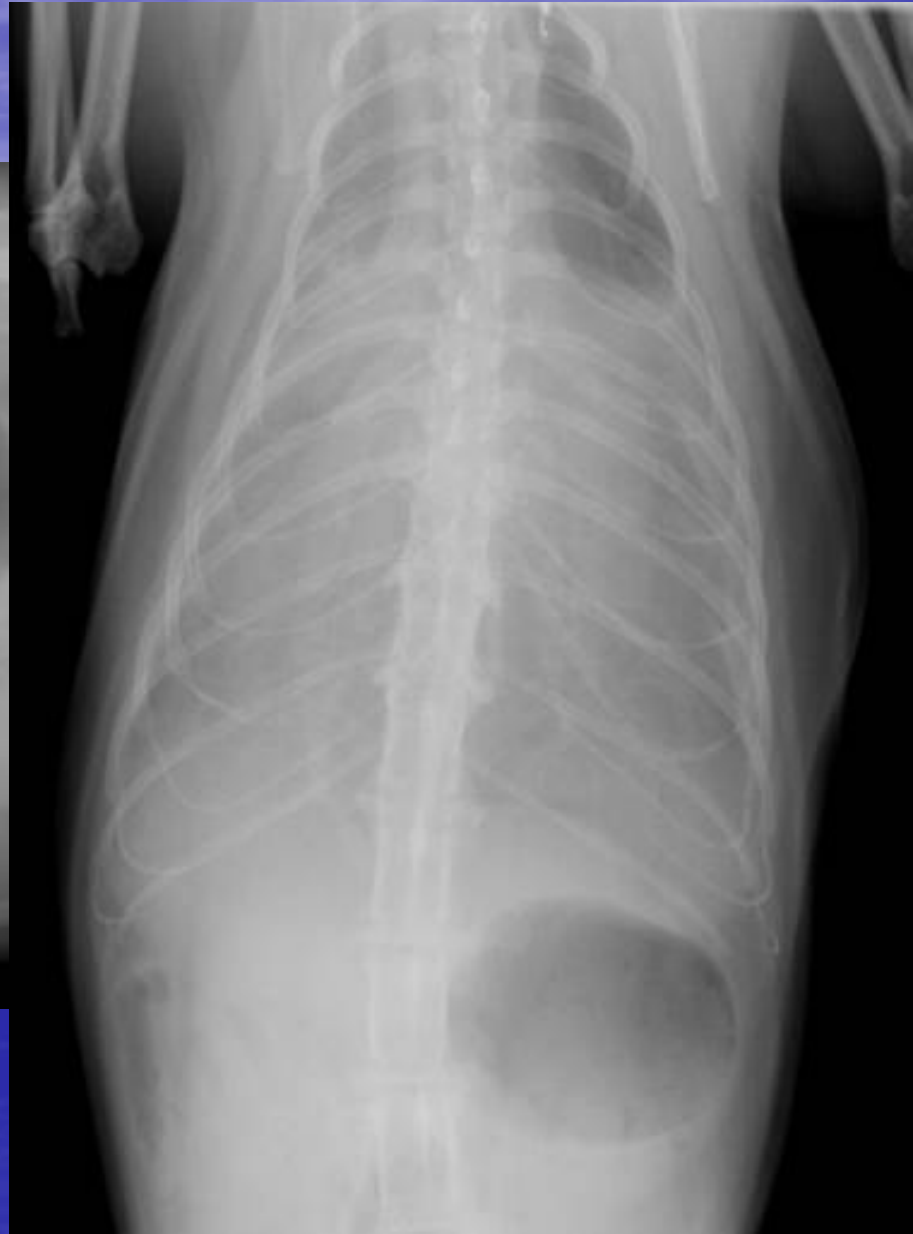
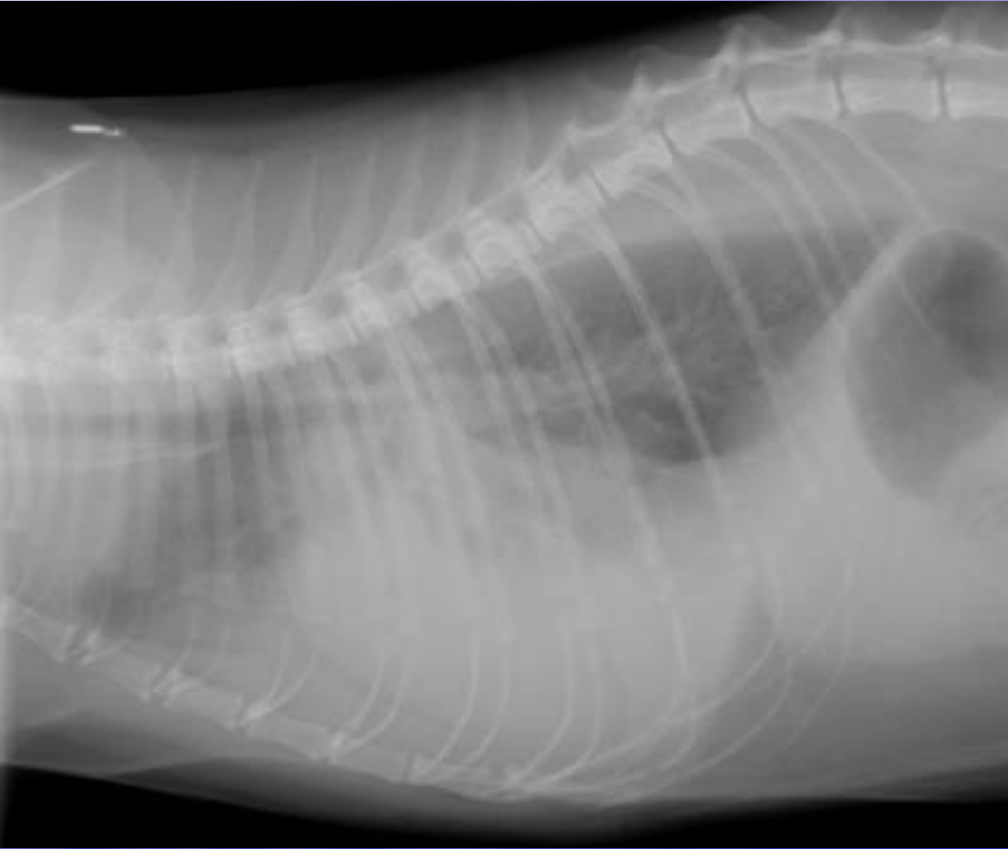
Lily – 11 month Persian

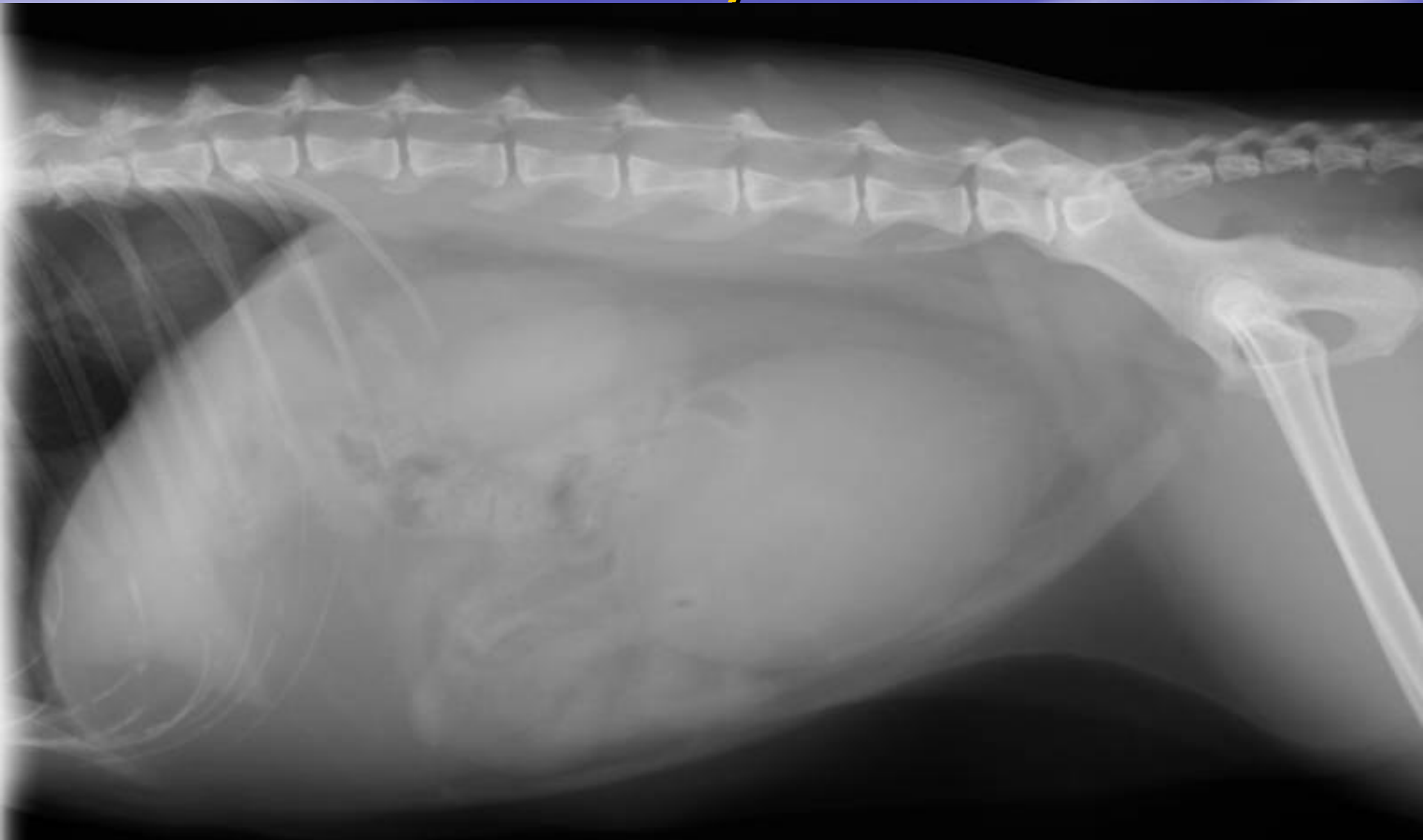



Sammy – 7 yr DMH



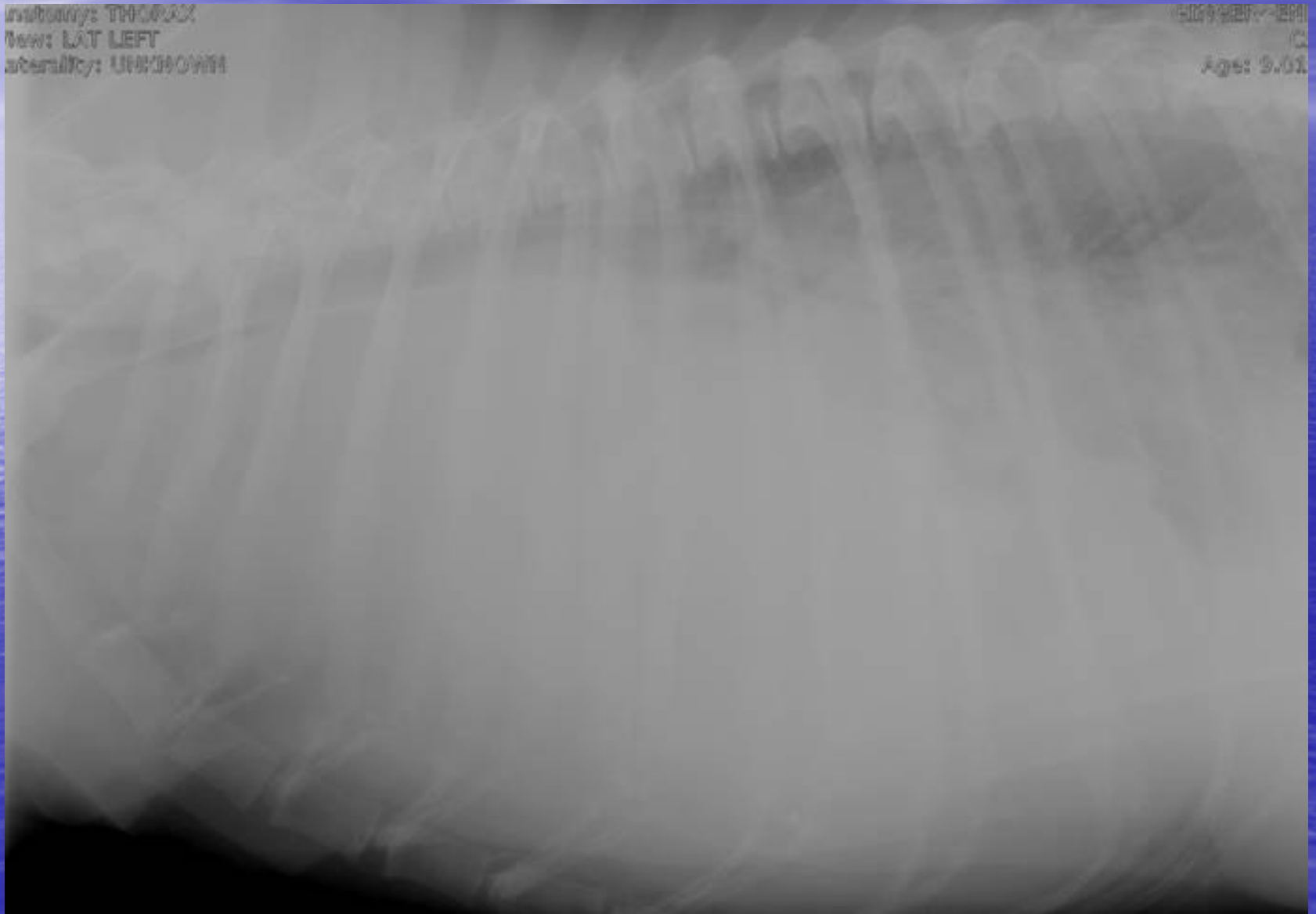Scout – 10 yr DSH MN



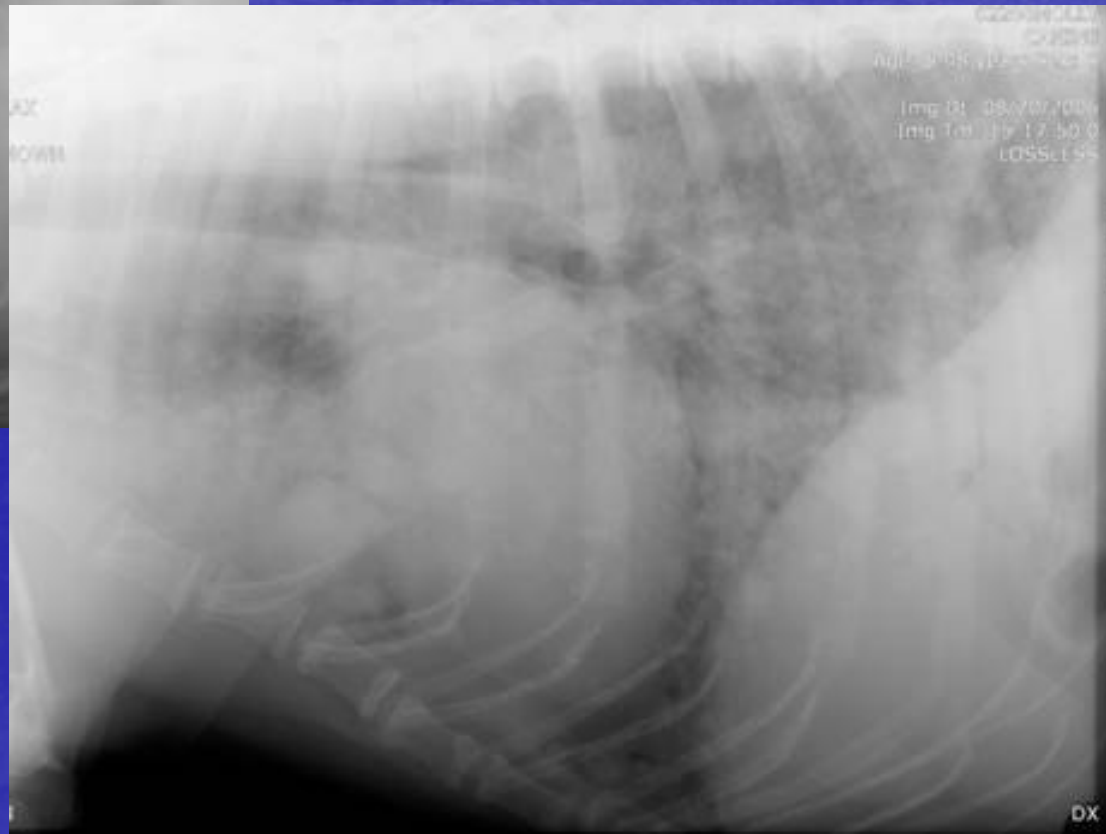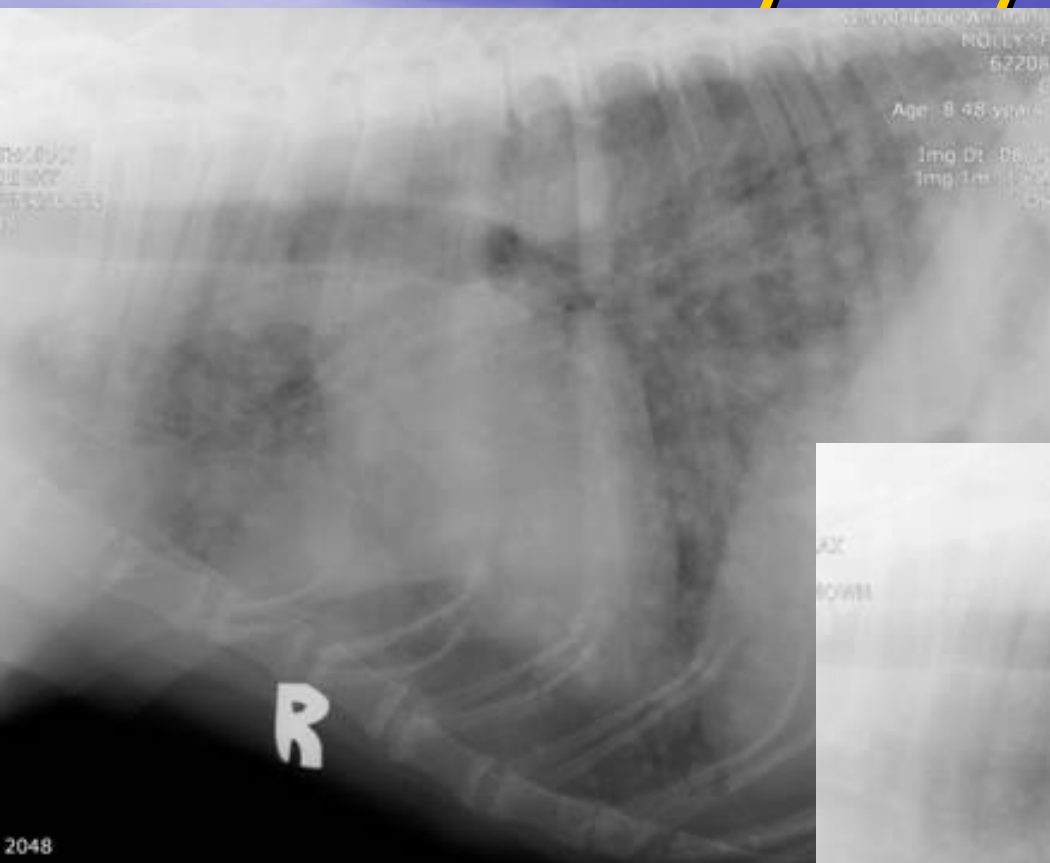
Ginger – 9 yr Lab

anatomy: THORAX
View: LAT LEFT
laterality: UNKNOWN

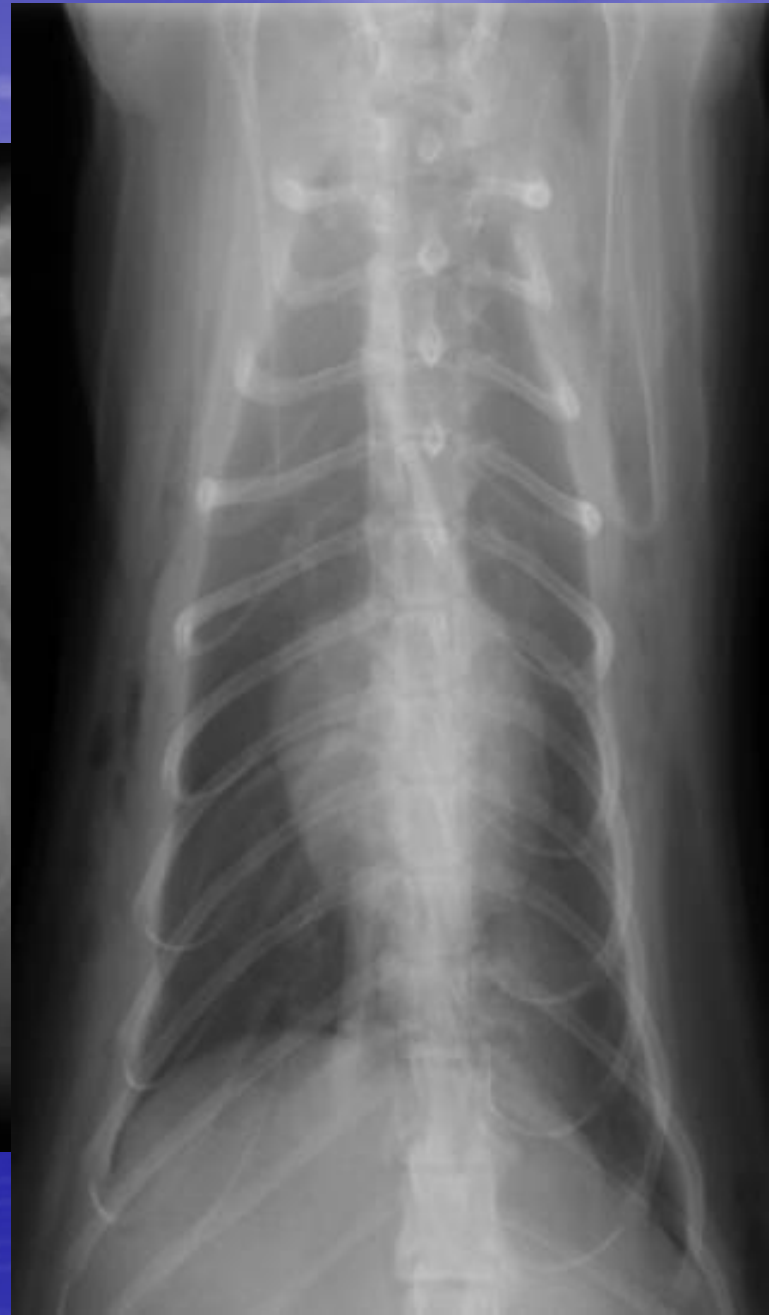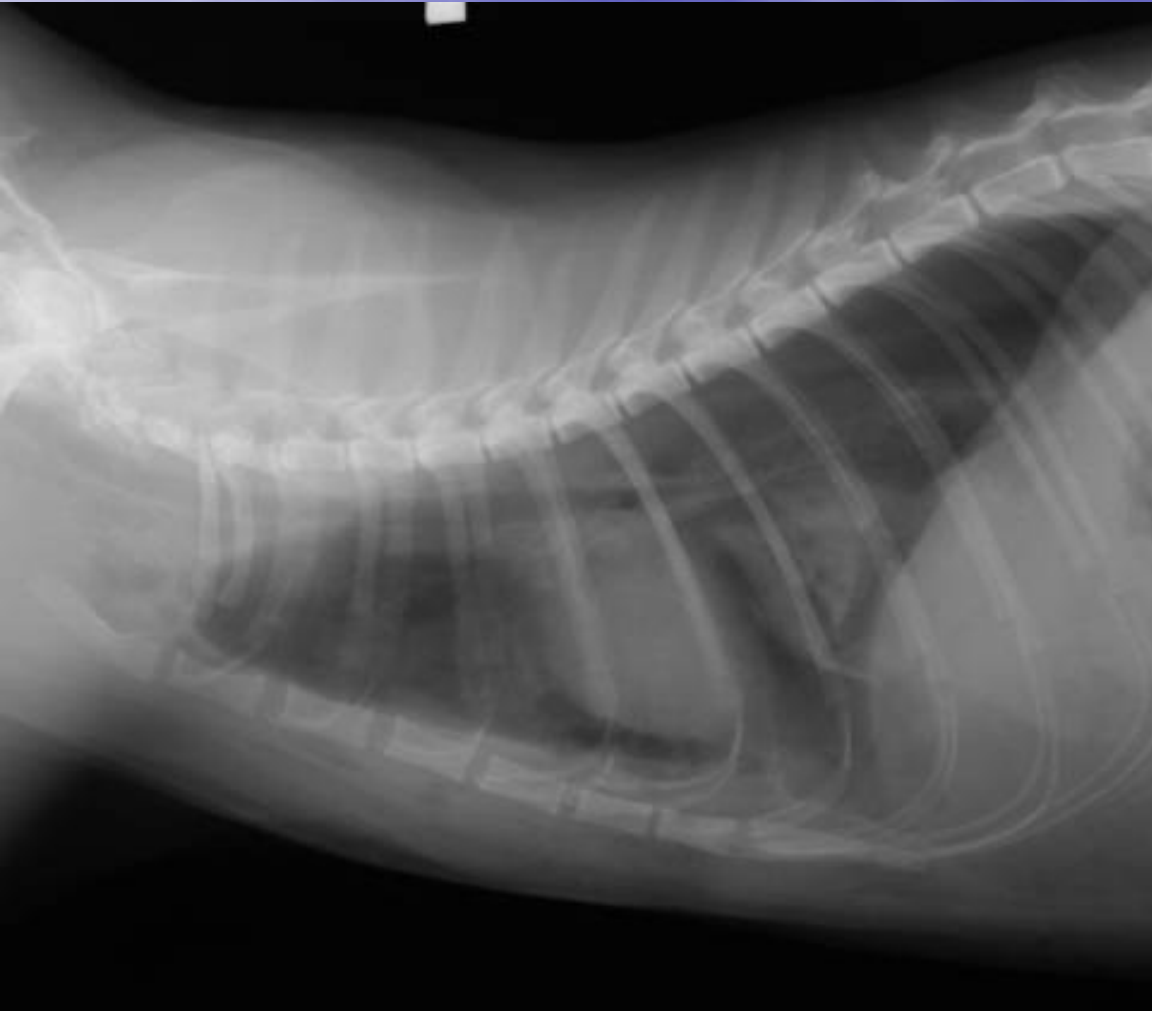PATIENT: EMU
C
Age: 9.01

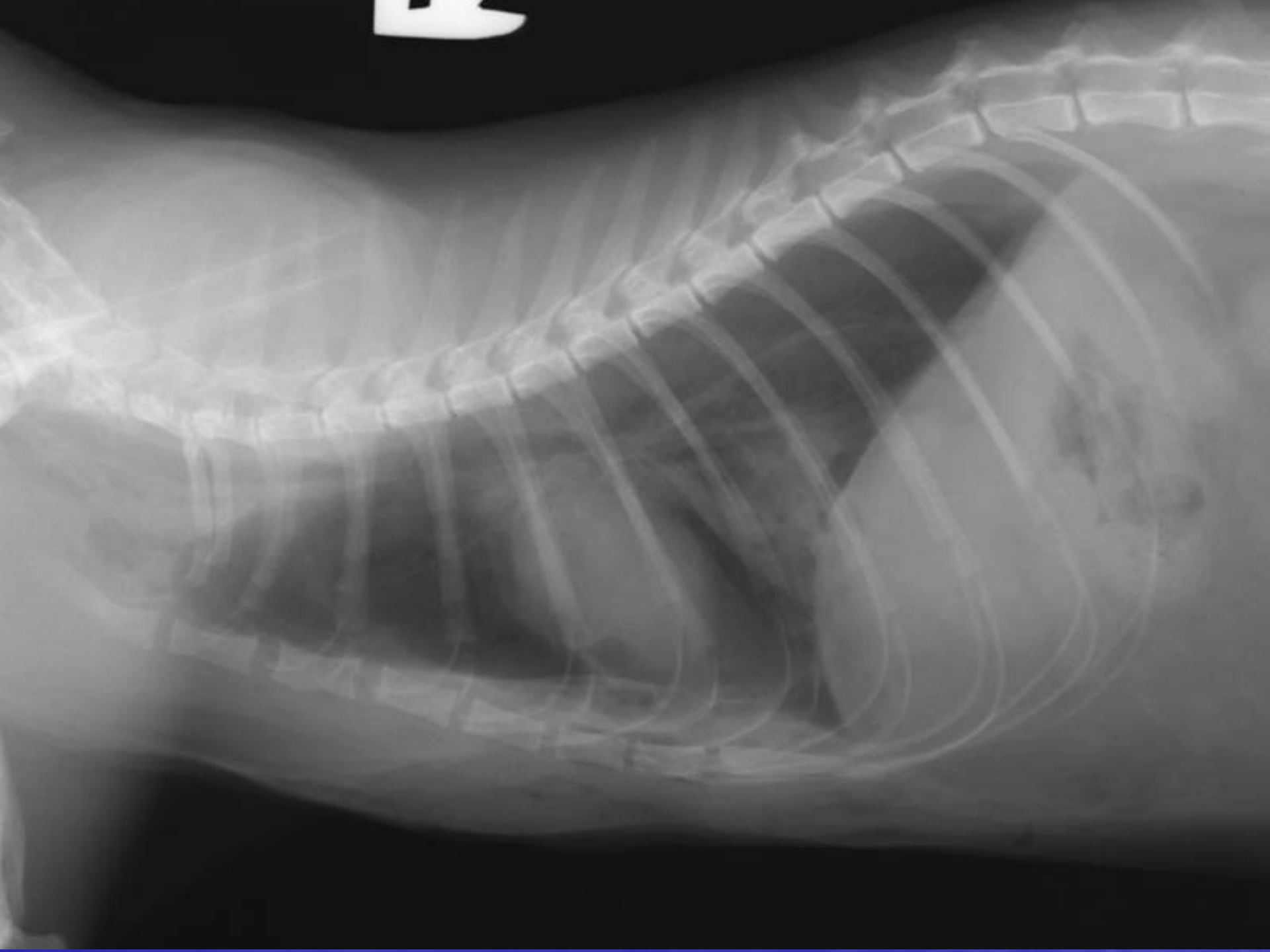

Molly – 8yr Germ

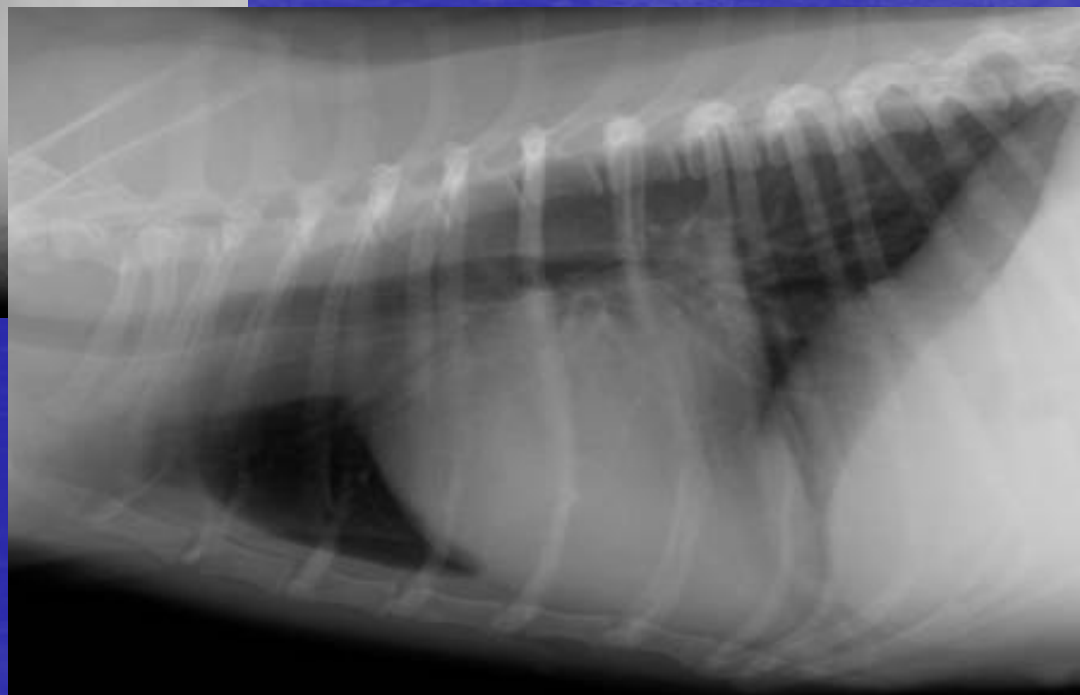
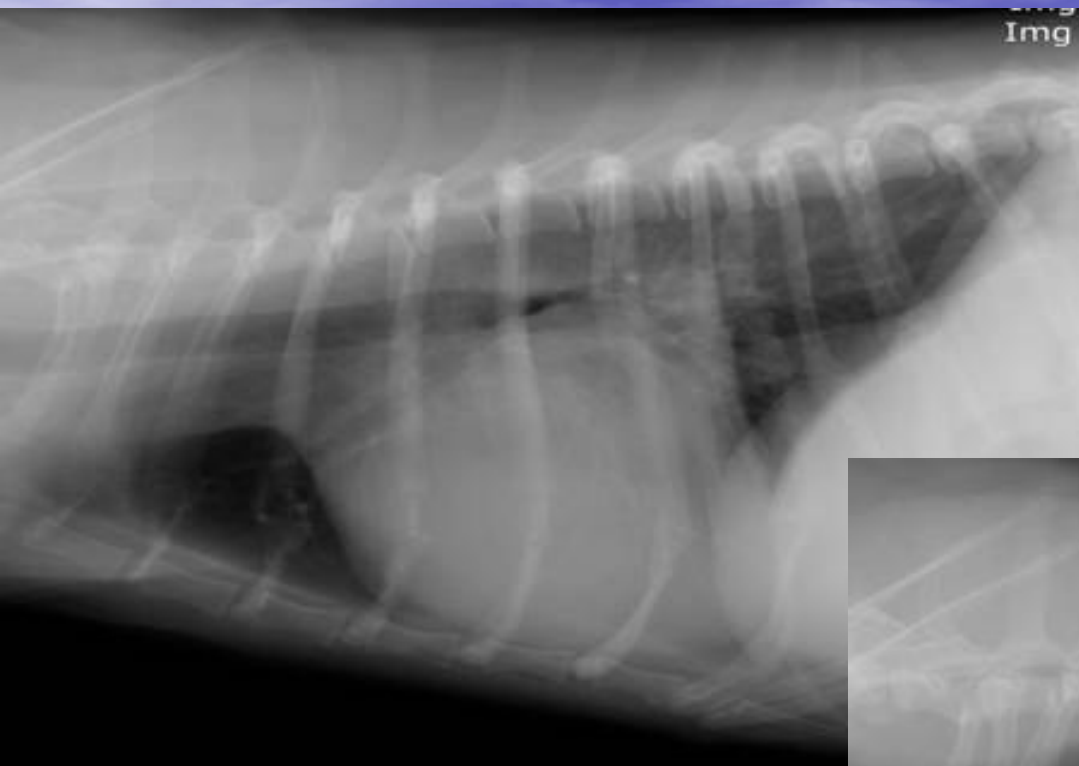
Eva – 14 m DSH



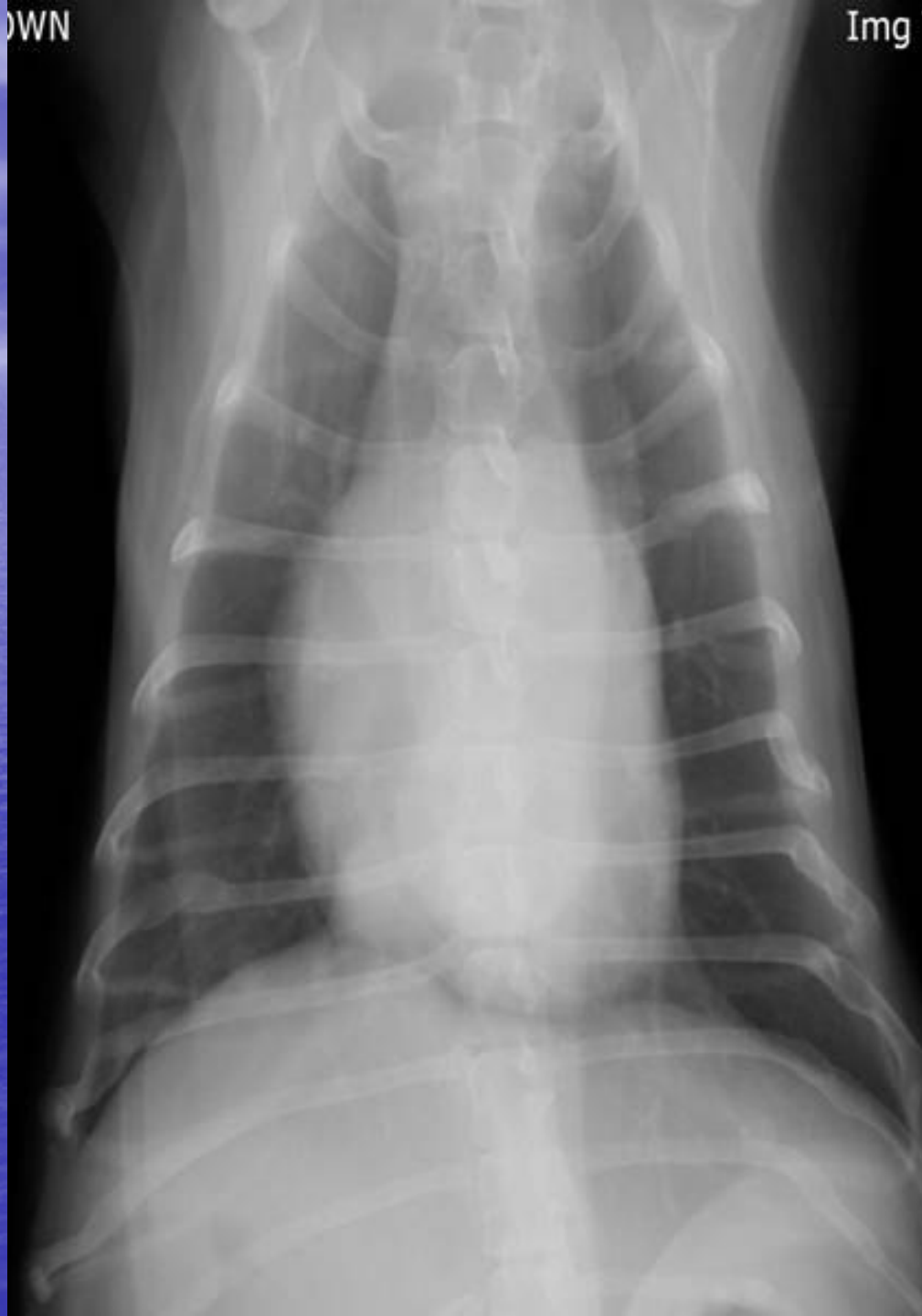

Pheobe – 11 yr Shih Tzu

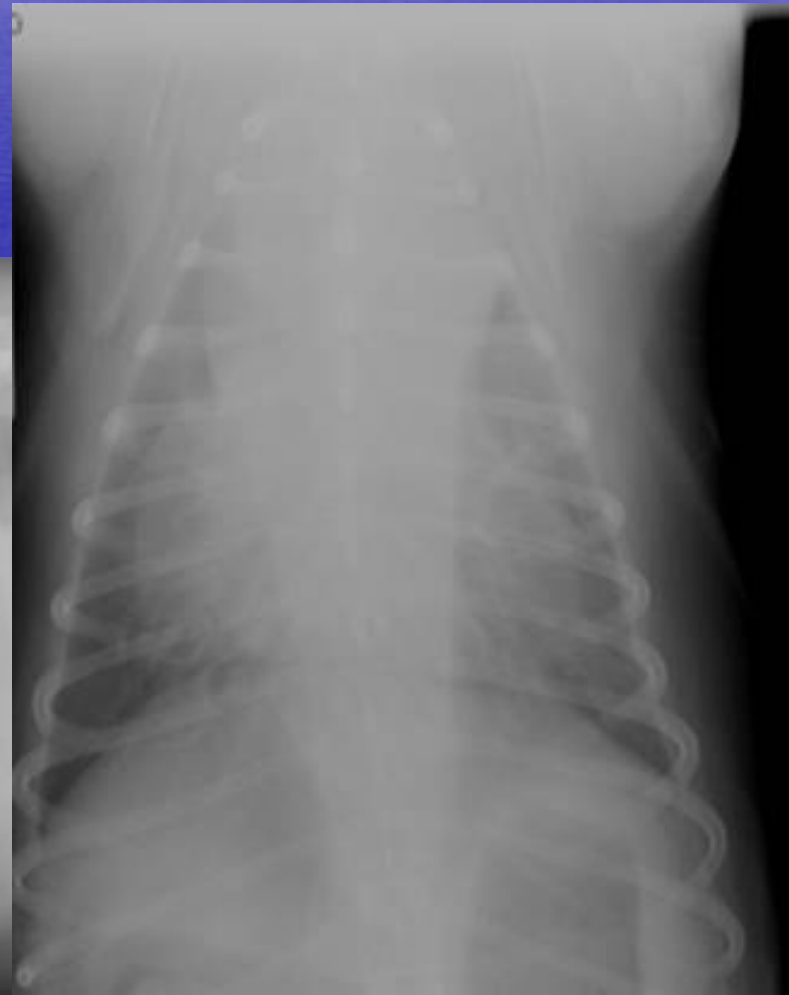
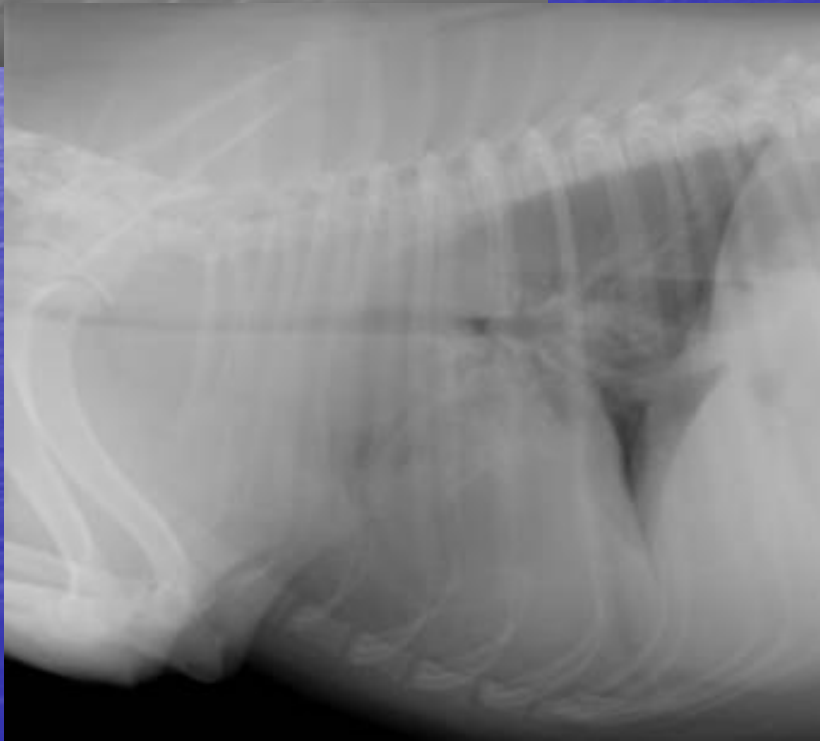
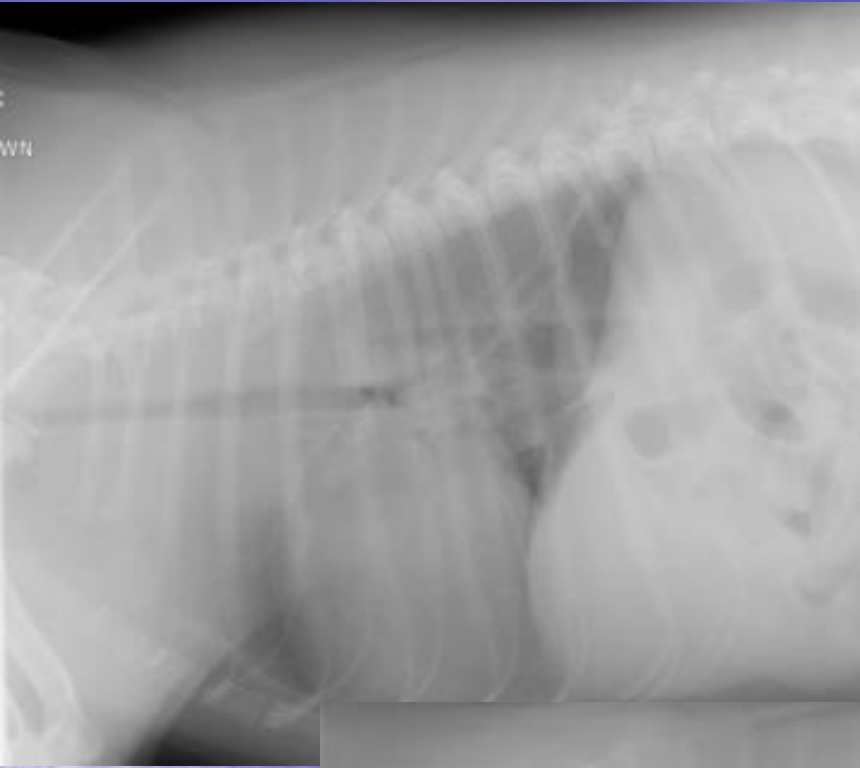DOWN

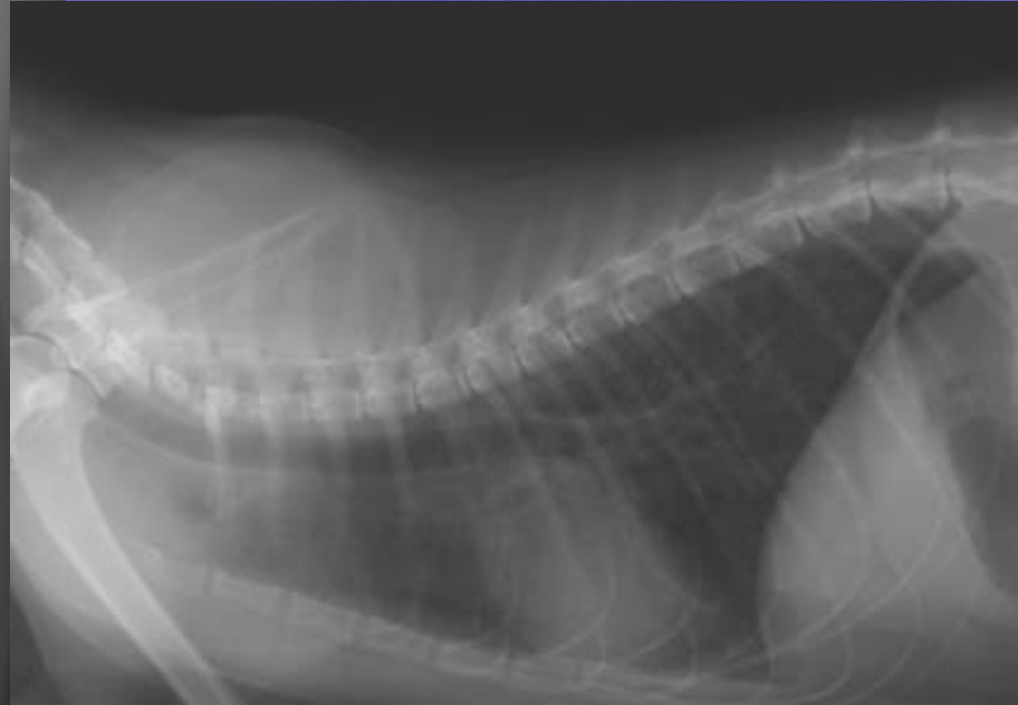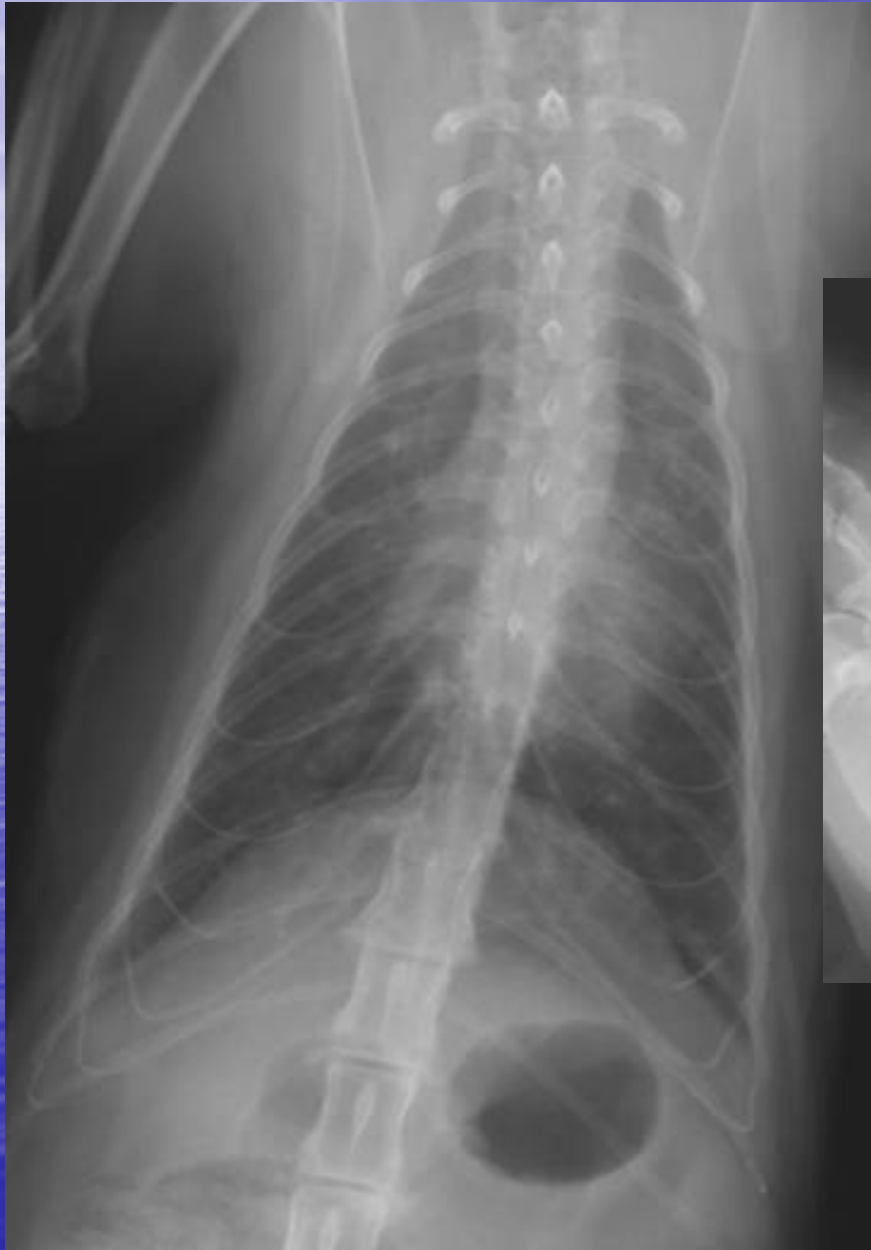
Img 1

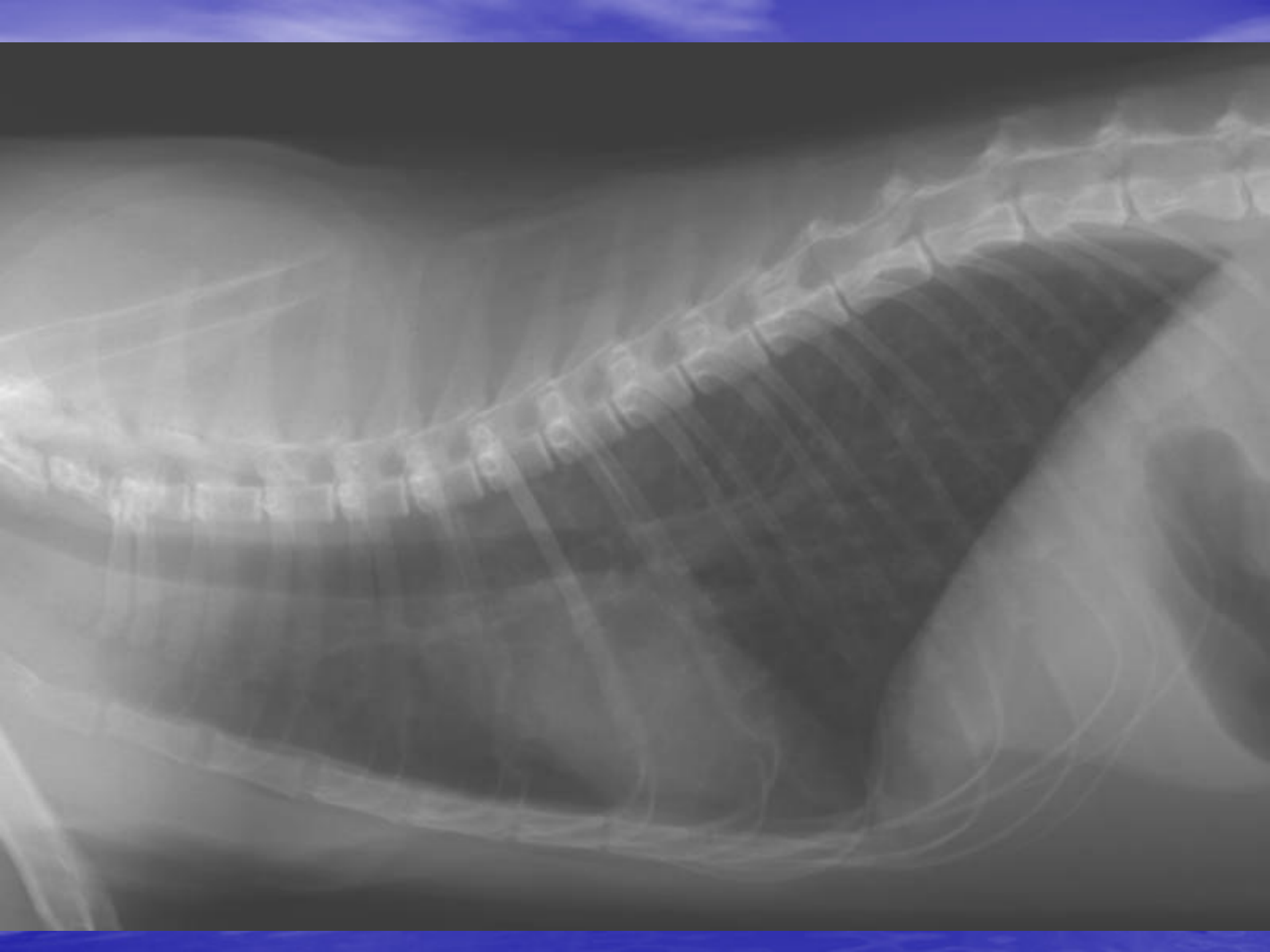


Bailey – 2 yr Beagle

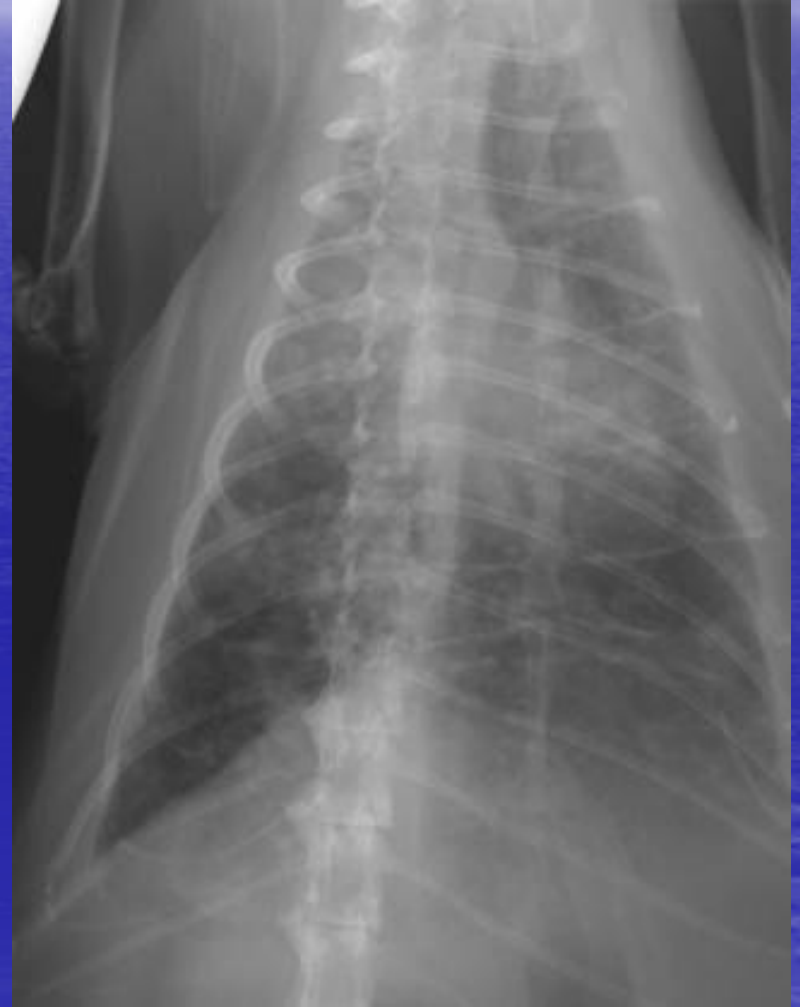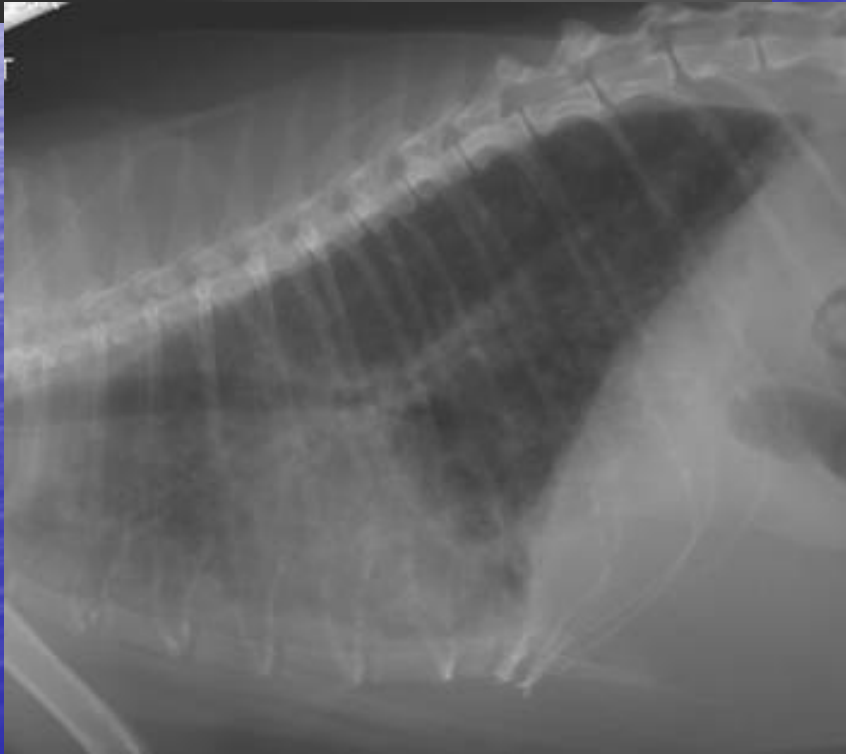

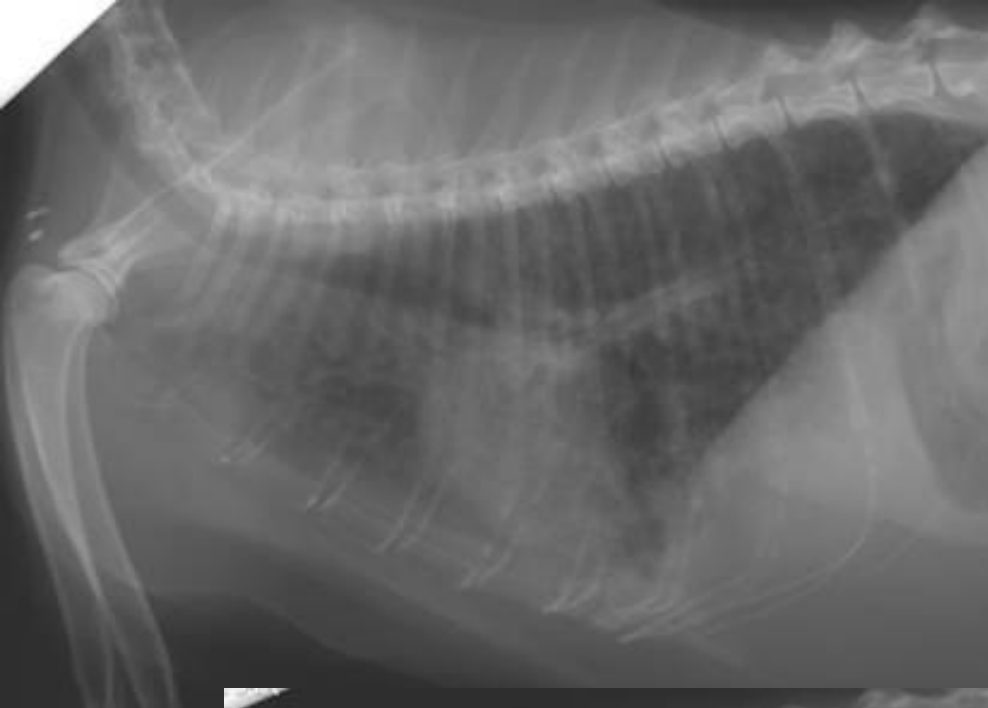
Smokey – 2 yr DLH

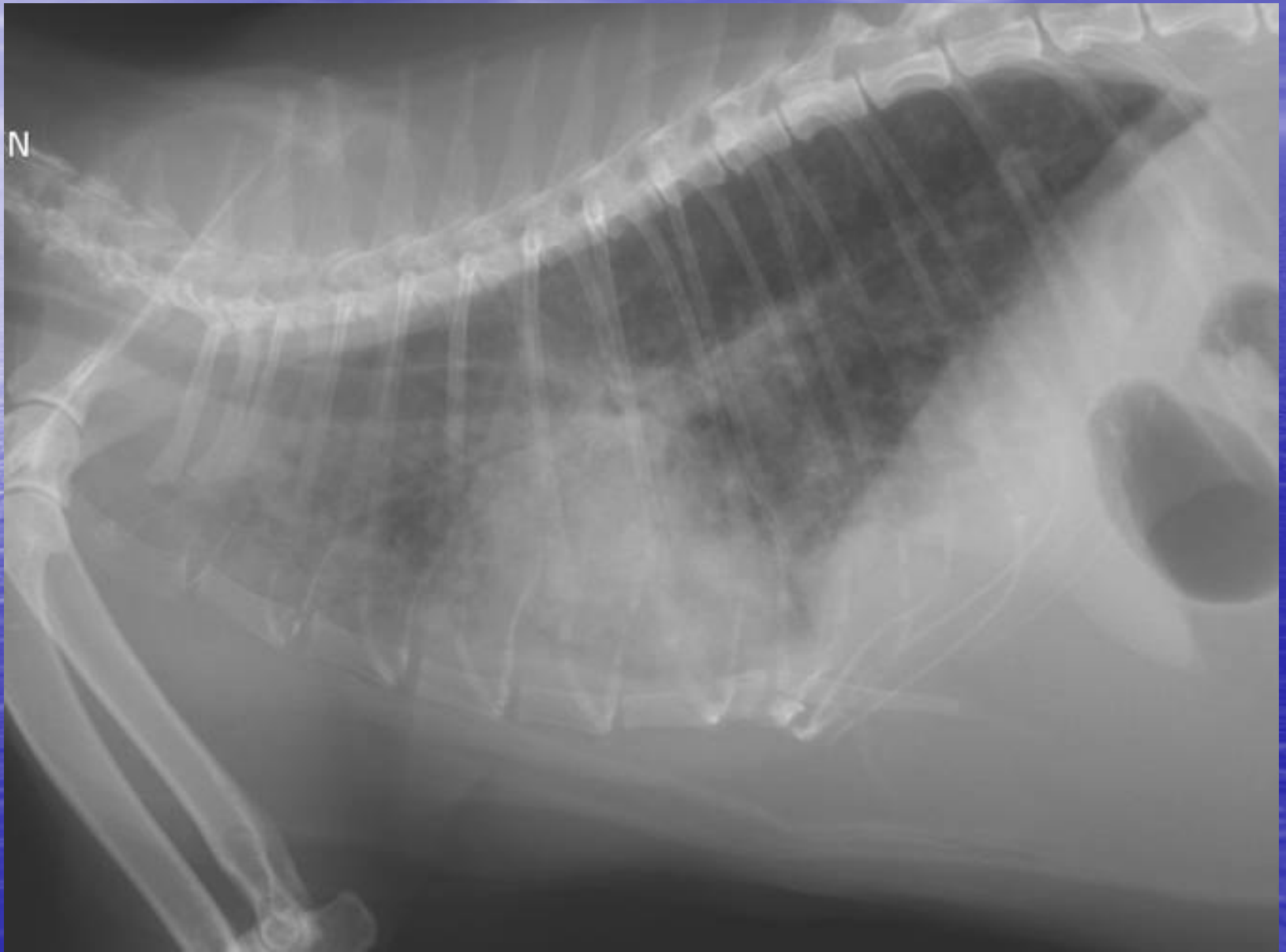


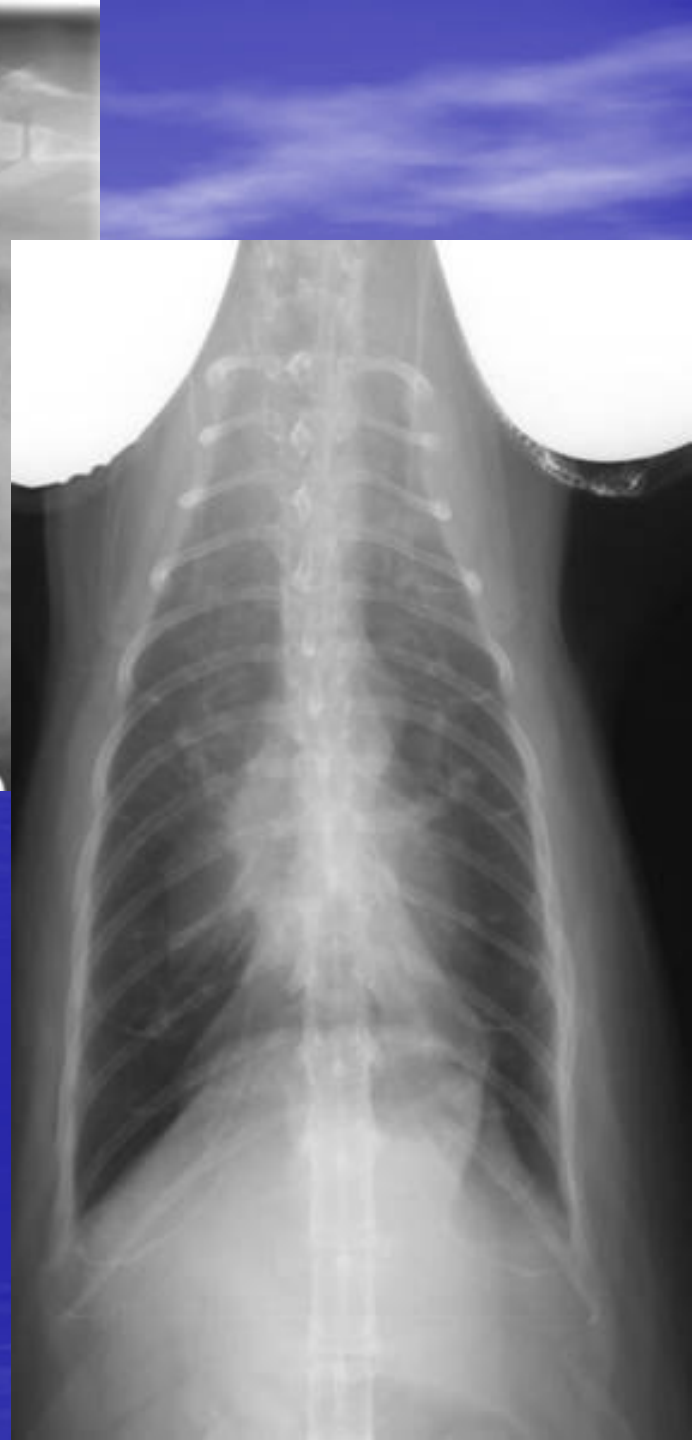
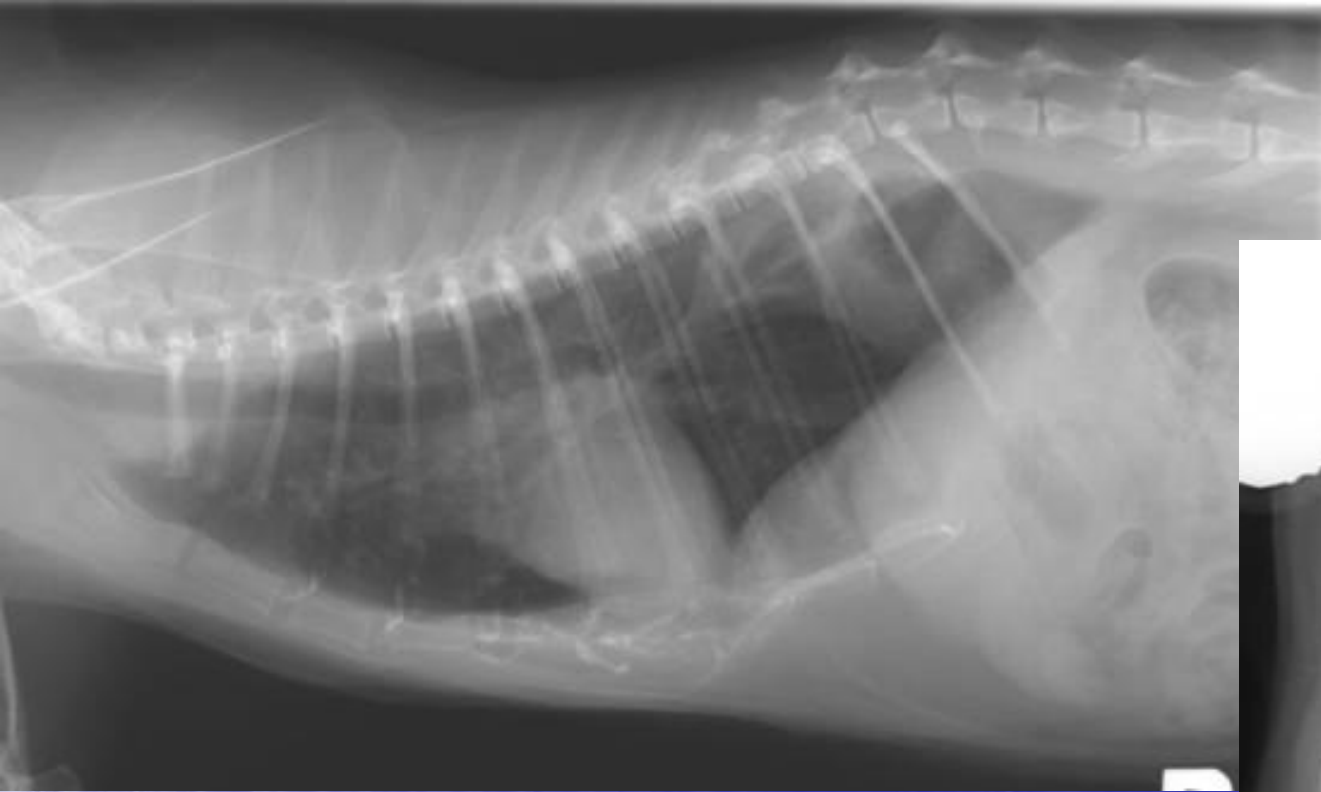Trouble – 11 yr DSH SF



Post roids





Kobe –
12 yr
DSH SF

