

FIP Type Cases

- New emerging disease
- Lethargy, pyrexia, weight loss
- Globulins >8.0 mg/dl
- Aleutians negative
- IHC positive for FIP, Dr Kuipel 517-432-2670
- Similar to the dry form-little fluid
- Twelve cases as of Jan 1st: ECE offshoot?

Disseminated Idiopathic Myositis

- First seen in 1999
- 100 cases as of Jan 2007
- <18 months of age
- Likely an acquired immunomediated disease, perhaps with a genetic predisposition
- Myositis caused by a Dutch vaccine

Signs

- Pyrexia(104-108 F)
- Lethargy
- Paresis
- Lymphadenopathy
- Diarrhea
- Partial anorexia
- Hyperesthesia
- Heart murmurs

Diagnosis

- Mature neutrophilia
- Toxic neutrophils
- Mild to moderate anemia
- Mild increase in ALT
- CK NOT increased
- No bacteria found

Pathology

- Red and white mottling of esophagus
- White streaks in diaphragm, lumbar muscles, leg muscles
- All muscle groups affected; also brain, liver, lung, trachea, spleen, bone marrow, fat

- Myofibers widely seperated by sheets of inflammatory cells
- Esophagus best to biopsy, quadriciceps group
- Multifocal so can miss it
- Dr Katrina Ramsell 503-643-2137

**Old Bridge
VETERINARY
HOSPITAL**

3604



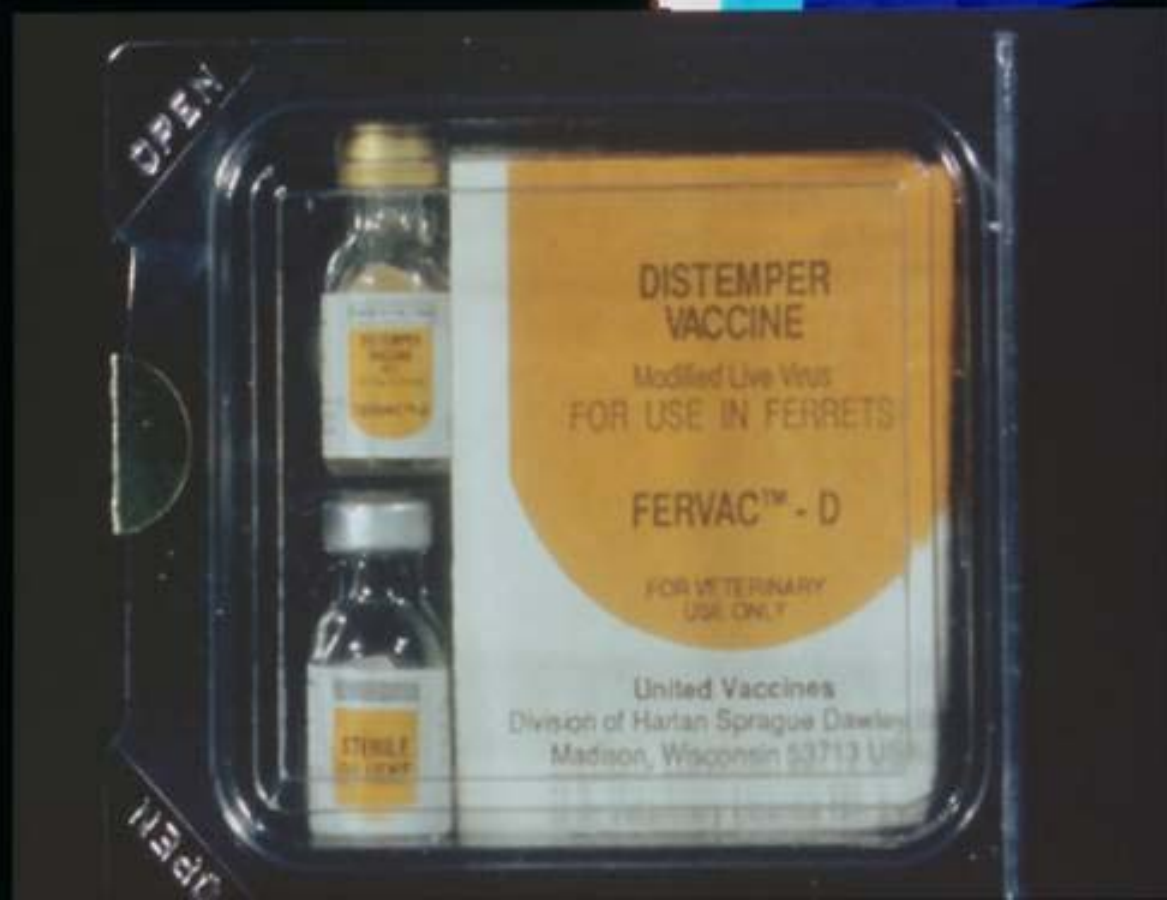The background is a dark blue gradient with several lighter blue diagonal stripes running from the top-left towards the bottom-right. The stripes are of varying widths and are spaced out across the frame.

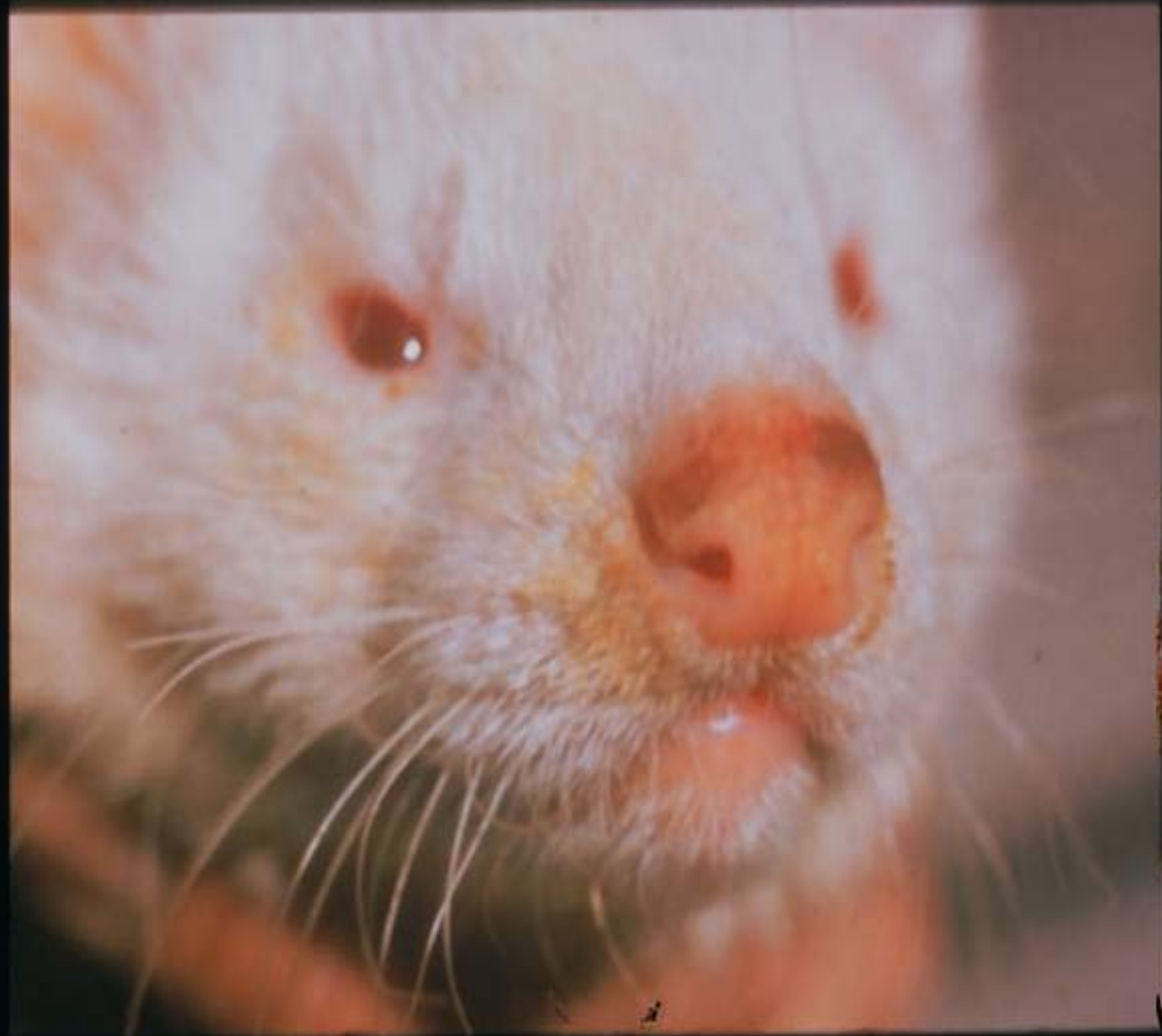GET BACK TO THE BASICS

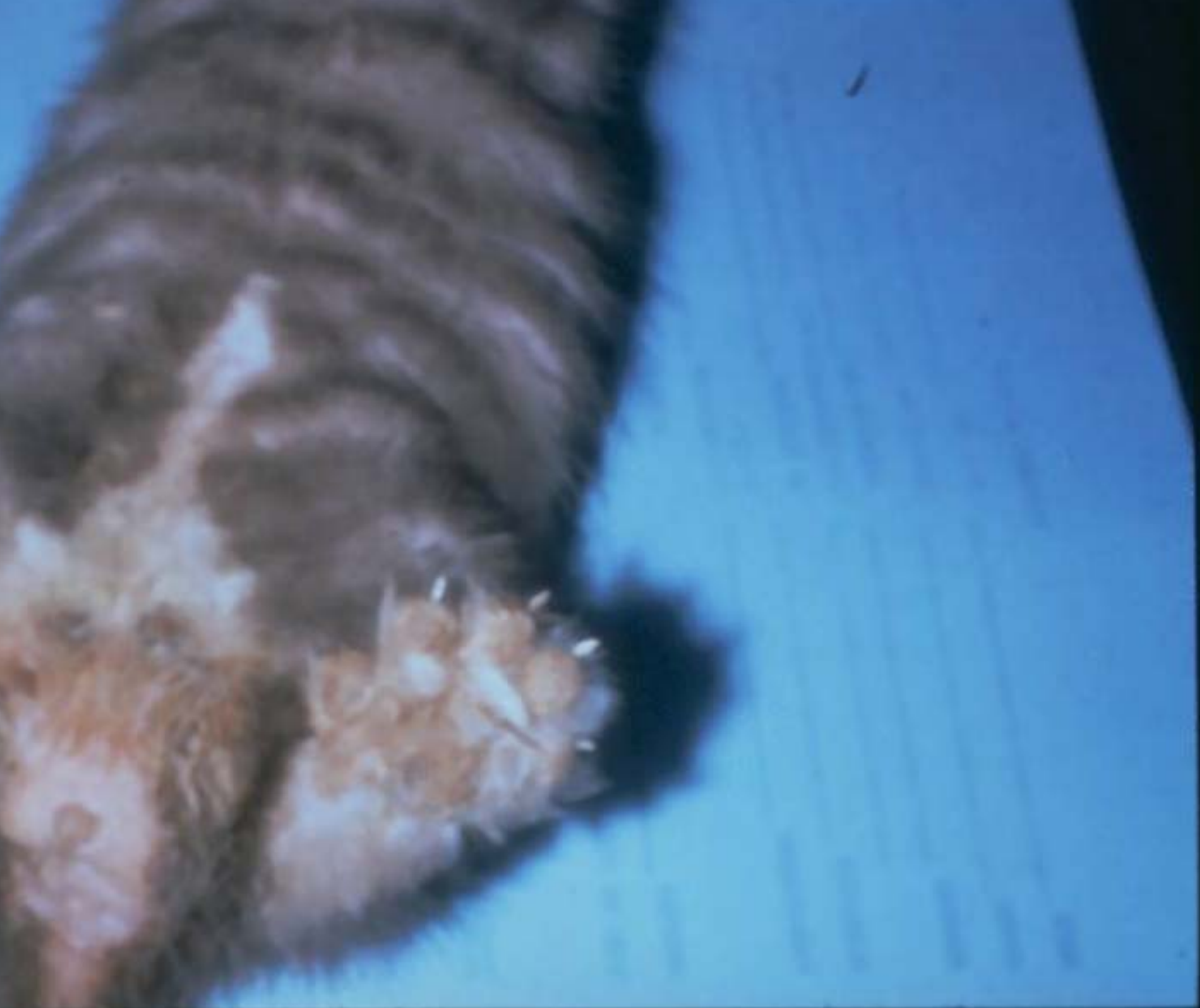Vaccines

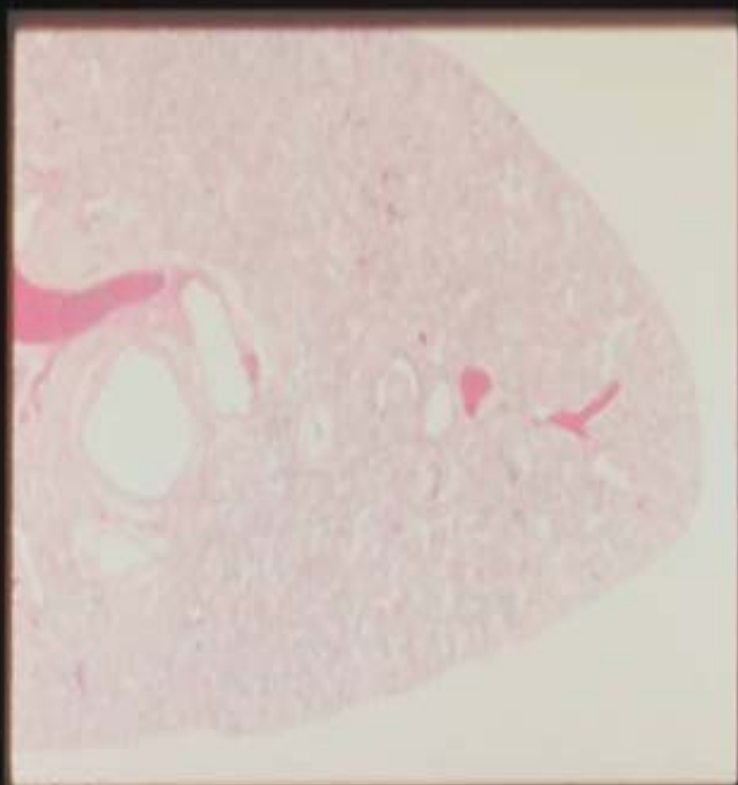
- Vaccines approved when >85% protection
- Distemper
- GalaxyD (Schering-Plough)-<2% reaction rate
- Purevax(Merial)
- Fervac-D(United) reaction rate, new release this year?? May not produce again.
- Rabies Imrab3 (Merial) ferrets 50,000x less susceptible than the fox

Canine Distemper

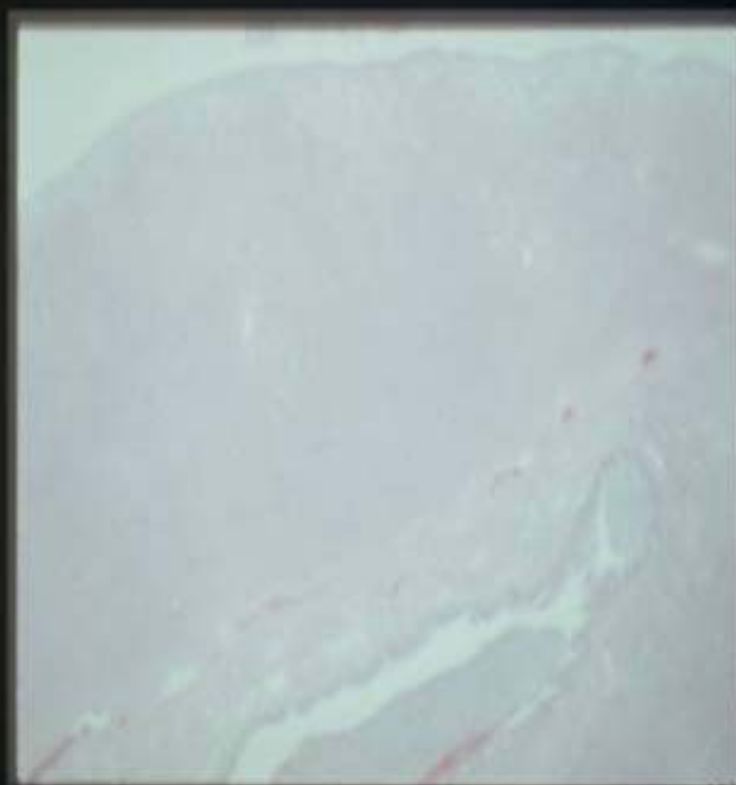








Normal ferret lung



CDV ferret lung

Vaccine Reactions

- Seen most often 3-30 minutes after vaccine
- Mild-lethargy, emesis, diarrhea. Treat with benadryl 2-4 mg/kg and pred 2-4 mg/kg
- Severe-above plus recumbent, bloody diarrhea, emesis-scary!! Treat with above plus IV fluids, epinephrine (.01 mg/kg or .02 cc)

Nutrition

- Cat, kitten, many ferret foods contain 32-38% protein, 18-23% fat, 20-30% COH.
- Polecat diet 55% protein, 38% fat, 1.2% COH. Pretty Pets Natural Gold, Evo, D/M
- Fiber needs to be low
- Protein should be animal source

SAMPLE DIETS

	PROTEIN	FAT	FIBER
KITTEN CHOW	30	8.0	4.5
CAT CHOW	35	8.5	4.0
ANF KITTEN	32	20	
SCIENCE GROWTH	34	25	1.0

- Ear mites-common, mites live off host 2 weeks to 4 months, 1% Ivomec in ear, treat all ferrets twice 3 weeks apart.
- IV catheters-24Gauge cephalic catheters, or 20 gauge needle in trochanteric fossa of femur
- Aging a ferret
- Warn clients of age related diseases
- Fecals-mainly coccidia

Spleens

- I grade from 1 to 10
- 5 is at the urinary bladder
- If a 7 or enlarges (especially rapidly), CBC
- >96% biopsies are EMH

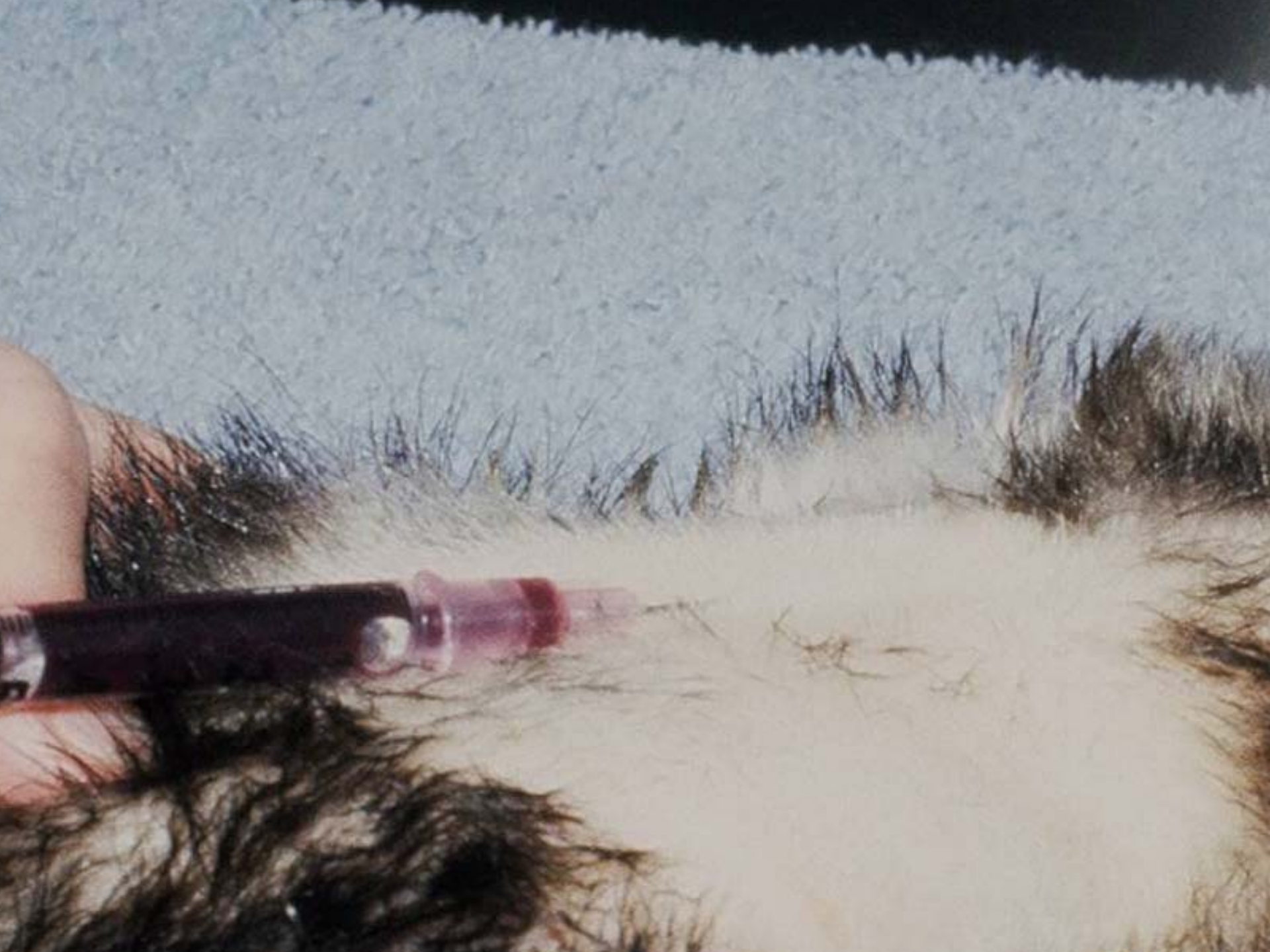SPLENOMEGALY

- **Grade 0-10**
- **Neoplasia - less than 5%**
- **EMH - 95%**

- Colds and influenza
- Ferrets begin diseases at 4 years of age
- Ferrets are old a 7 years of age
- Aleutian Disease-Parvovirus, chronic wasting, many remain normal.
- Antigen-antibody complexes in many tissues

Aleutians

- Blue Cross Animal Hospital
Attention Dr. Blau-CEP TESTS
401 North Miller Avenue
Burley, Idaho 83318 IFA, antibodies
- . Avecon Diagnostics, Incorporated
501 Grouse Drive
P.O. Box 8
Bath, Pennsylvania 18014 Saliva



Patient _____ Date _____
_____ tablets _____ times daily
_____ CAPSULES every _____ hrs.

For Veterinary Use Only
MOUNT VERNON ANIMAL HOSPITAL
5623 Richmond Highway
Alexandria, Virginia 22309
360-6600

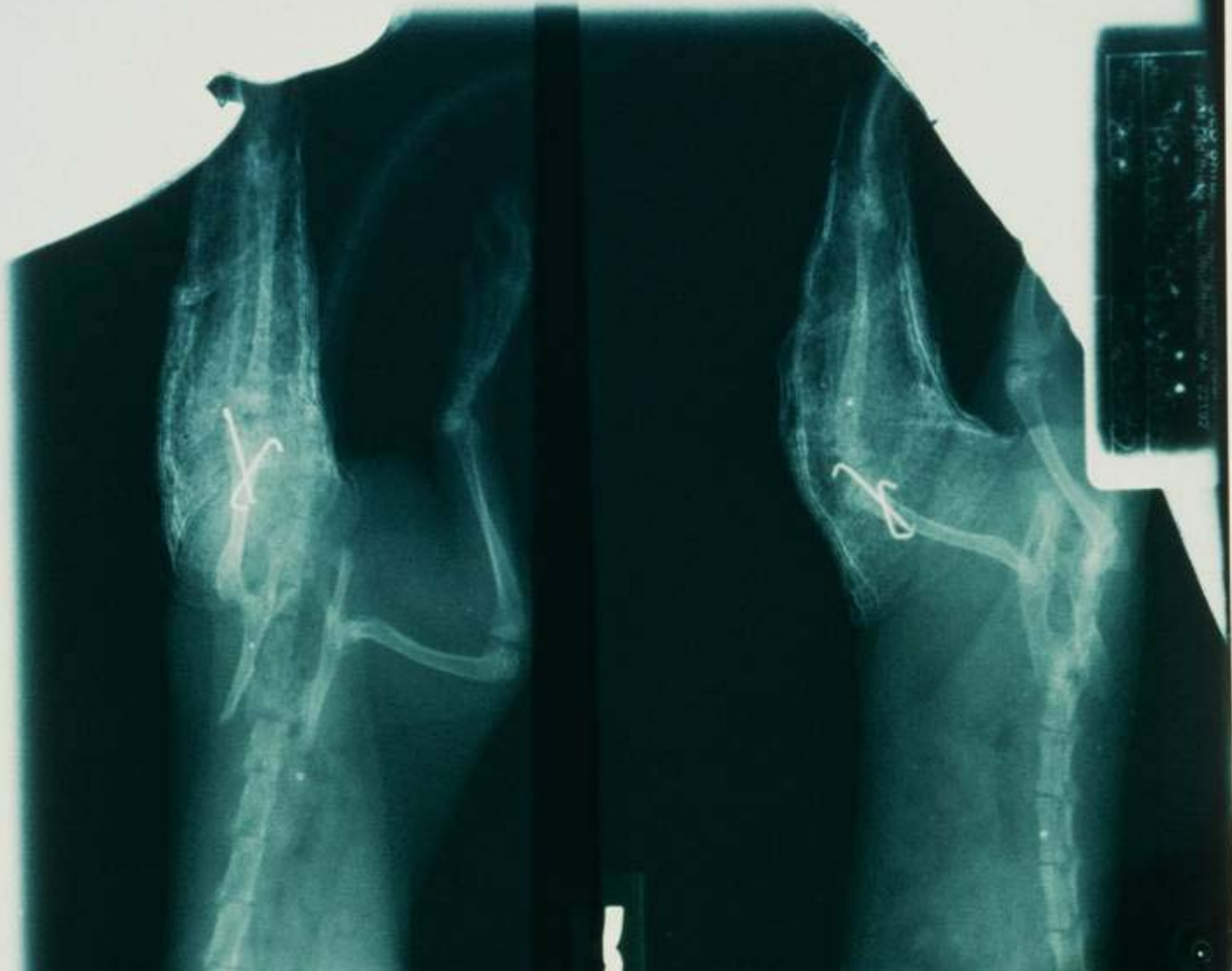

95



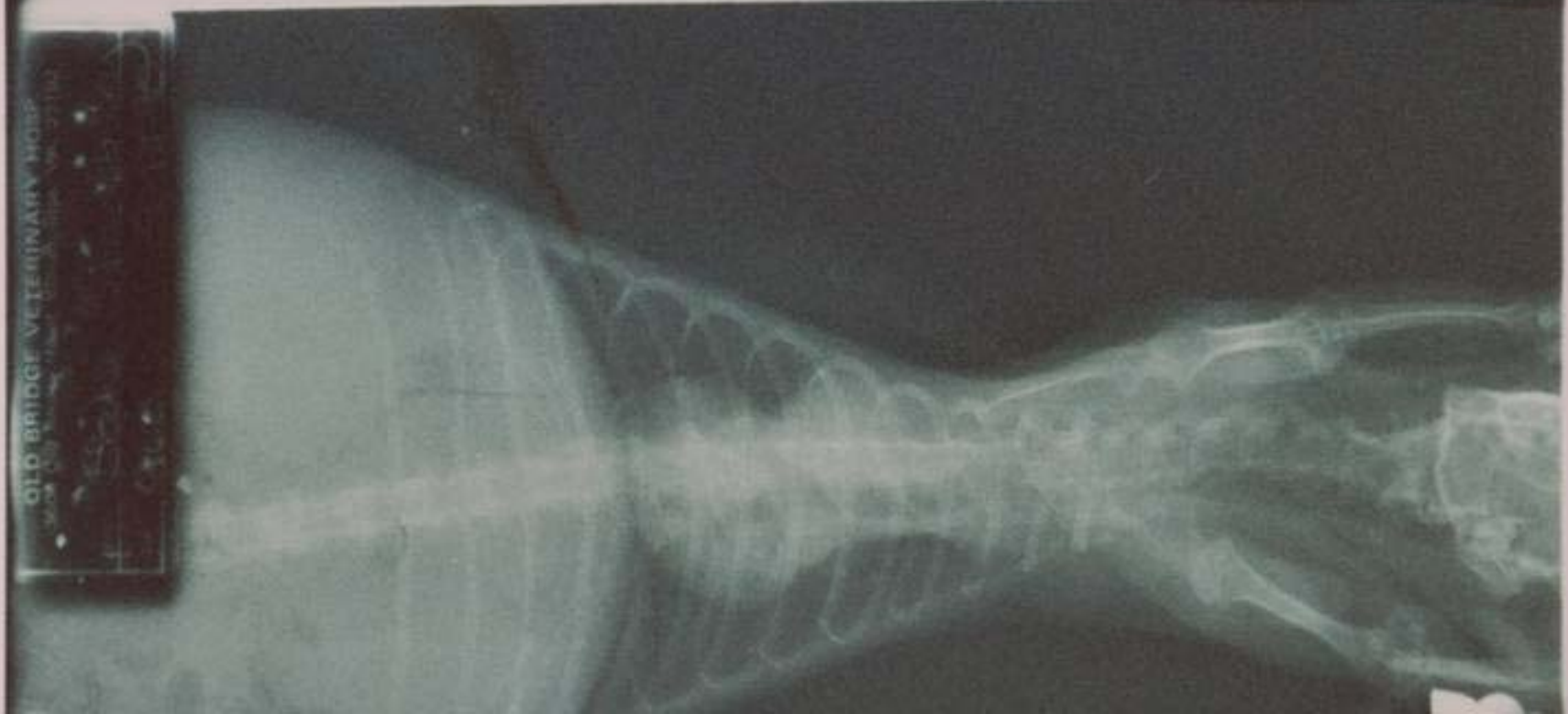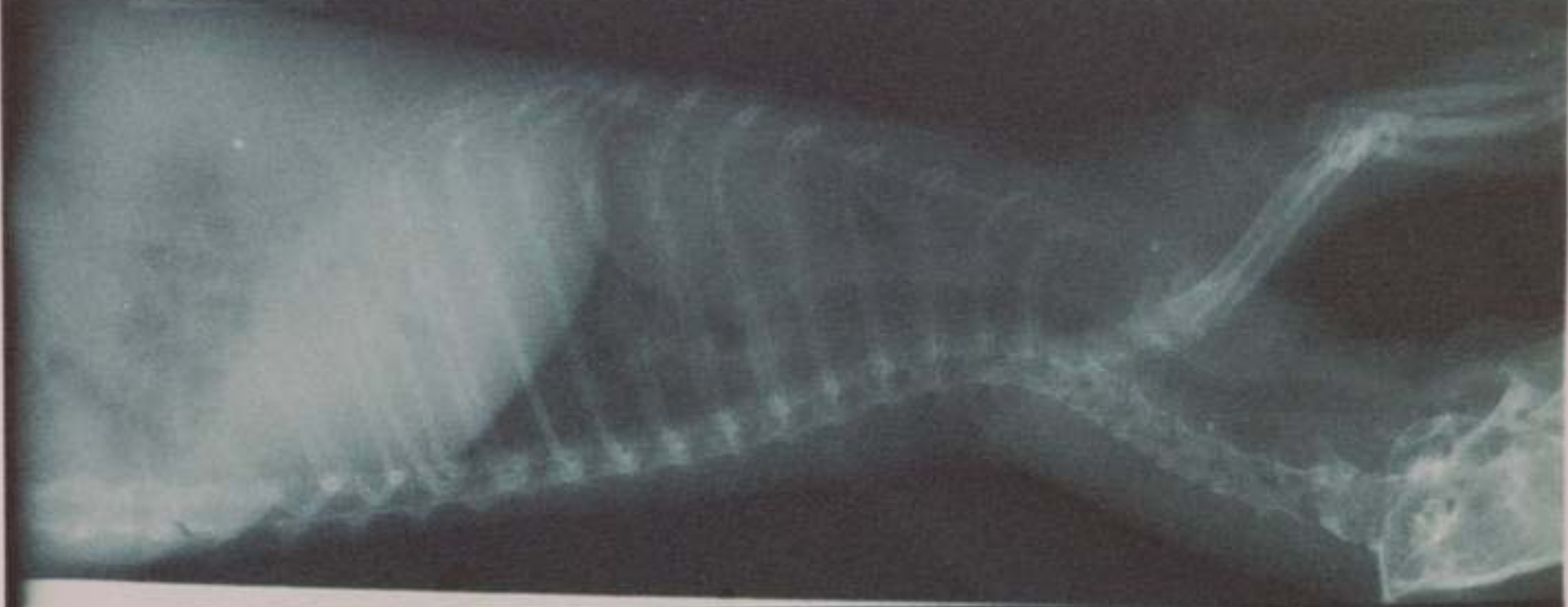PLATE V. TIBETAN 76

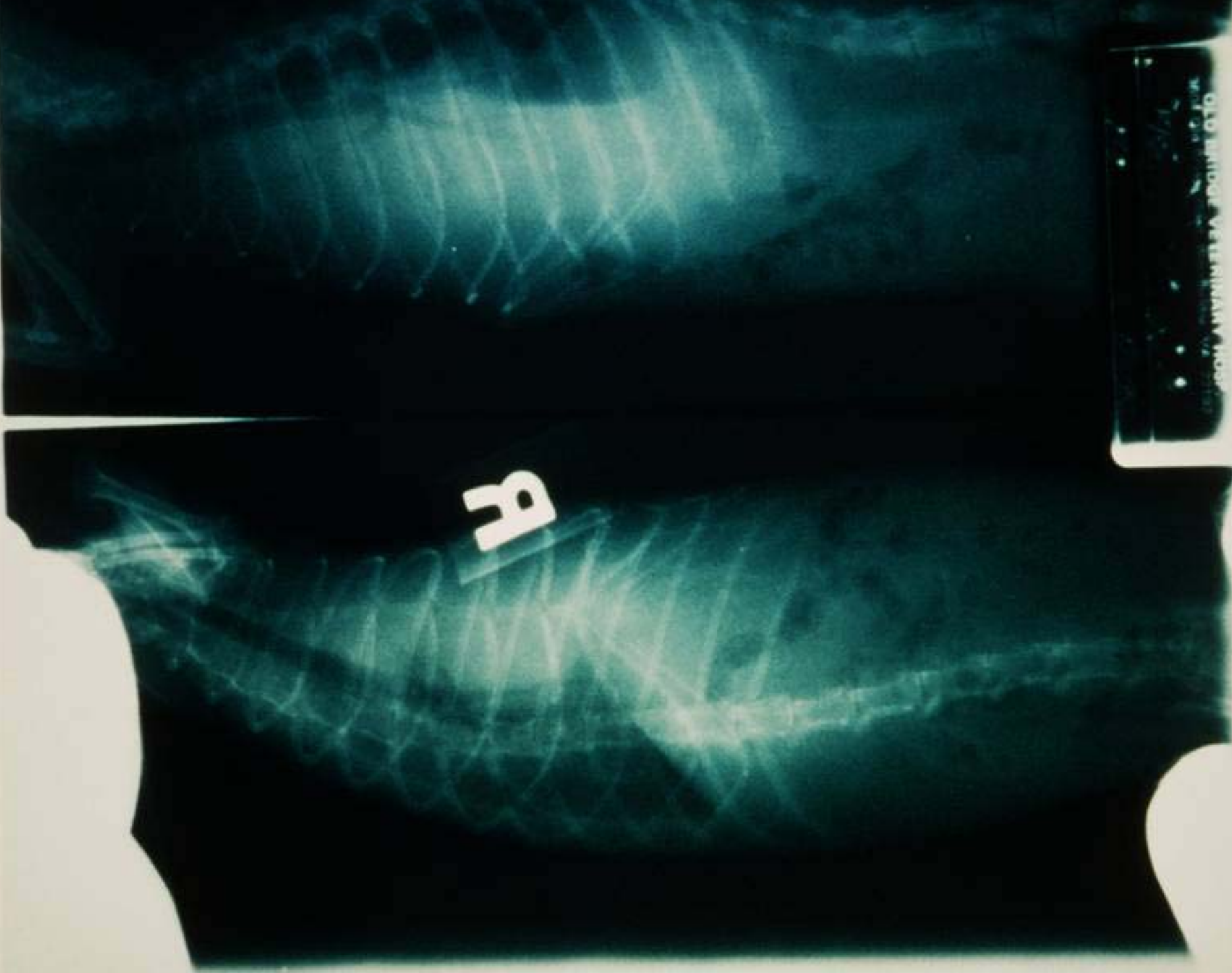
PLATE V. TIBETAN 76



13

OLD BRIDGE VETERINARY HOSP





R

OTO BIOMEDICAL SYSTEMS
1000 UNIVERSITY AVENUE
ANN ARBOR, MICHIGAN 48106
TEL: (313) 763-1000

My Doctor said "Only 1 glass of alcohol a day". I can live with that.



Intestinal Diseases- Lymphoplasmacytic Inflammatory Bowel Disease

Garner- 115 intestinal biopsies, 67% had LPIBD with some Eosinophilic IBD, 30% had LPIBD, 3% Eosinophilic IBD.

120 gastric biopsies, 88% LPIBD, 12% had both LPIBD and EIBD

Possible causes-food hypersensitivity(esp glutens) aberrant immune response, bacterial/viral infections, bacterial overgrowth, toxins

Signs

- Weight loss
- Diarrhea
- Vomiting
- bruxism
- Melena
- Secondary acute suppurative hepatitis

Diagnosis-Biopsy

Signs plus

Lipase > 500 IU/L

Antech; > 1000 IU/L

Idexx

Serum Globulins

> 3.0 g/dl

ALT and GGT

elevations

- Relative lymphocytosis
- Biopsy-ferrets normally have more lymphocytes in gi
- Pylorus, duodenum, ileum
- Gastric lymph node
- Liver if ALT and GGT

Treatment

- .9 mg/kg immuran q 24-72 hours (gradual response)
- Perform CBCs (bone marrow suppression) and lipase every 1-3 months
- Prednisone 2mg/kg SID to BID
- Z/D , Duck and Potato, feline lamb and rice
- Metronidazole 15-20 mg/kg SID to BID
- Baytril 5-10 mg/kg SID
- Amoxicillin 5-10 mg/kg BID to TID

Helicobacter Gastritis

- Gram negative microaerophilic rod
- Virtually 100% of ferrets harbor H. Mustelae
- Resides primarily in pyloric area and first 1 cm of duodenum
- Maybe associated with gastritis and peptic ulcers

Signs

- Melena-almost pathognomonic
- Vomiting
- Bruxism

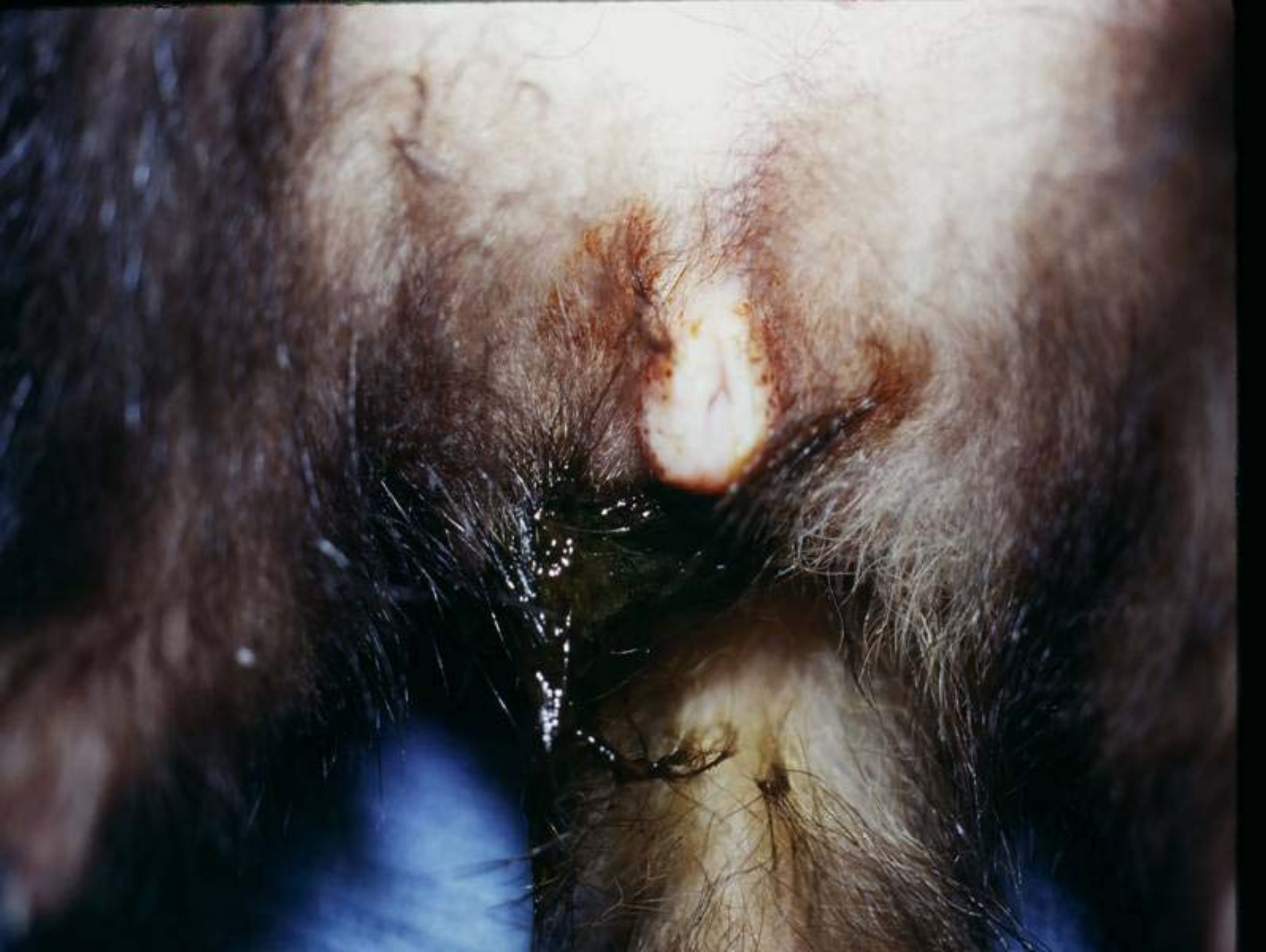Pawing at mouth

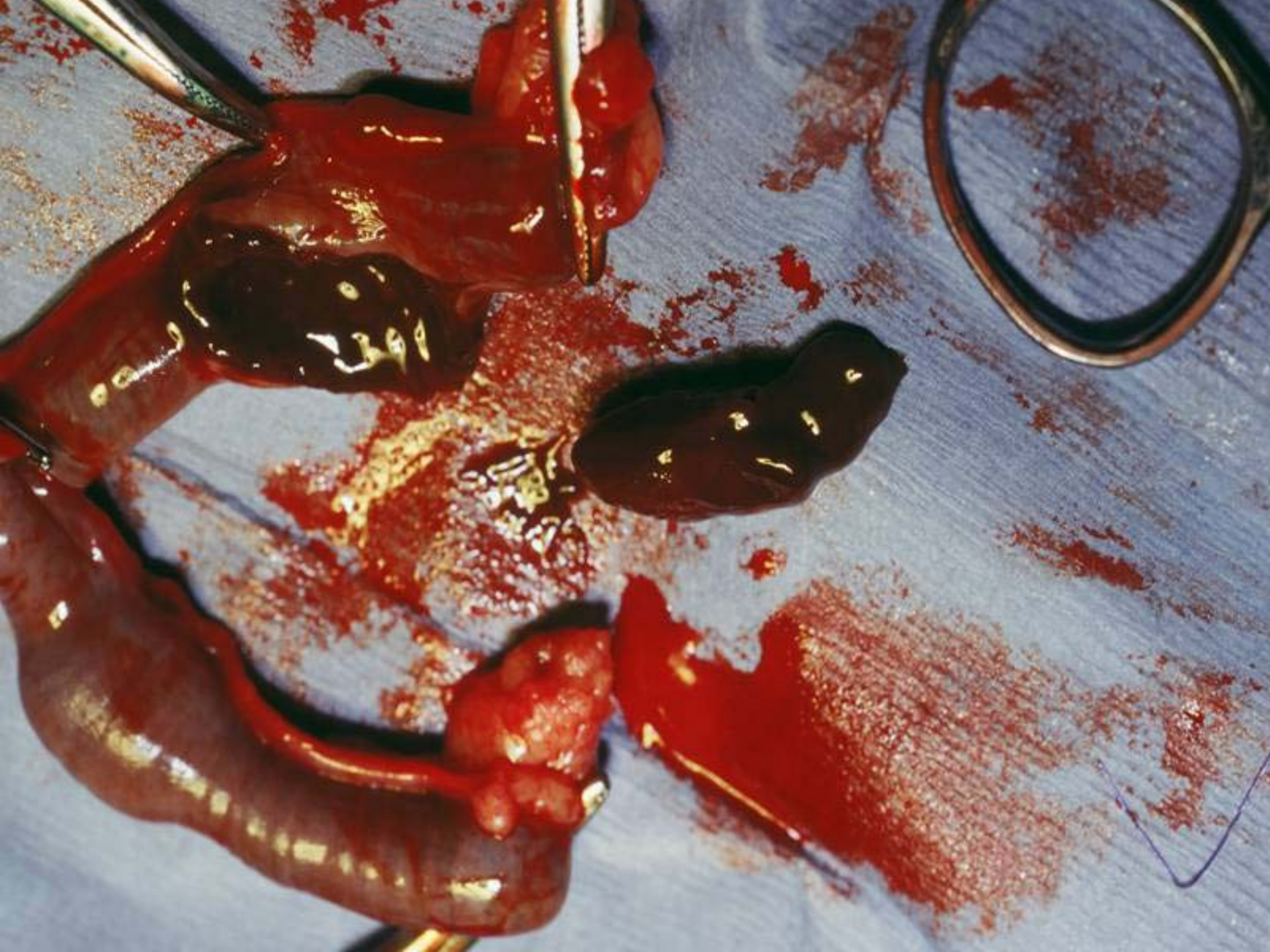Weight loss

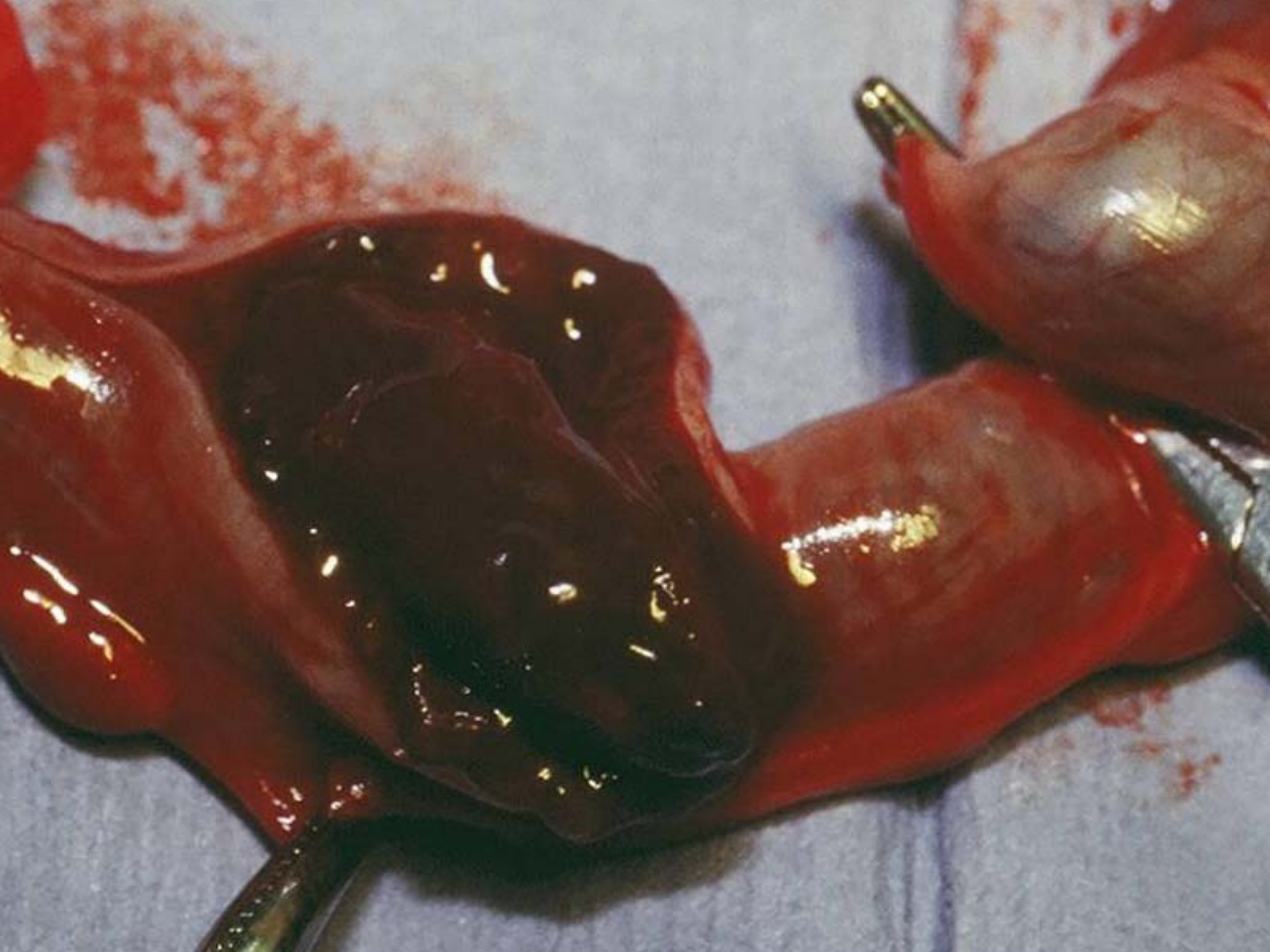Anorexia

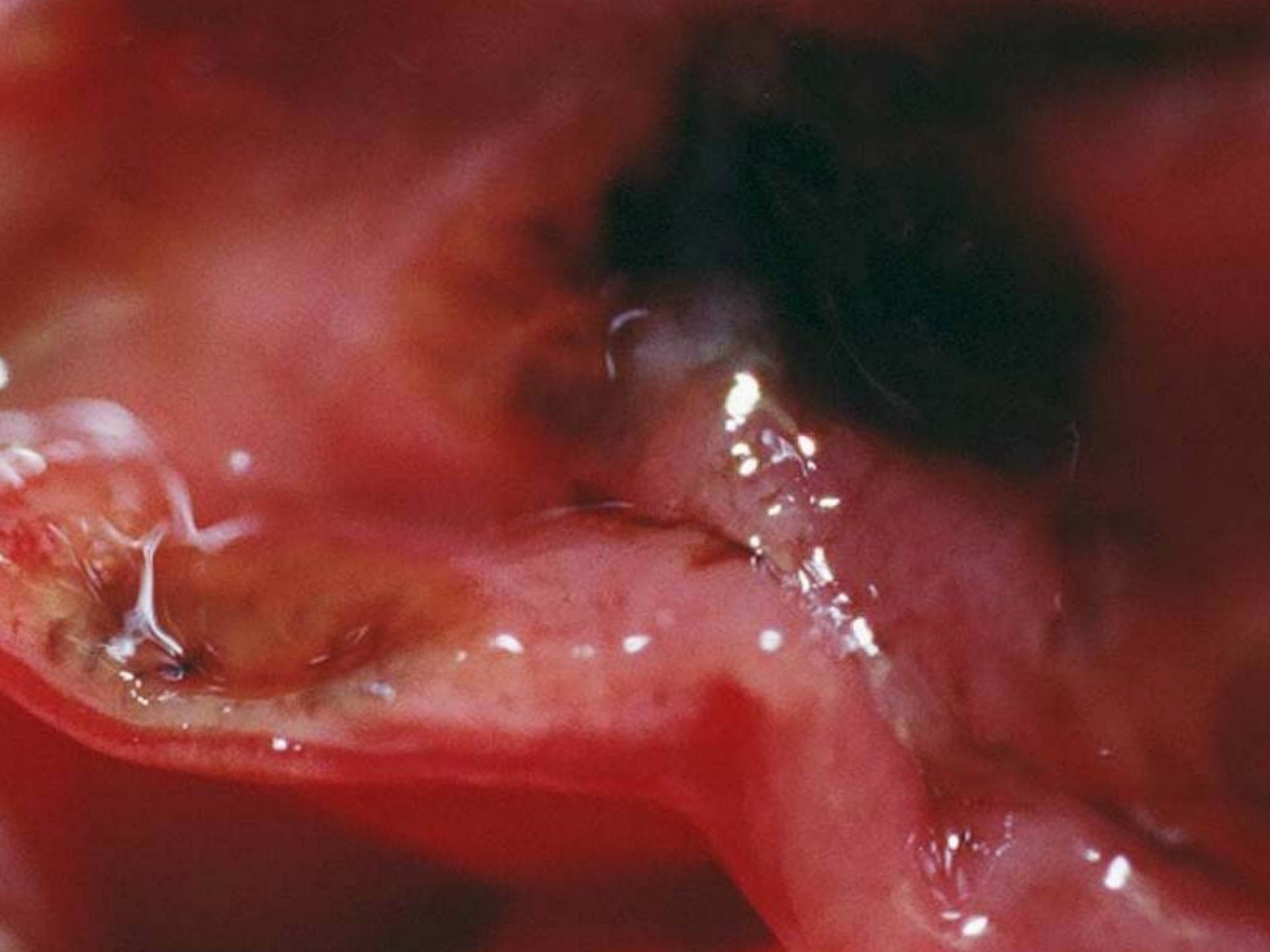
Overdiagnosed?

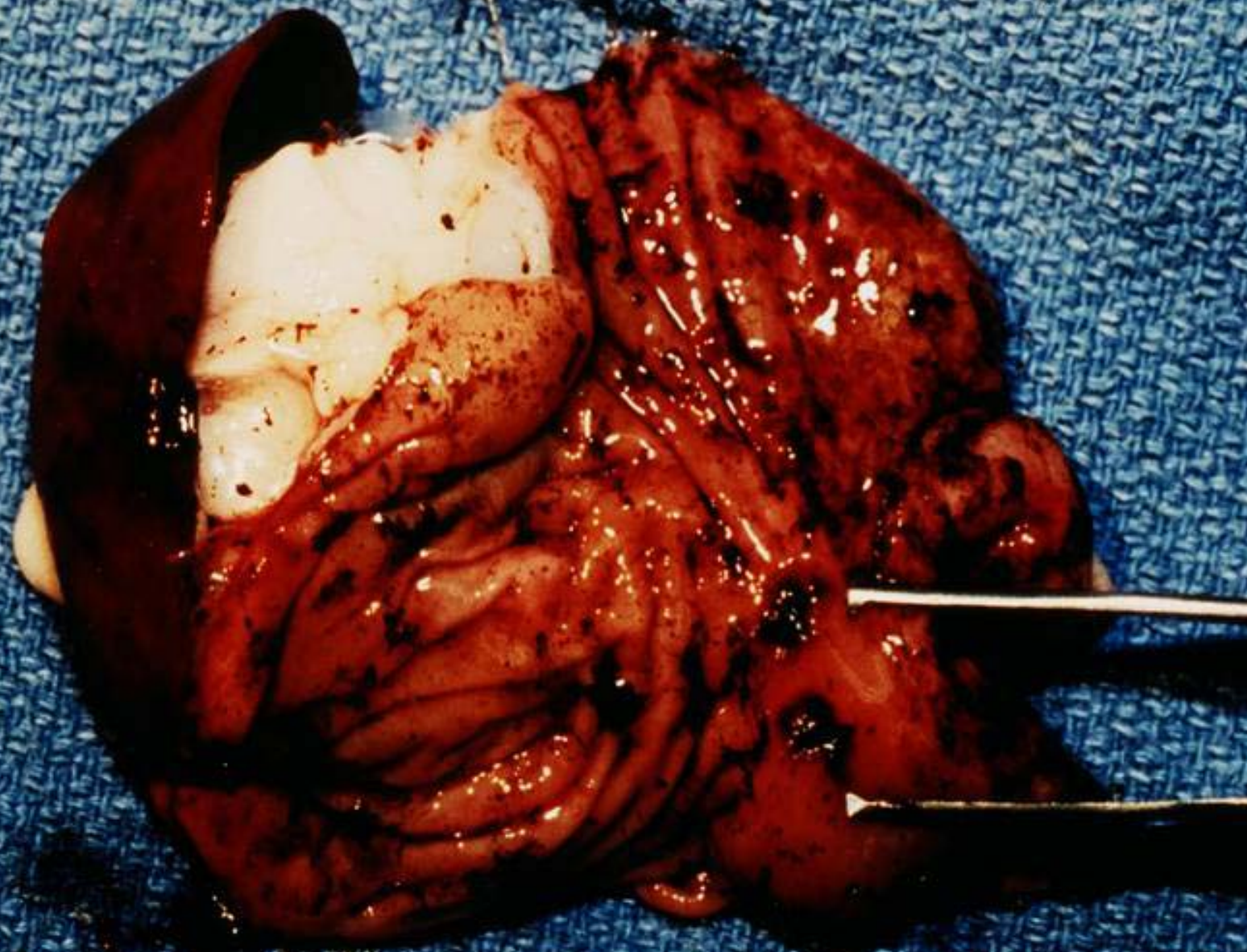
Acute Death-Serosal
artery rupture

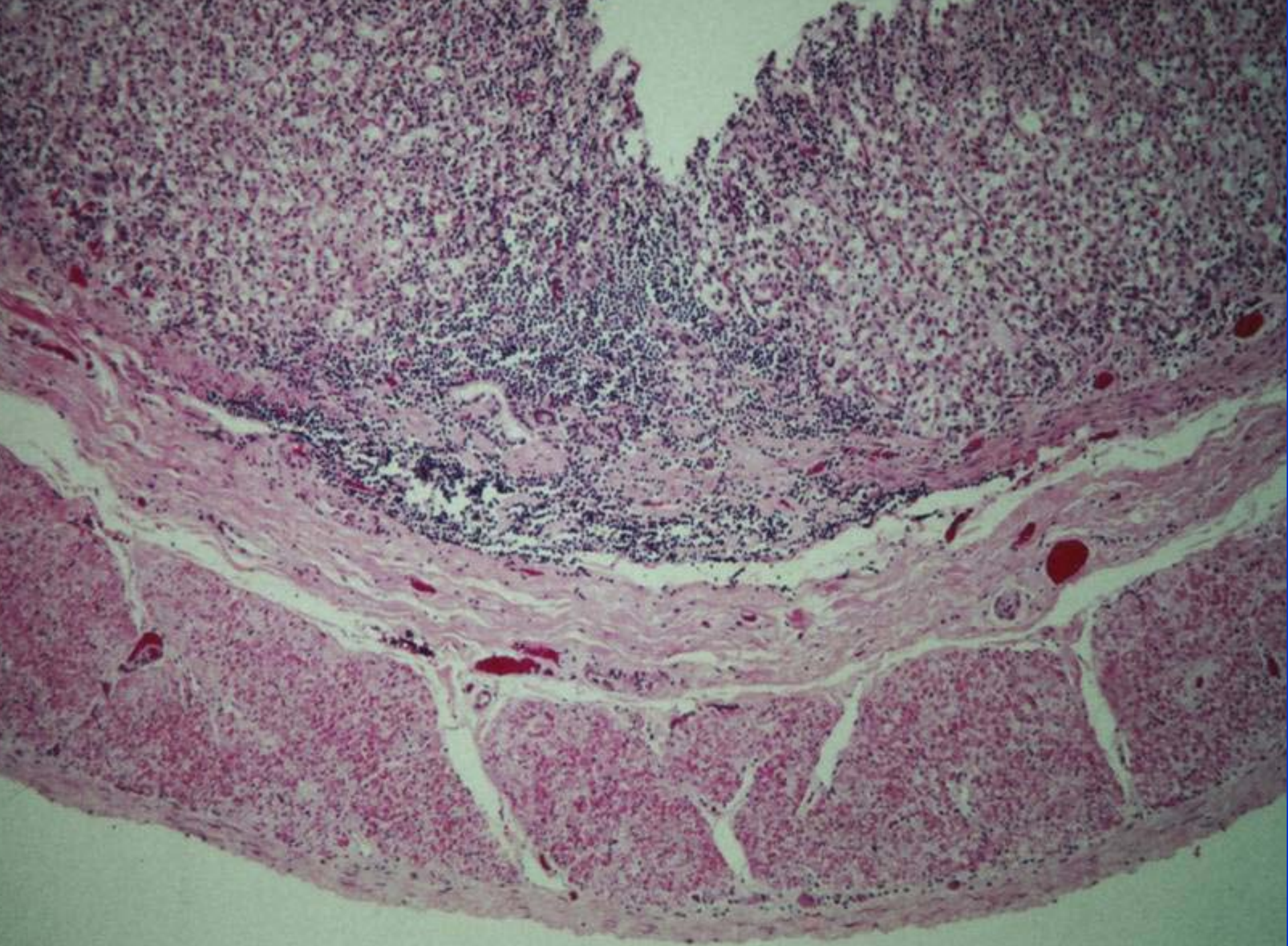


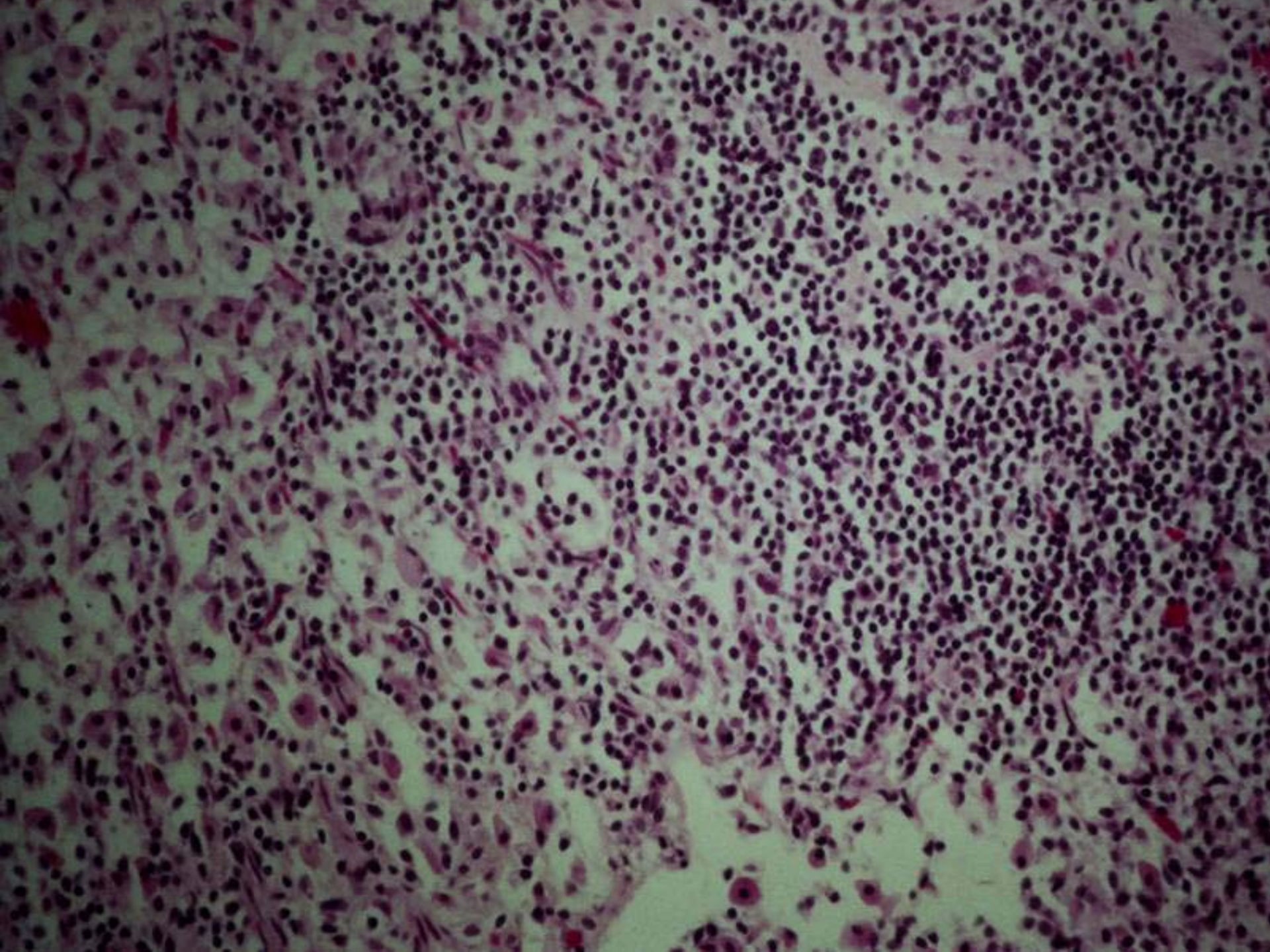


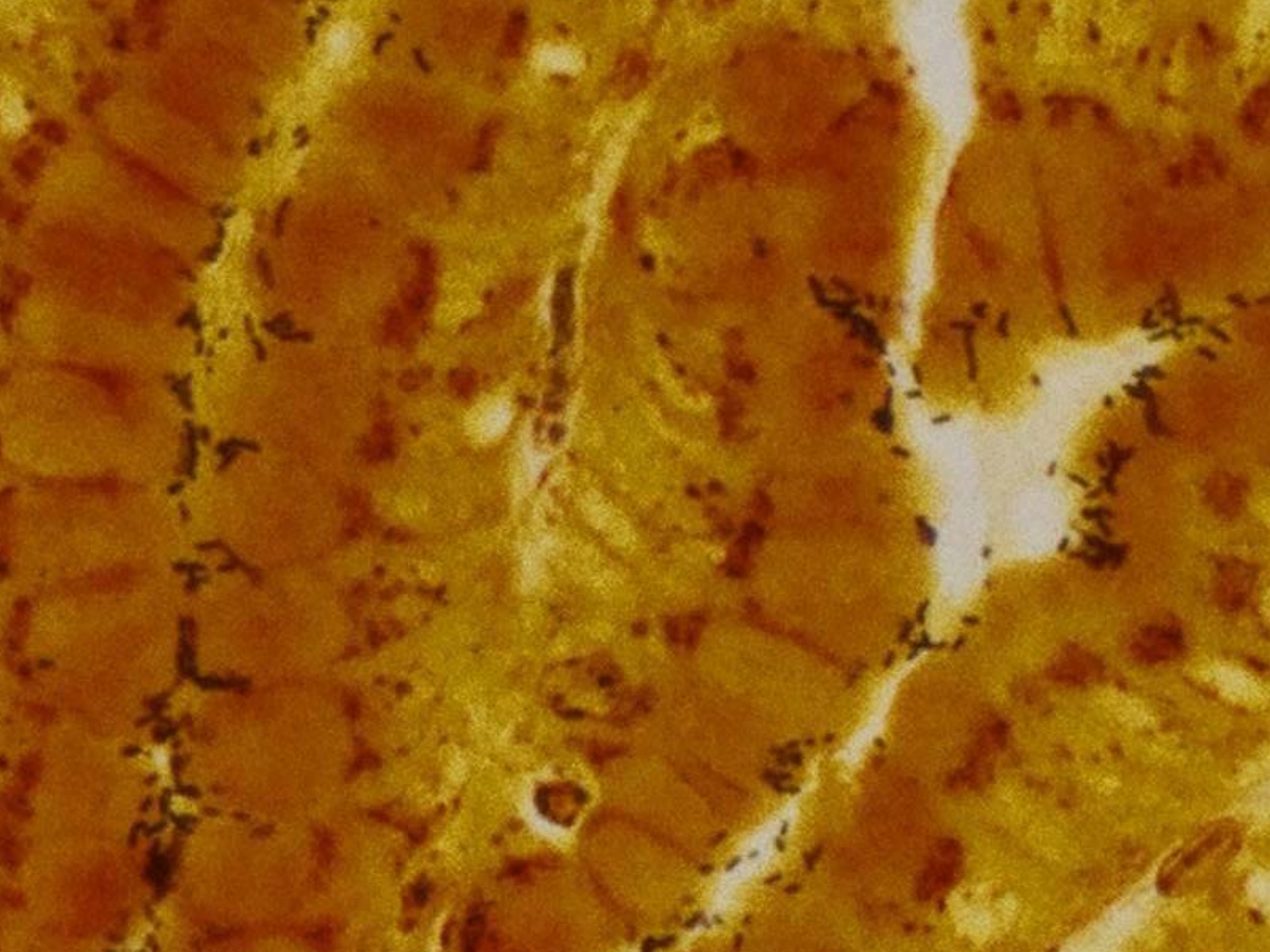












Diagnosis

- Signs
- Biopsy
- Urea breath test
- PCR of feces
- Fecal culture
- Stool antigen test
- Rapid Urea Test
- All have it!!! Tests somewhat useless

Treatment

- Metronidazole 20 mg/kg BID for 10 days
- Amoxicillin 10 mg/kg TID for 1 month
- PeptoBismol .5 cc TID
- Sucrafate 100 mg TID
- Famotidine .5 mg/kg SID
- Biaxin 50 mg/kg
- Omeprazole .7 mg/kg SID
- Bland diet (turkey baby food)
- Difficult to eradicate

GASTRIC ADENOCARCINOMA

- Tumors 6 - 8x incidence
- Gastritis → T cell cytokines → B cell proliferation
- Lymphoid germinal centers → MALT

Epizootic Catarrhal Enteritis

- Corona virus, can last in environment weeks to months
- Recovered ferrets shed virus for up to 6 months
- Ferrets < 4 months show little to no symptoms
- Ferrets 5-18 months mild to moderate symptoms
- Virus less Virulent?

Signs

- Green/brown diarrhea
- Emesis
- Weight loss
- Anorexia
- Occur 2-3 days post exposure
- Many have ascending portal hepatitis

Diagnosis

- History!!!
- Increased ALT
- Lymphocytosis, decreased albumin
- Increased lipase
- No serology
- Histopath, Immunohistochemical testing of gut mucosa

Treatment

- Fluids
- Forced feeding
- Antibiotics (baytril/amoxi 10 mg/kg TID)
- Metronidazole (15-20 mg/kg SID)

Coccidia

- Fairly common
- Small virulent species
- Check all ferrets from pet stores
- Treat with albion

Trichobezoars

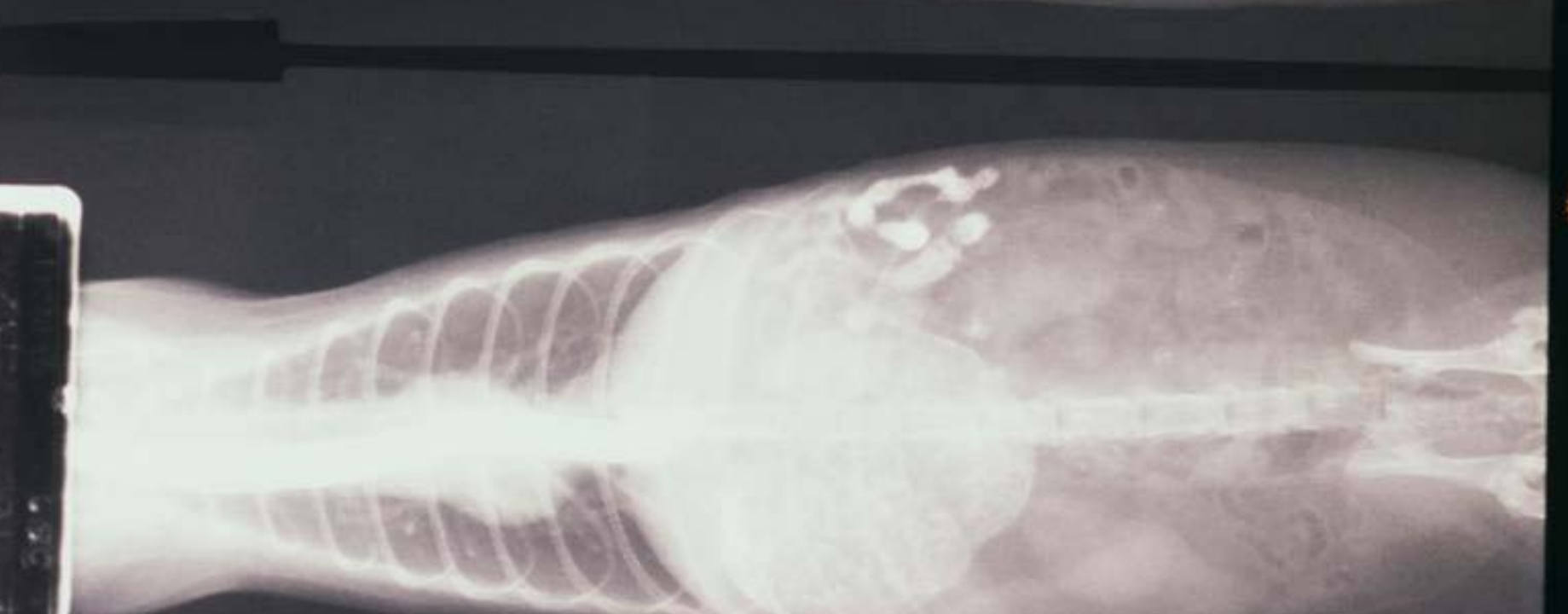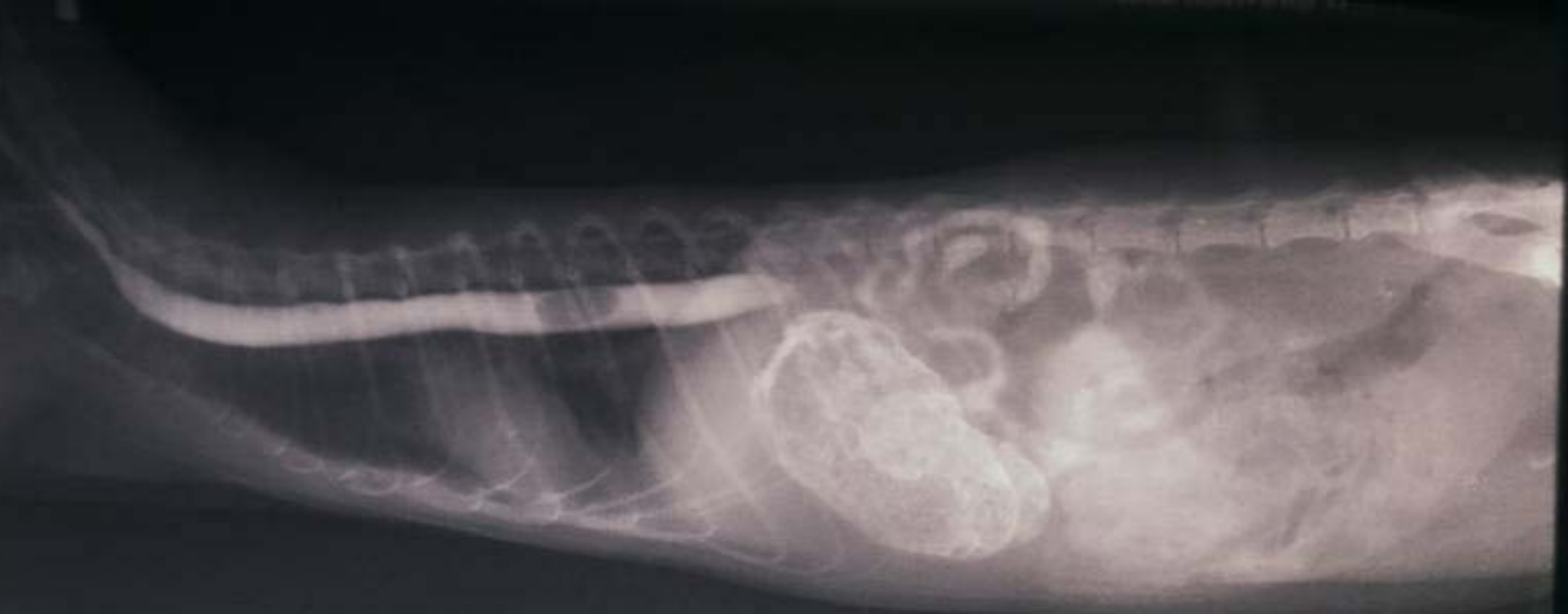- Barium often misses it
- 10-20 cc air (pneumogastrogram) better
- Usually can't palpate
- Often no symptoms
- Anorexia, weight loss, emesis
- All surgeries palpate stomach
- Prevention-laxatone, frequent grooming
- Stomach motility problem secondary to inflammation of stomach and /or small intestine, reglan .5-1.0 mg/kg BID

Foreign Bodies

- Primarily rubber, especially young ferrets
- Acute
- Anorexia, bruxism,
- Won't move on the exam table
- Radiographs usually useless
- Palpation is the key

Megaesophagus

- Uncommon
- Gastritis → emesis → esophagitis?
- Signs coughing, choking, neck extension, regurgitation, weight loss, distress while eating
- Diagnosis-barium with AD
- Treatment-zantac 3.5 mg/kg BID, carafate 100 mg TID, reglan .5-1.0 mg/kg BID



Eosinophilic Granulomatous Disease

- Uncommon
- Eosinophilic infiltrates in lymphatics and multiple organs
- Etiology-unknown-parasites, allergies?
- Signs-diarrhea, anorexia, weight loss, lethargy
- Diagnosis-biopsy, some have peripheral eosinophilia

- Treatment
- Hypoallergenic diet
- Immuran .9 mg/kg SID
- Prednisolone 1-2 mg/kg SID

Bacterial Overgrowth

- Etiology-IBD, ECE, diet changes, coccidia, foreign body. Clostridium-enterotoxemia, Salmonella, E.Coli
- Signs- green diarrhea, anorexia, weight loss, bruxism, emesis
- Treatment
 - baytril 5 mg/kg BID PO
 - amoxicillin 10-20 mg/kg BID PO

Neoplasia

- Primary Lymphoma
- IBD, Helicobacter
- Mesenteric lymph nodes initially affected
- Lymphocytosis, increased lipase, increased globulins
- Treatment-handout



Urinary Obstruction

Prostate disease-prostatic hyperplasia
secondary to adrenal disease common and
the first in the differential in a male with
stranguria

Diagnosis – palpation, contrast, sonography,
exploratory

Treatment-adrenalectomy, drainage, C&S

Treatment-Casodex 5 mg/kg SID

- Flutamide 10 mg/kg PO BID
- Lupron 4 month repository
- Melatonin implant (Malatek www.melatek.net)
- Baytril 10 mg/kg for 4-6 weeks
- Differentials include urolithiasis, cystitis, neoplasm of bladder neck or urethra

Calculi

- Feeding a high quality highly digestible animal source of protein results in sulfuric acid production and an acidic urine
- Acid urine prevents phosphate calculi
- Plant protein(corn meal, wheat gluten, soybean meal) → $\text{pH} > 7.0$

Calculi

- Magnesium content of food, urinary pH, meal frequency, size of meal, and water intake can influence urolithiasis formation.
- Post prandial urinary pH rises .5 to 1.25
- Totally Ferret produces a urinary pH of 5.8

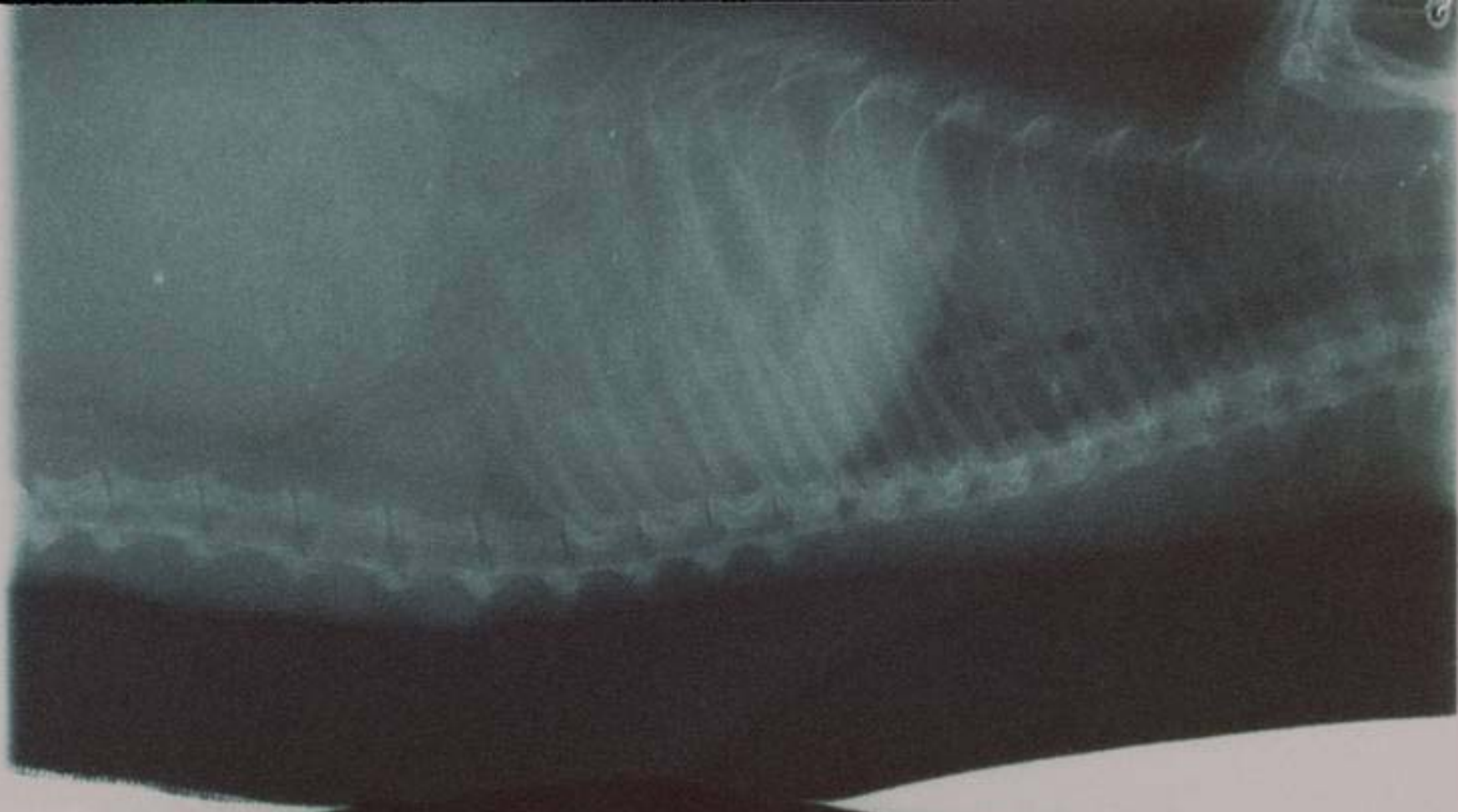Cystitis

- Less common than dog
- No reports of idiopathic cystitis as seen in the cat
- E Coli and Staph the most common offenders

Bladder Atony

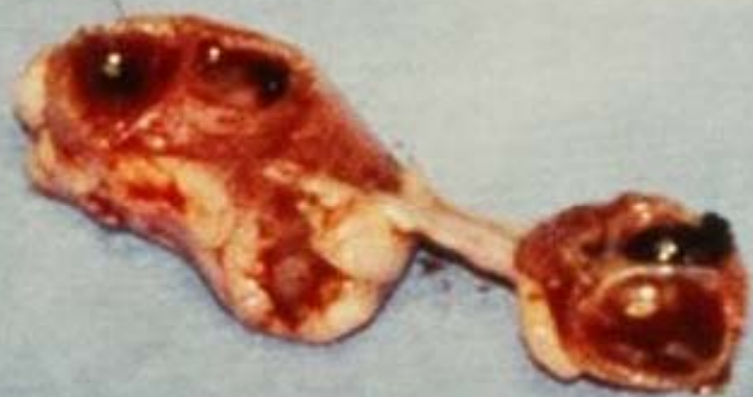- Flaccid large bladder
- Often occupies the entire abdomen
- L1-L2; S1-S3, bladder wall
- Treatment-phenoxybenzamine, bethanachol,
- Manually express
- Always secondary infection-use intermittent antibiotics

- L1-L2 storage (sym) → caudal mesenteric ganglion → bladder
- S1-S3 (somatic) → pudendal nerve → external urethral sphincter
- S1-S3 (para) → pelvic nerve → activate detrusor
- Bethanachol .6 mg TID; Phenoxybenzamine 1.25 mg SID to BID



Renal Cysts

- Common, congenital
- Primary cause of renomegly
- Some cysts larger than kidney itself
- Can remove the kidney although rupture is rare
- Differential for renomegly-neoplasia, pyelonephritis, hydronephrosis



Chronic Interstitial Nephritis

- Common to some degree in ferrets > 4 years of age
- #1 cause of chronic renal failure
- Bun/Creatinine discrepancy
- BUN 344 Creatinine 1.9
- BUN 404 Creatinine 1.5
- BUN 208 Creatinine .69

KIDNEY DISEASE

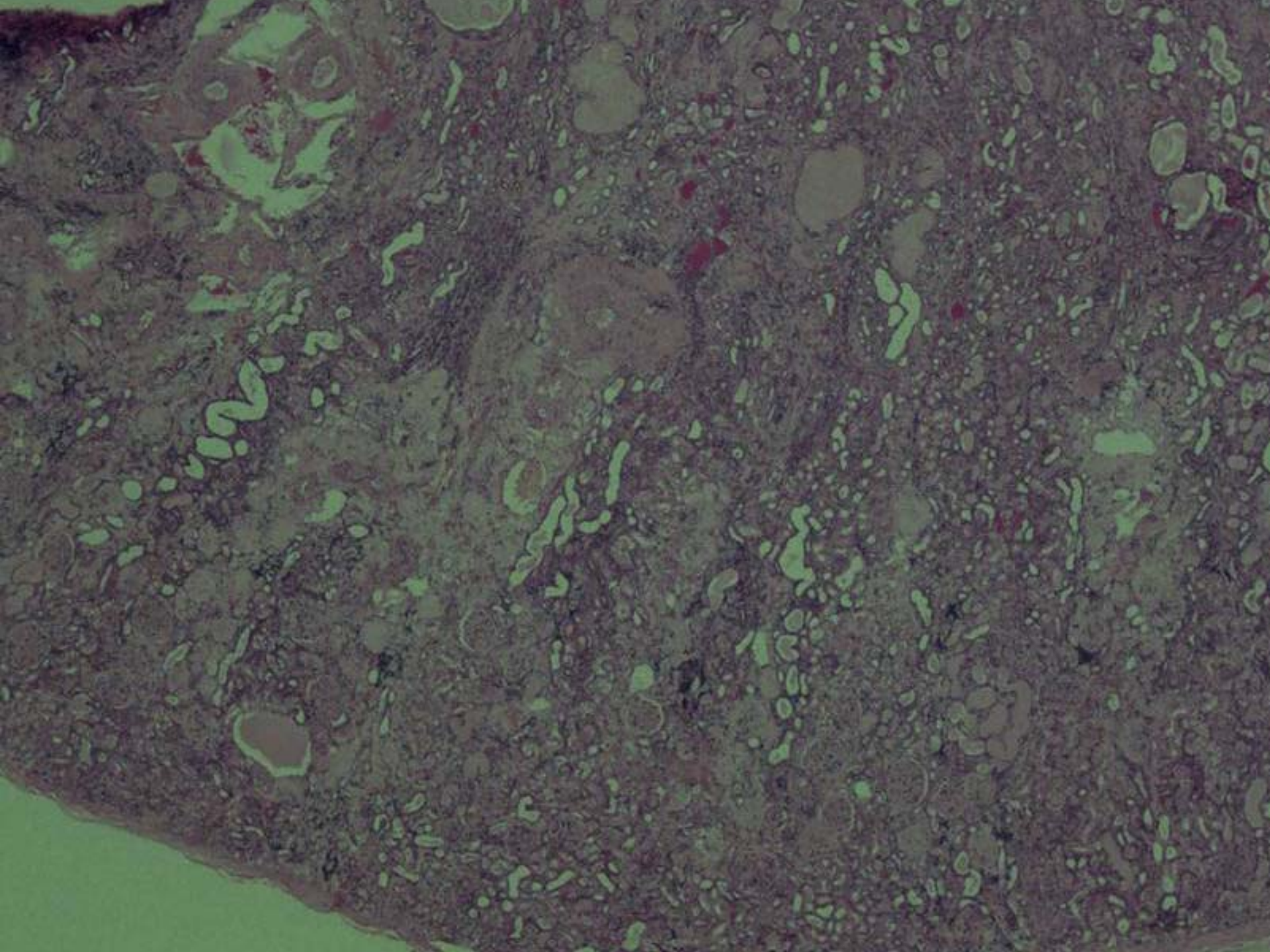
	BUN (mg/dl)	Creatinine (mg/dl)	Phosphorus (mg/dl)
Normal	8-31	0.16-0.84	3.7-7.4
Case 1	404	1.5	18.5
Case 2	320	1.1	
Case 3	472	1.86	25.7
Case 4	208	0.69	16.89
Severe Uremia	319	3.02	
Analogous	1260	12	

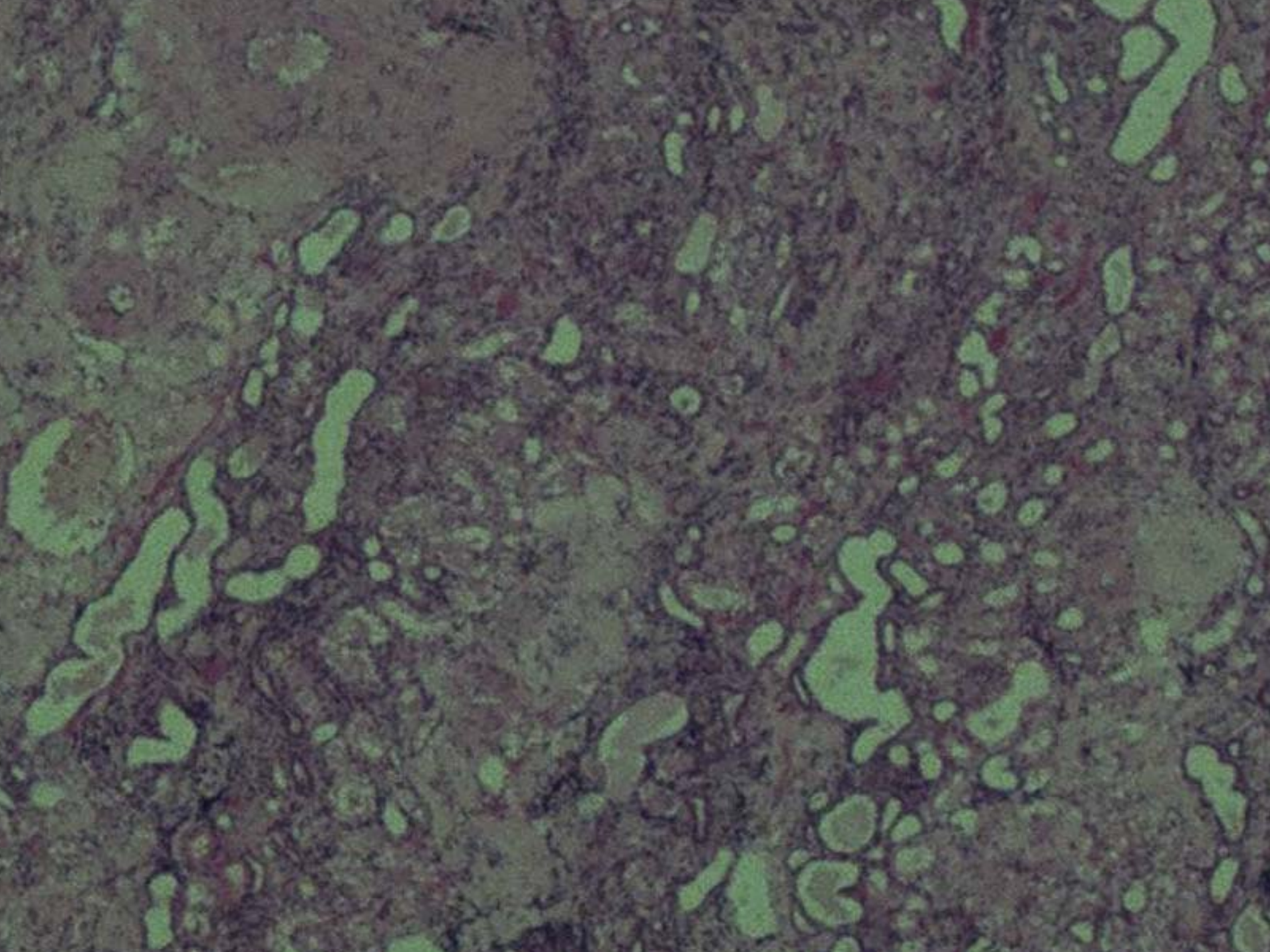
RENAL DISEASE

- **Not prevalent as hepatic disease**
- **Kidney enzymes**
 - **BUN values reach tremendous levels**
 - **Creatinine values - low to normal range**
- **Often no history of PPU/PD**
- **Often do not vomit**

RENAL FAILURE?

- Use urine specific gravity
- Serum phosphorous
- BUN
- Creatinine
- Symptoms





Miscellaneous

- Pyelonephritis-ascending infections, culture and sensitivity, fluids, antibiotics, force feed
- Grape / Raisin toxicity
- Toxins-lillies(all parts), 3 leaves kill a cat, household chemicals, antifreeze, Advil, zinc, pennies, etc
- Preputial Cysts-usually benign, 8 cases of adenocarcinoma.



Old Bridge
VETERINARY
HOSPITAL
3604



Adrenal Disease

- 2nd most common internal tumor
- LH receptors found in adrenal tissue
- FSH & LH stimulate zona reticularis to produce excess sex steroids

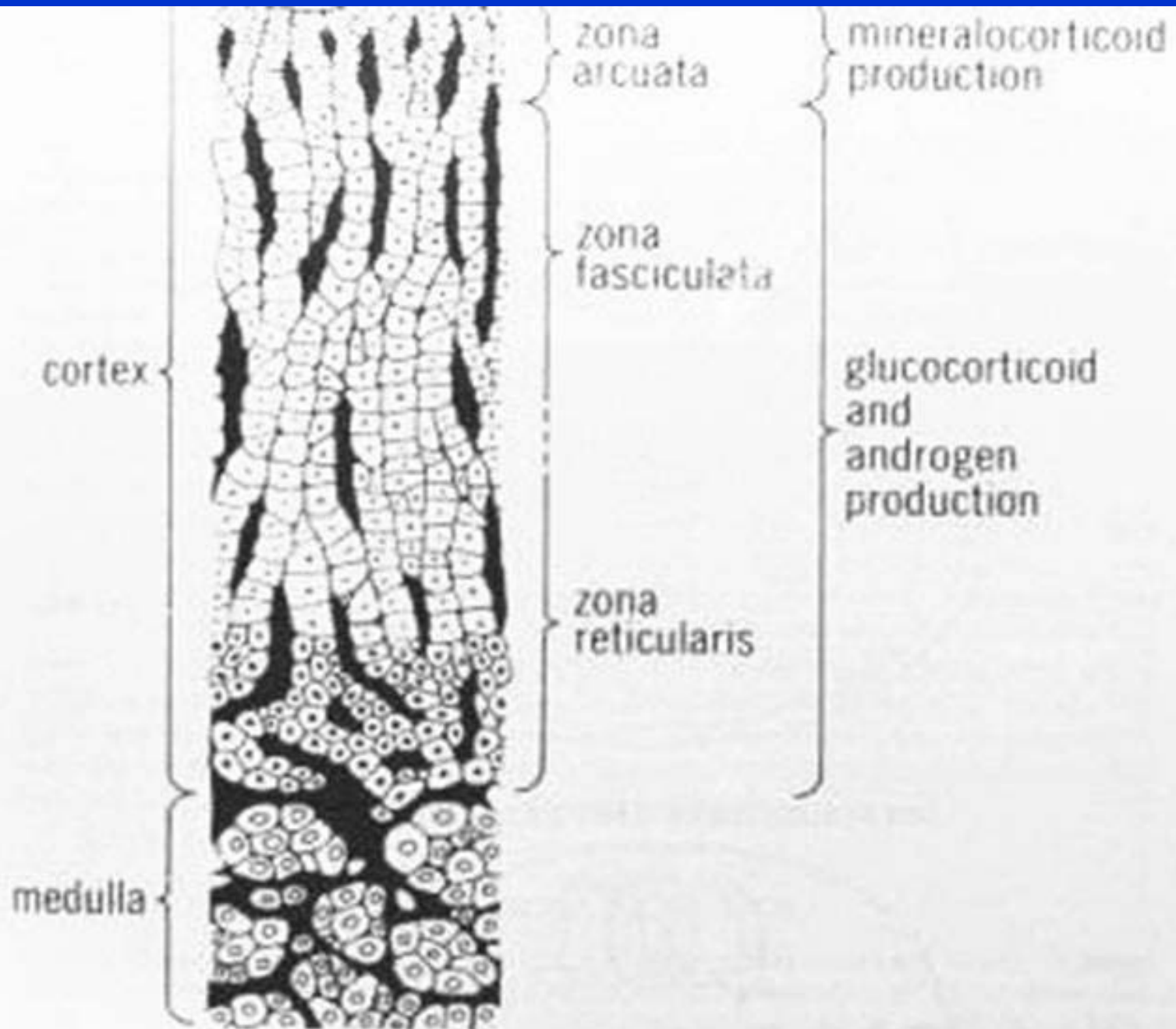


FIG. 17-2. Cross-section of normal canine adrenal gland.

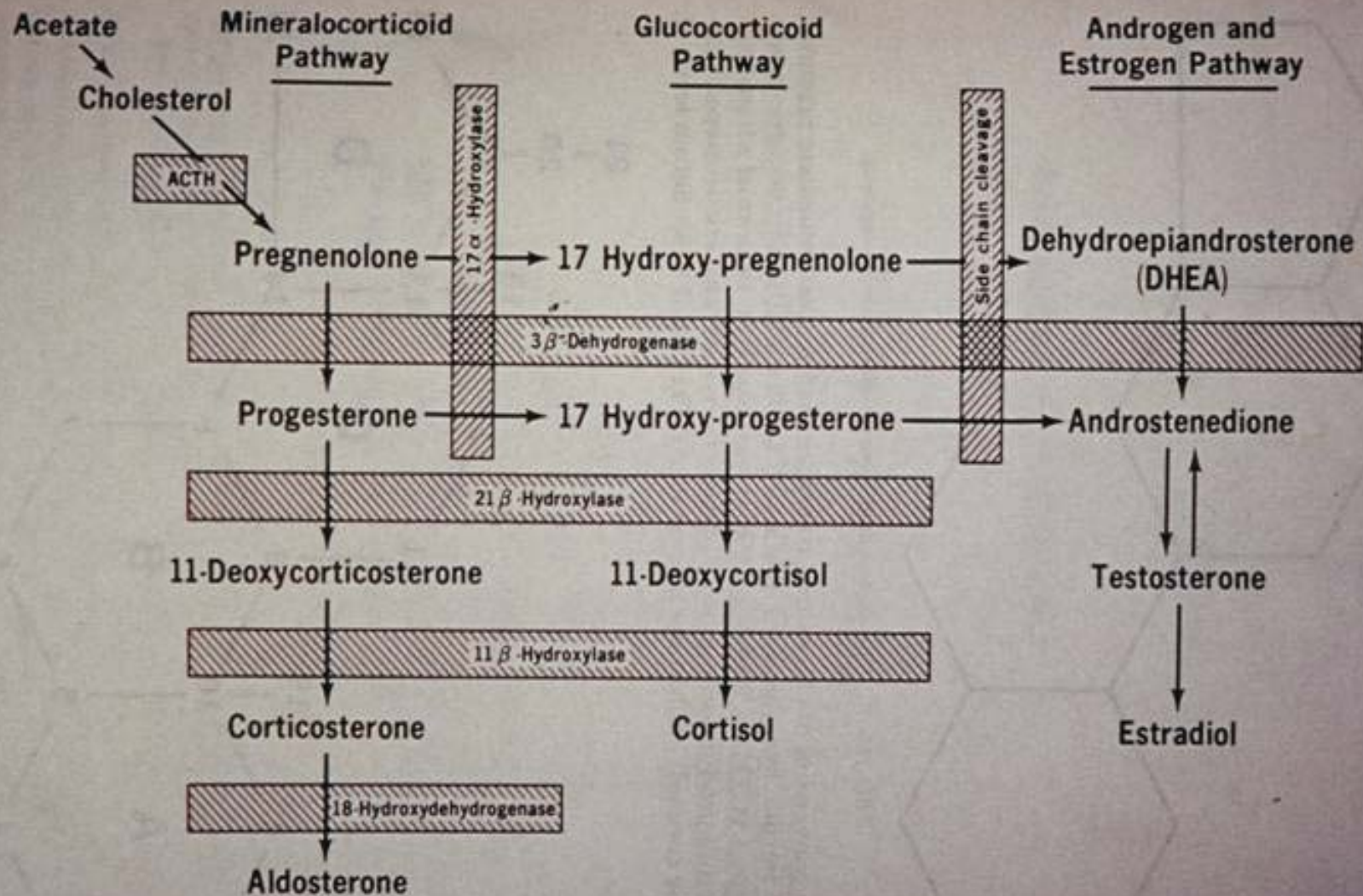


Fig. 17-4. Adrenocortical hormone synthesis.

- Estradiol (72%), 17 hydroxyprogesterone (50%), androstenedione (58%)
- Progesterone, testosterone, cortisone (<1%-4%), DHEAS infrequently increased
- Early neutering → lack of negative feedback of sex hormones → increased GnRH
- Rodent species early neutering leads to adrenal disease

Intact Ferrets

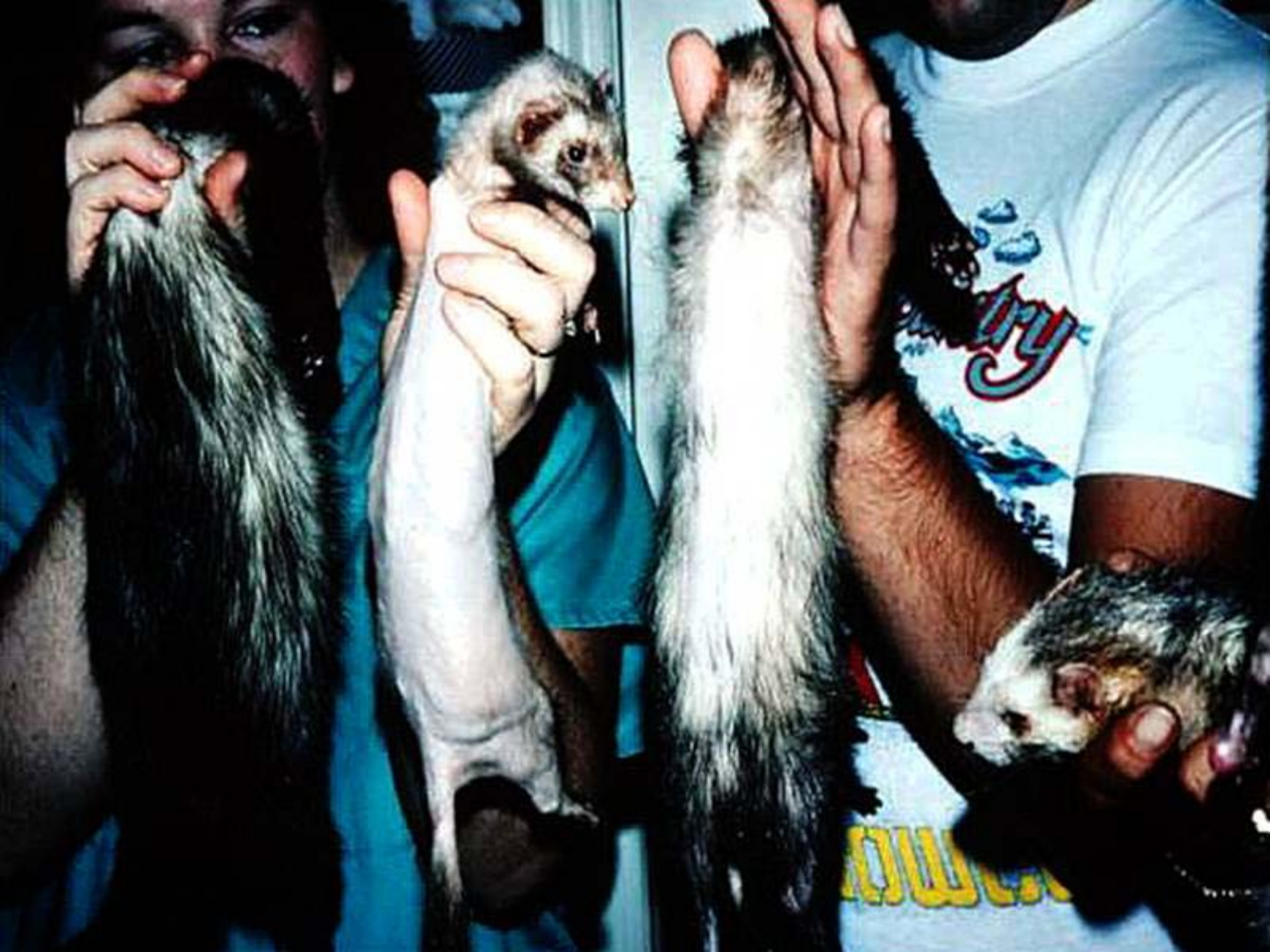- FSH and LH release → sex hormones → decreased GnRH → decreased LH and FSH

Neutered Ferret

- FSH and LH release (lack of hormone feedback) → increased levels of GnRH → increased FSH and LH

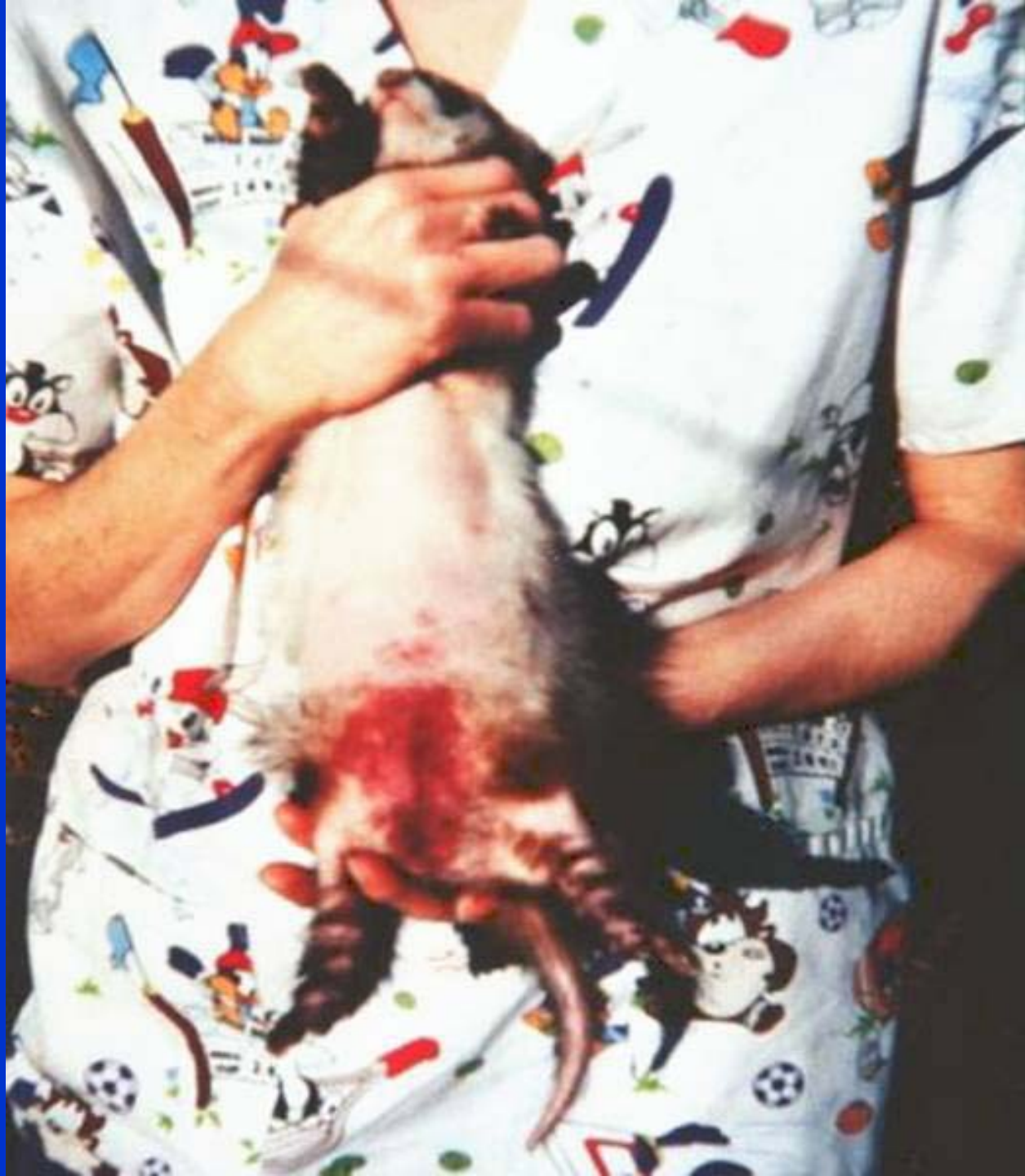Signs

- Alopecia
 -
 - Pruritis
 - Swollen vulva
 - Return of sex drive
 - Aggression
 - Alopecia on tail only
- .Stranguria
 - .Anemia
 - .Hyperkeratosis
 - .Muscle atrophy
 - . No signs
 - .weight gain









Diagnosis

- Primarily signs
- Wrinkle Test
- University of Tennessee
(joliver@UTK.edu)
- Ultrasound

- **Wrinkle Test**
- **95% moderate to severe alopecia**
- **Signs can initially be intermittent**
- **No good evidence of hypothyroidism**

Treatment-Surgery

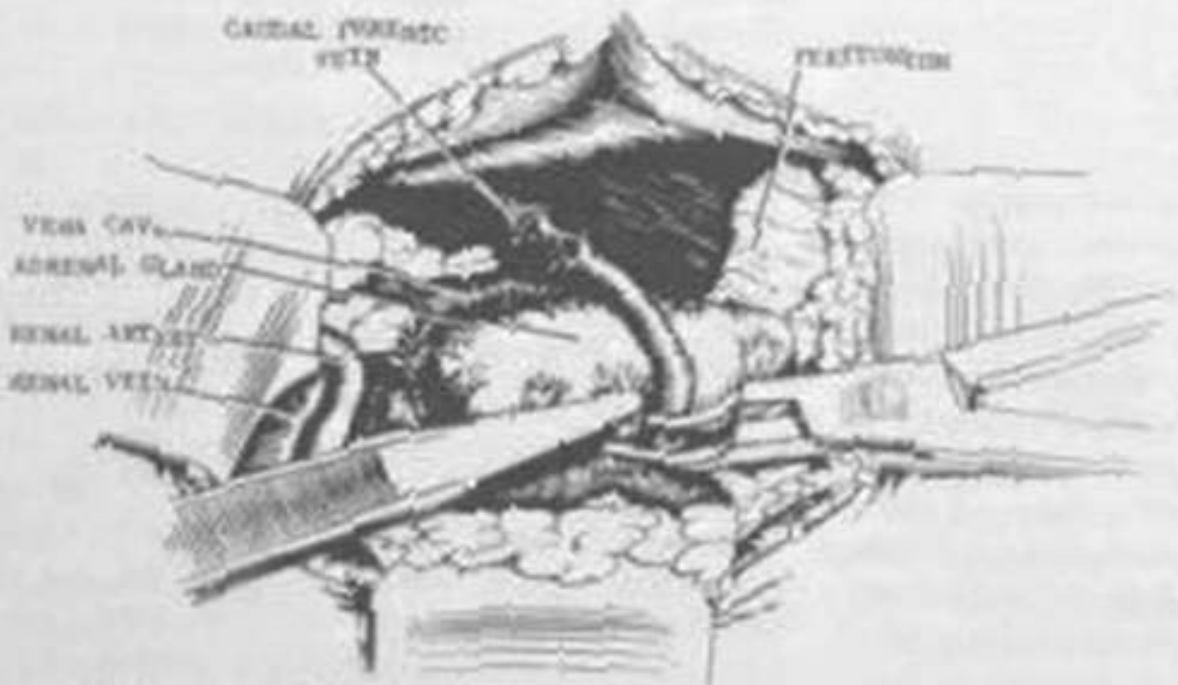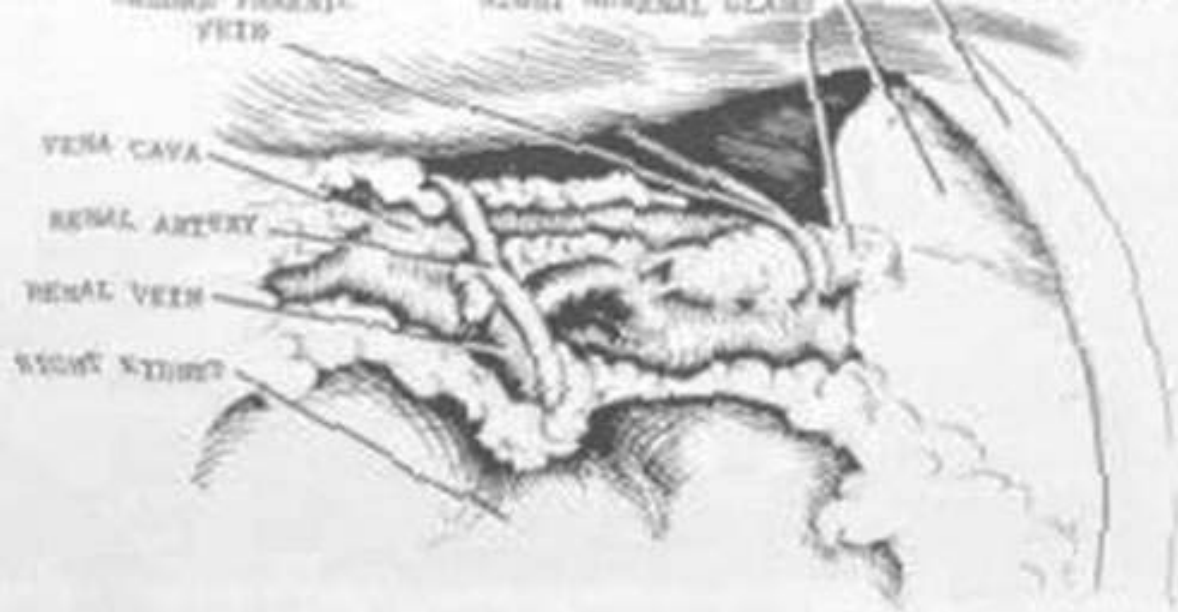- One side theory-selective effect of LH/FSH, some cells get “angry”. Look at size, shape, color-black/grey dots.
- Pretreat with buprenorphine, .03-.05 cc torbutrol, .1 cc DOCP, .05 cc vetalog
- Check pancreas, hairballs
- Cryosurgery right side first-can't damage vena cava

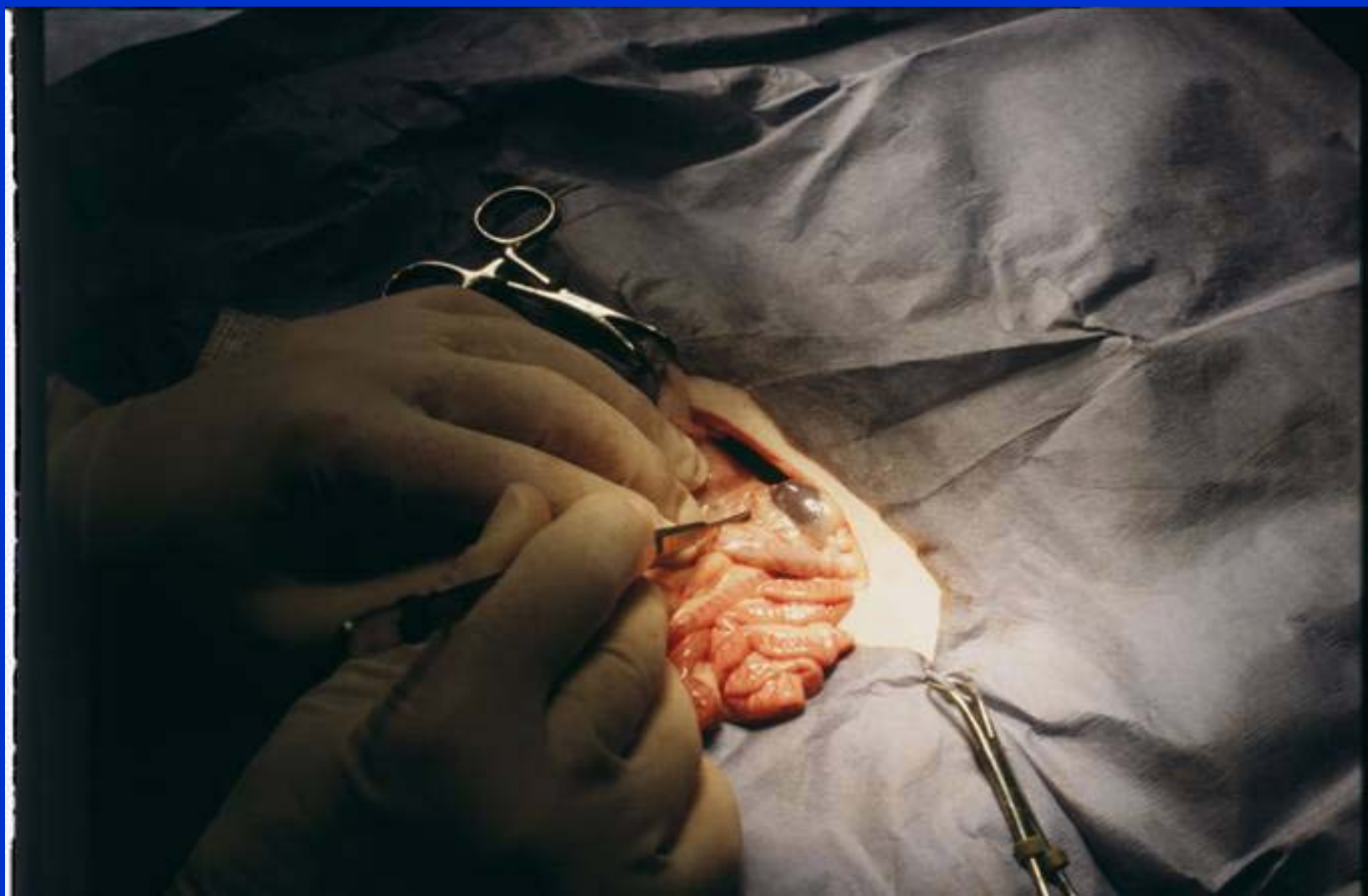Surgery

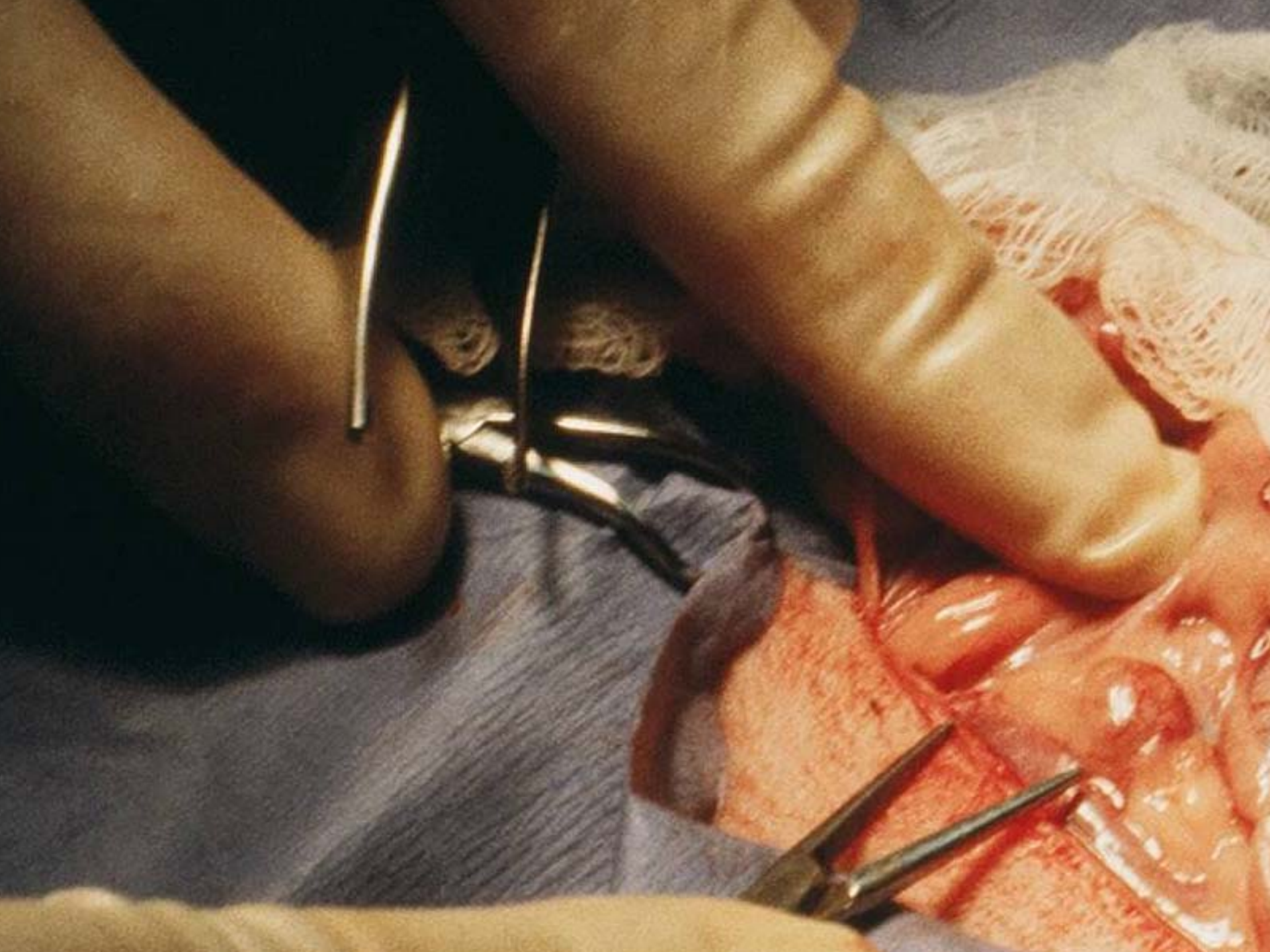
- Remove left side, obese ferrets
- Size of adrenal not correlated with signs

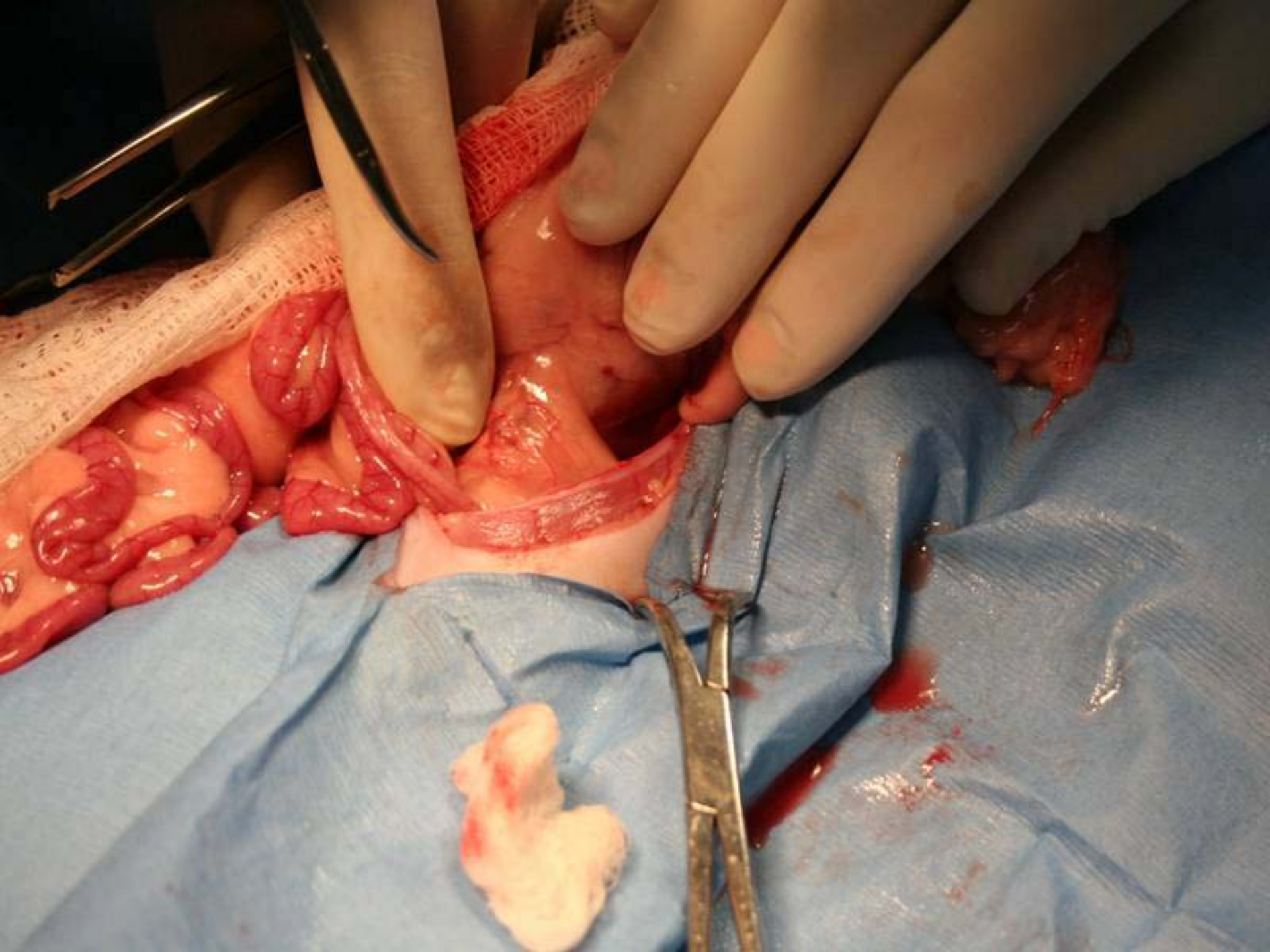
SURGERY

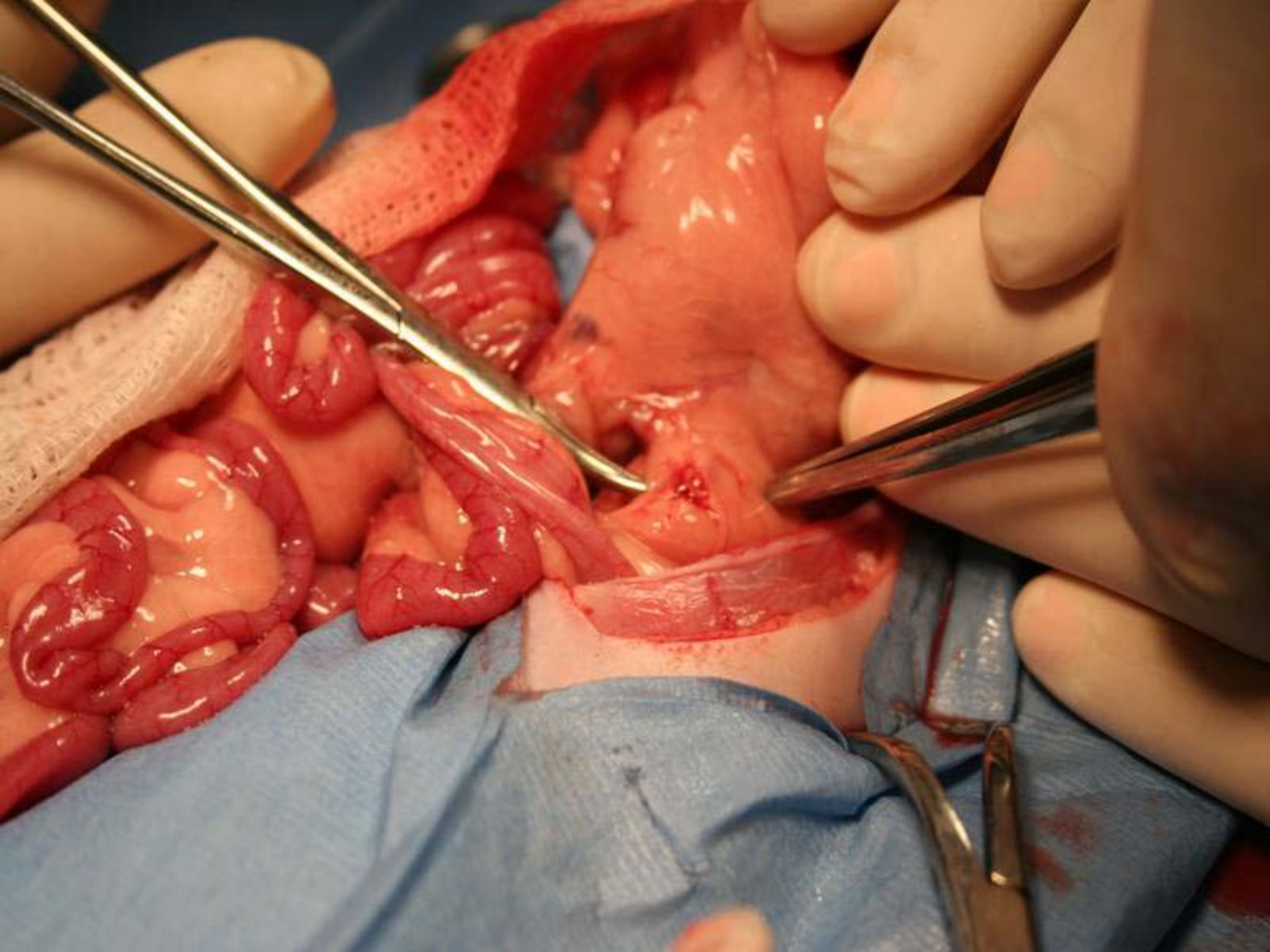
- **Compare size, shape, color, firmness**
- **Dissect away fat**
- **Usually bilateral**
- **Ectopic tissue**

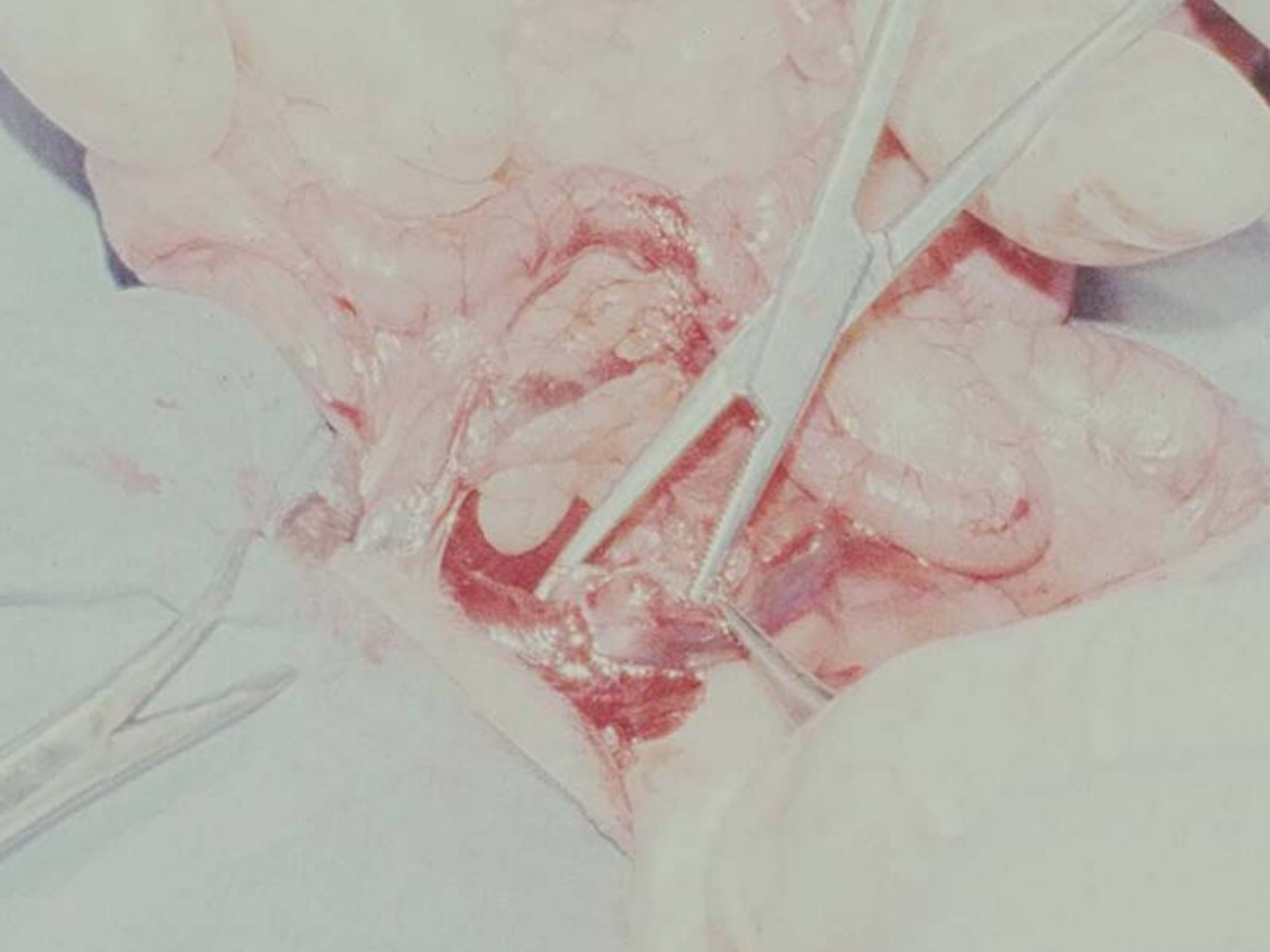


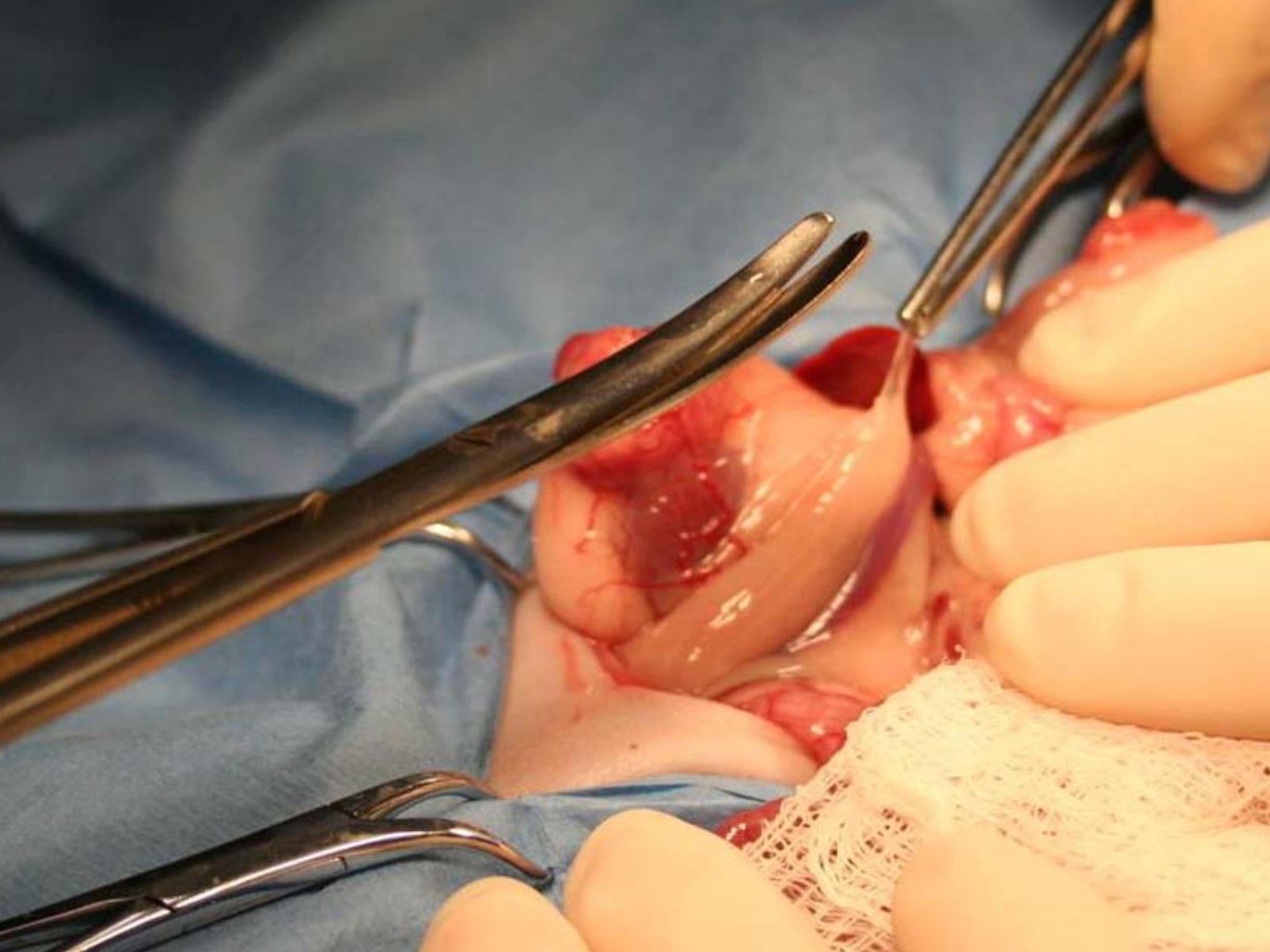

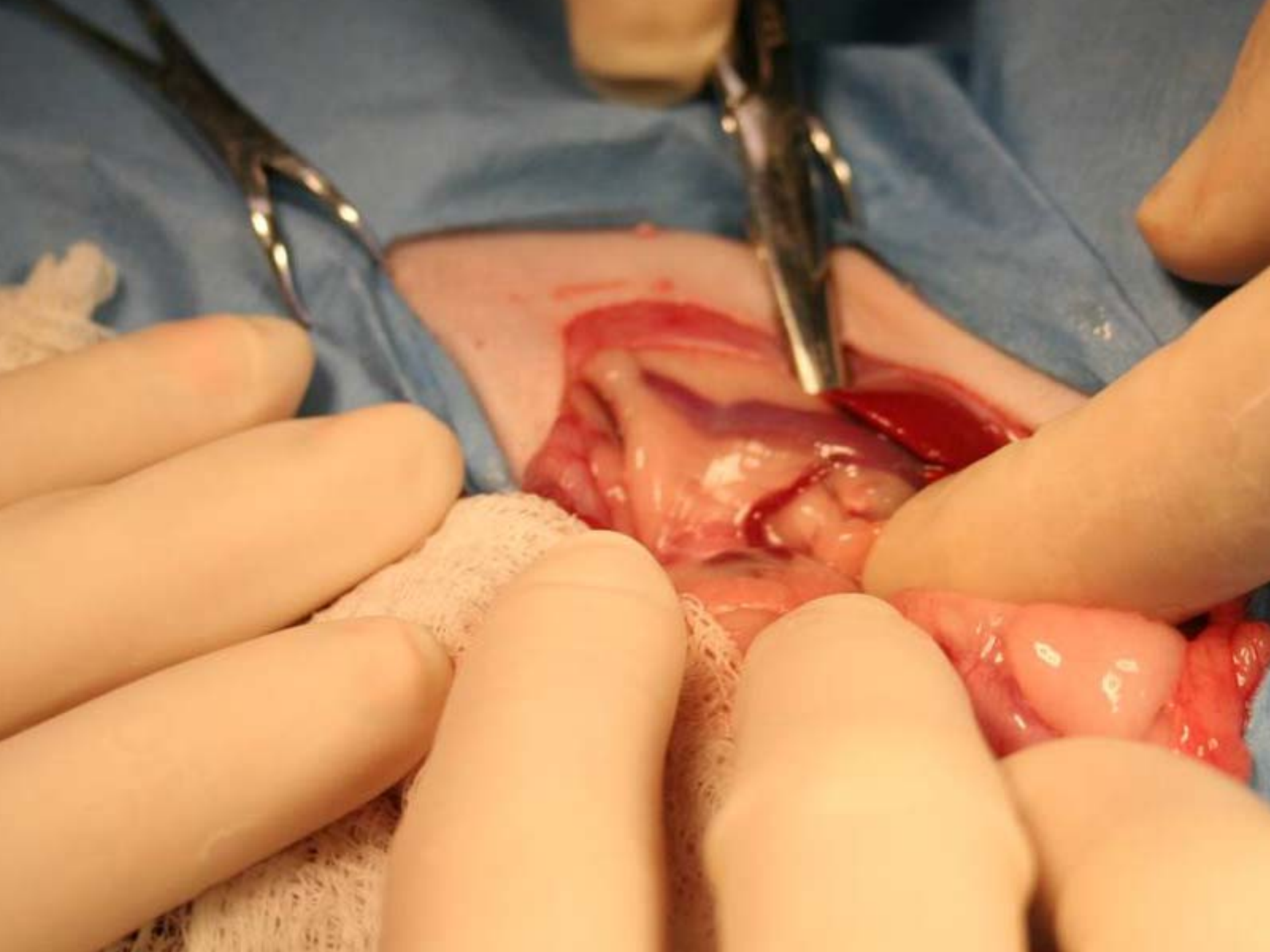


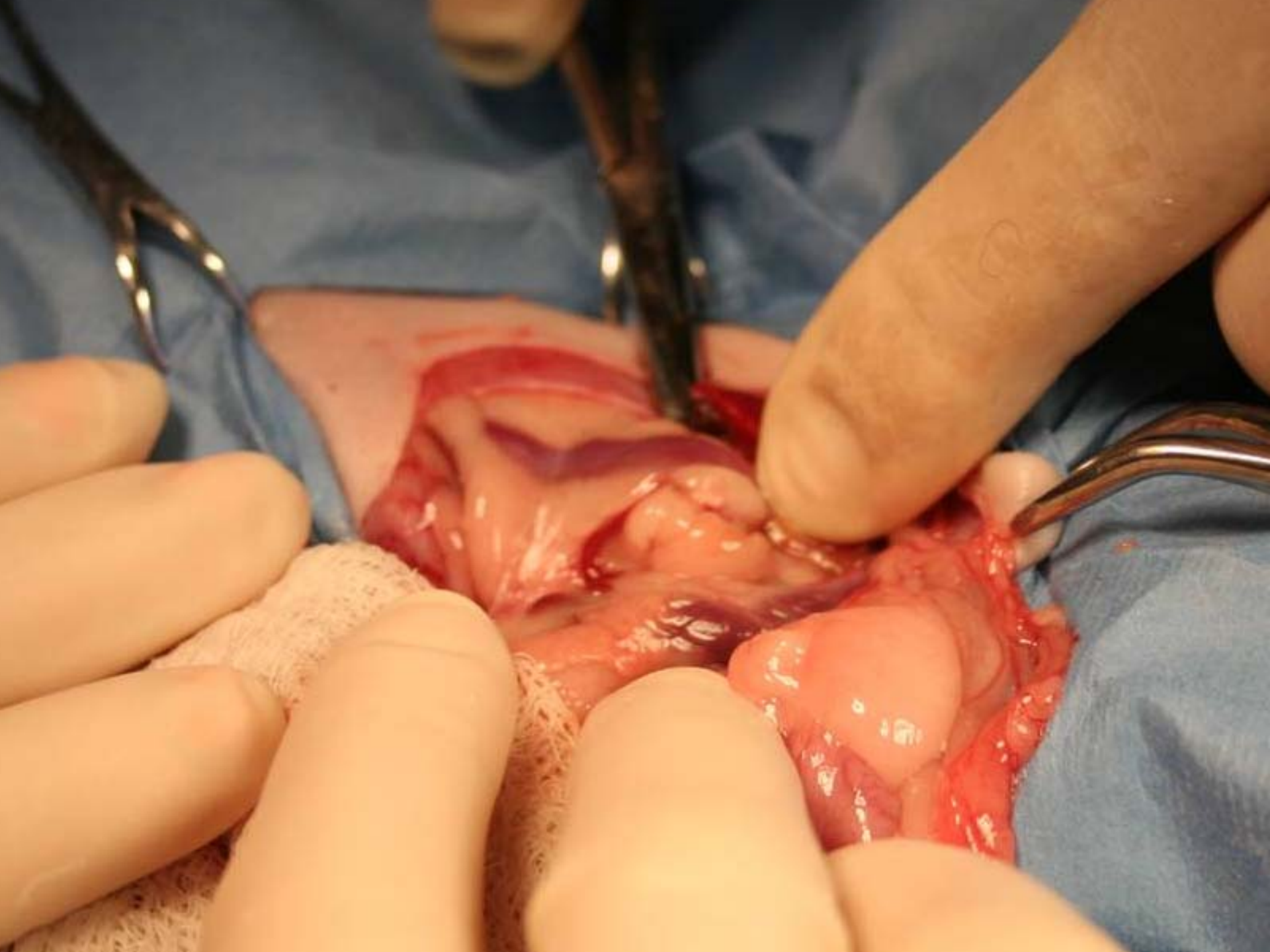



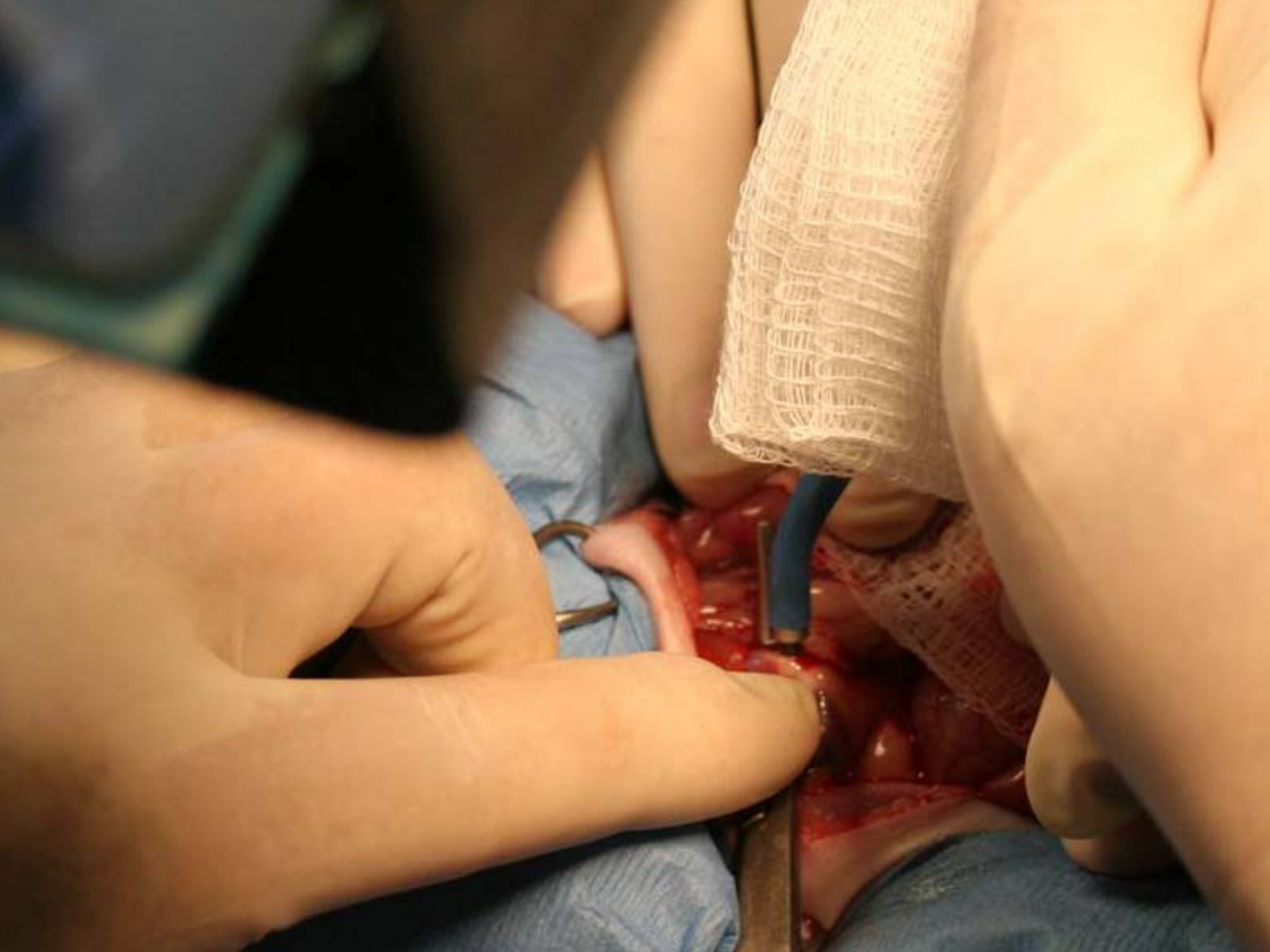


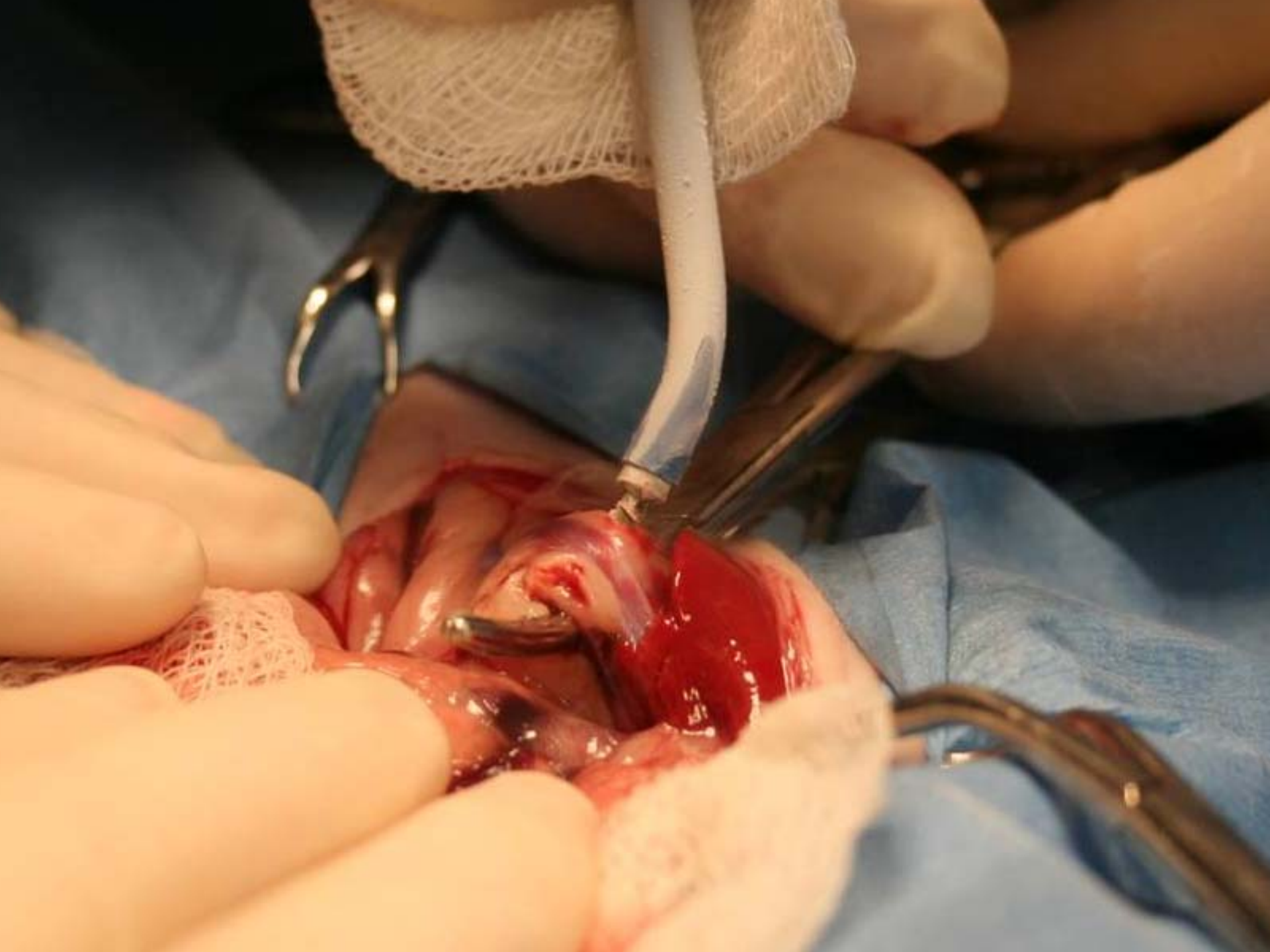


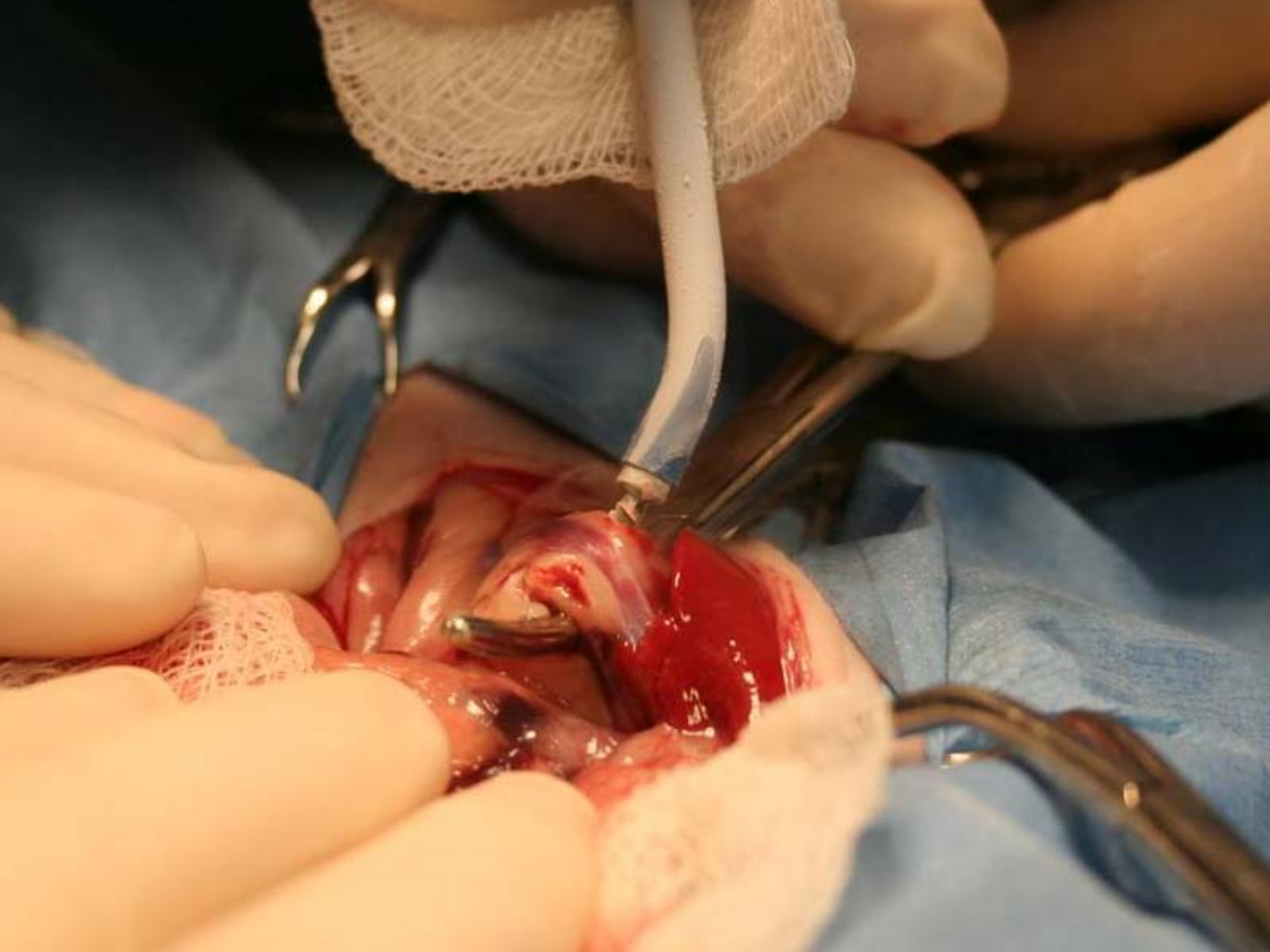


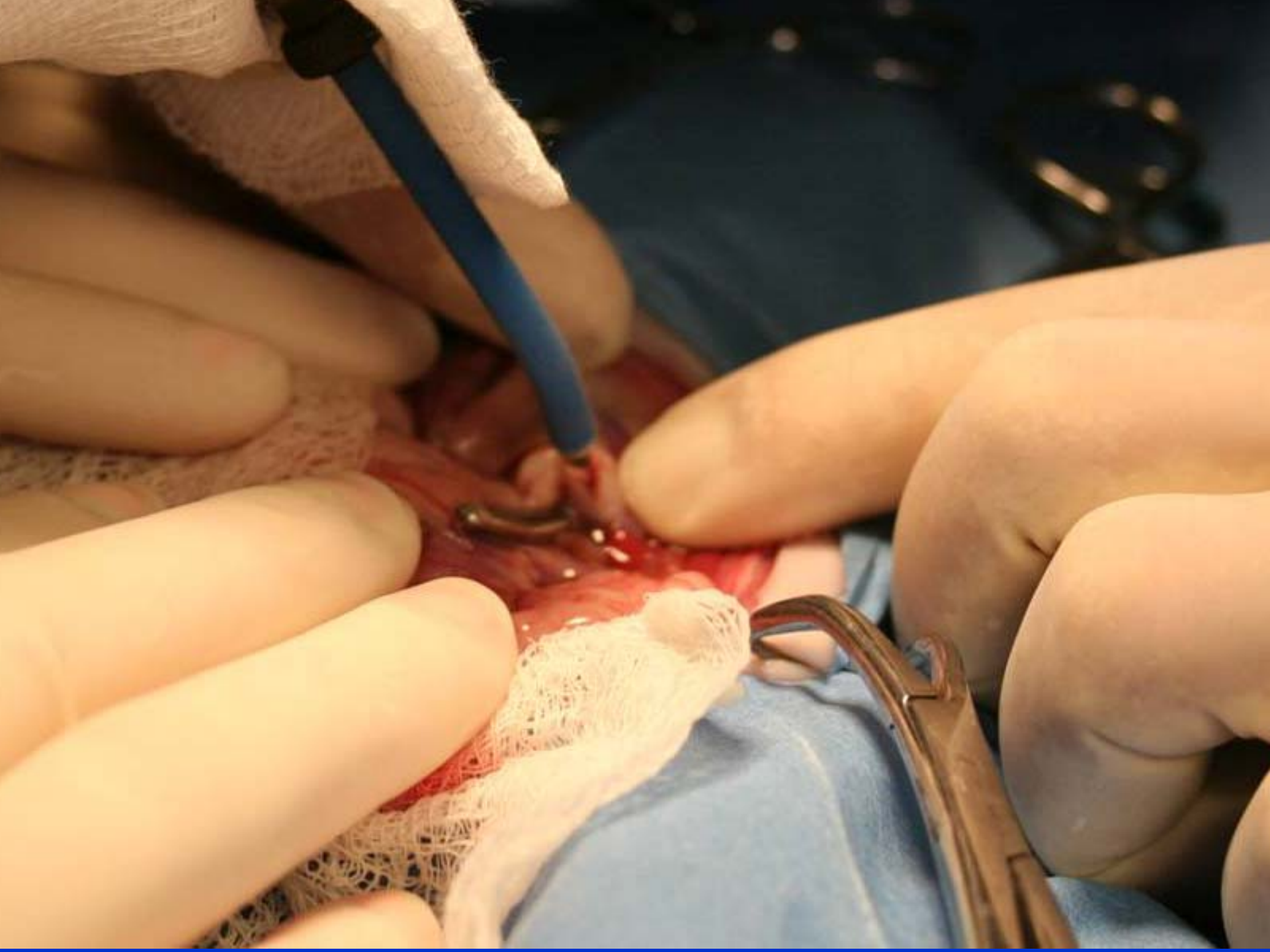

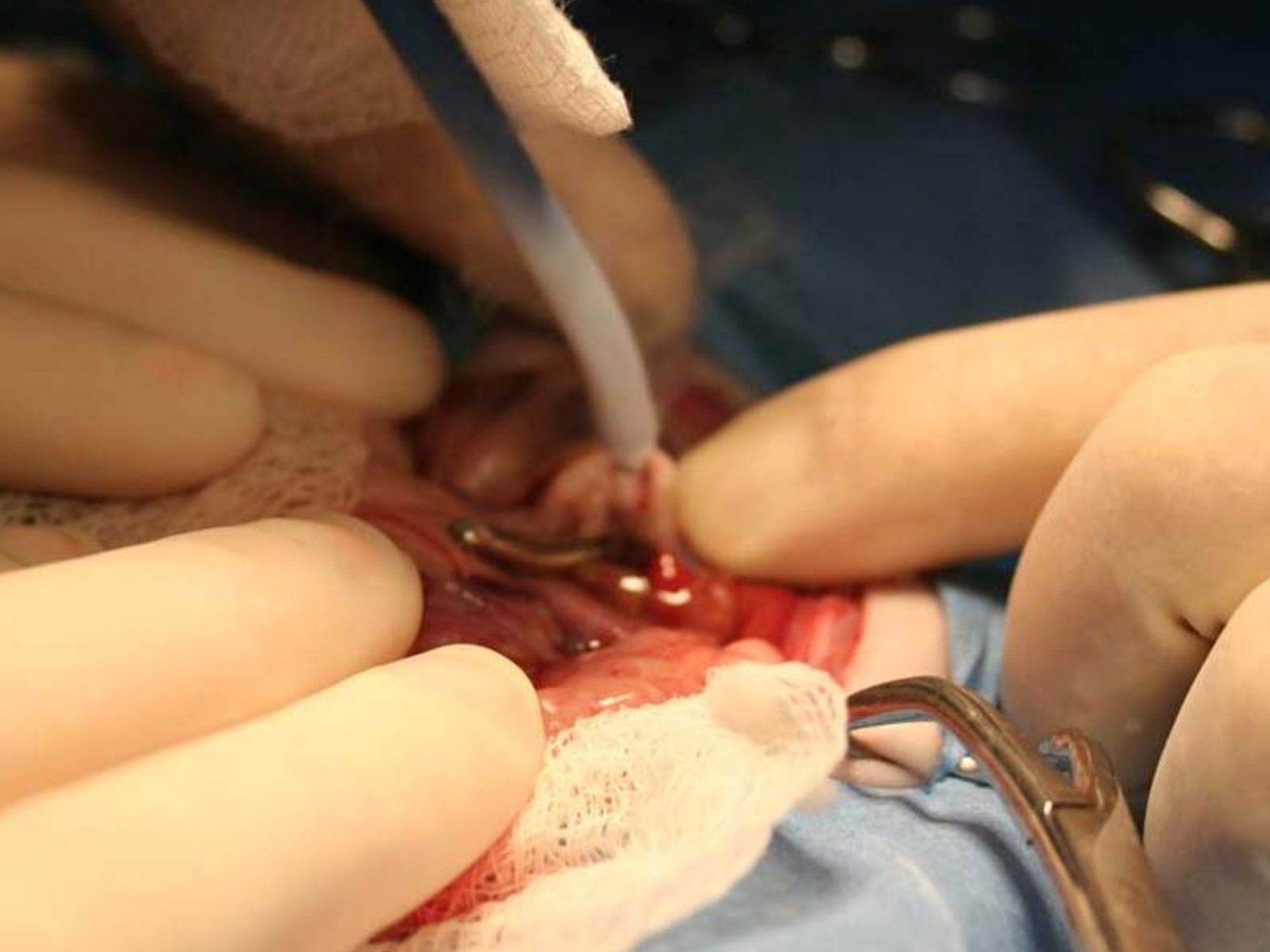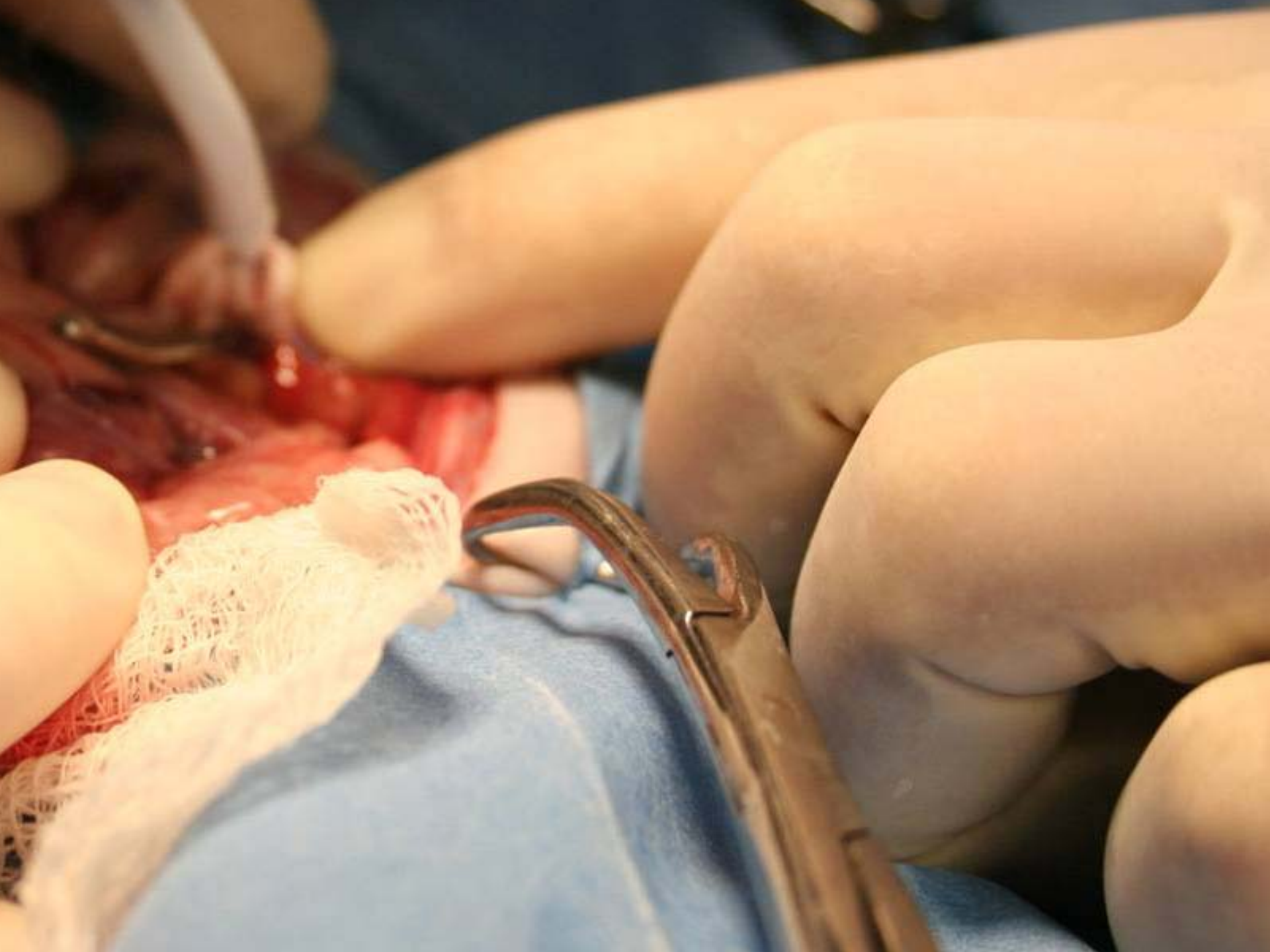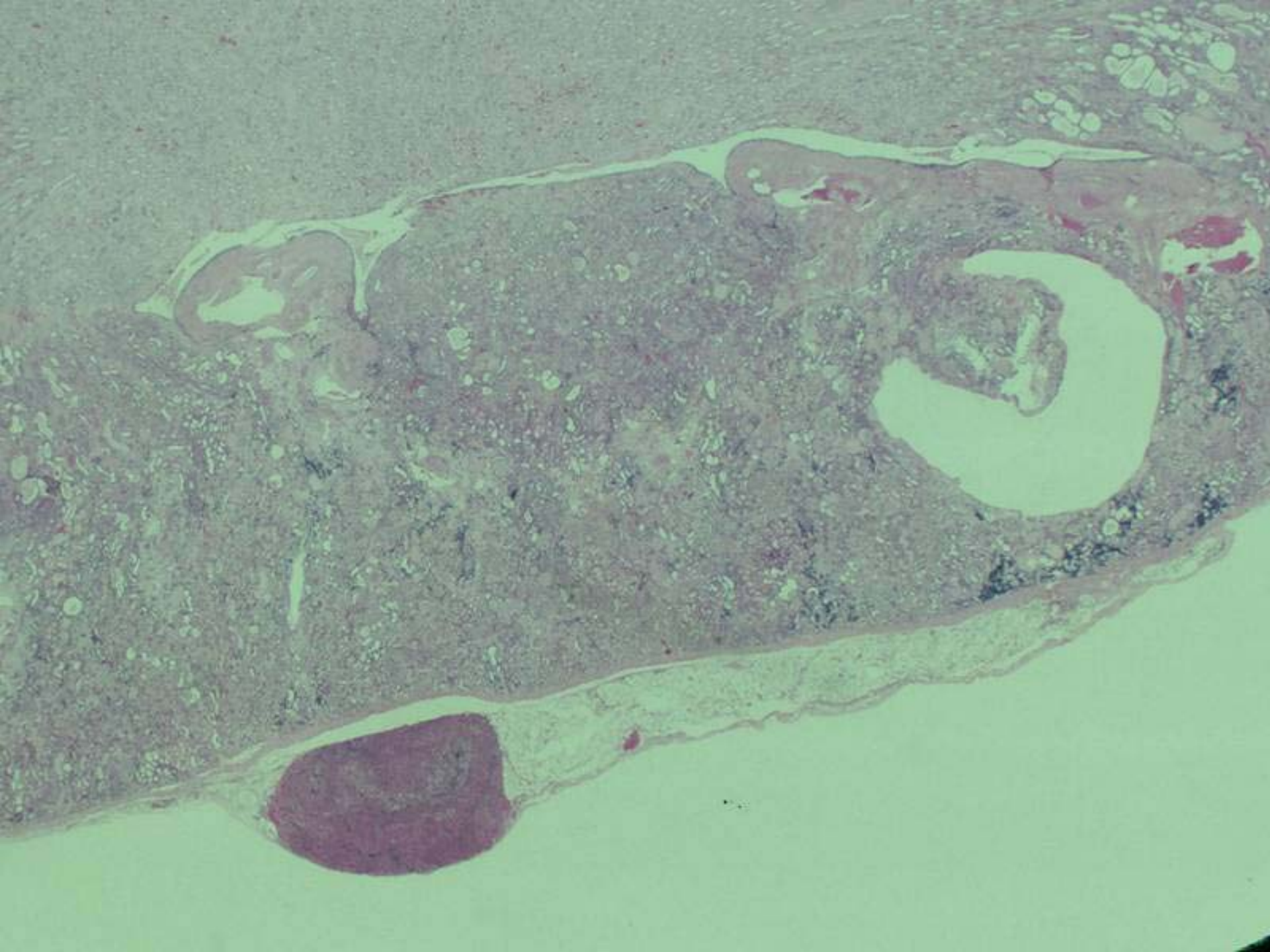









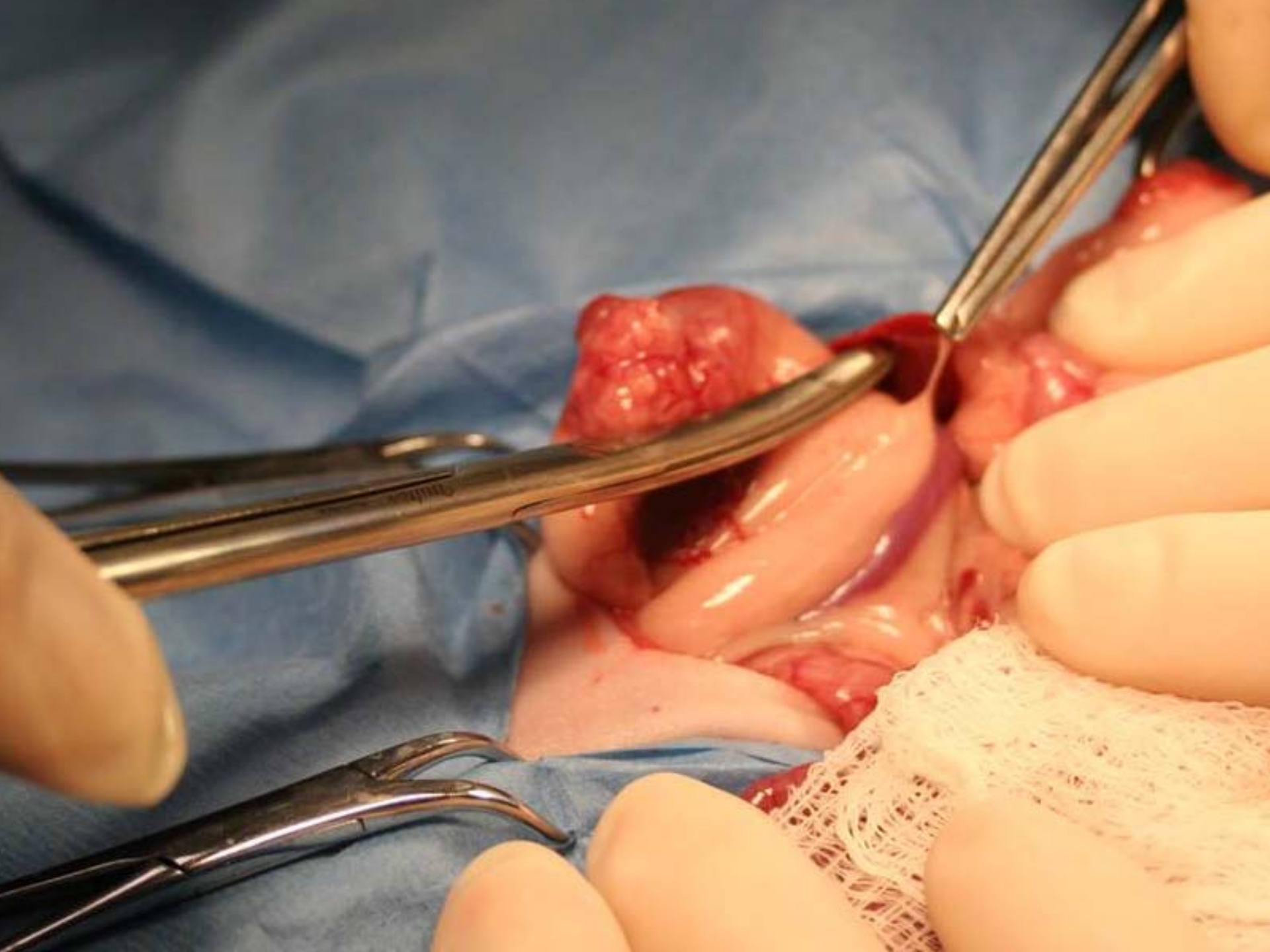




Venal Caval Ligation/Options

- .1 ml ethanol in the gland-symptom free 1 year
- Ligation-acute death in 30-60% of cases due to increased blood pressure.
- Death after 72 hours due to renal failure so push IV fluids
- Satinsky clamp

Postop

- Keep warm . lupron/melatonin
- Eat and drink same day
- Check blood glucose next day
- Check Na/K <27 use .1 cc DOCP once a month or 1/4 florinef tablet SID
- Dispense carafate, pepto, amoxi, metacam
- 30-40% recurrence rate 4 months to 2 years later

Medical Treatment-Lupron

- GnRH superagonist. Why not an antagonist?
 - . 80% response rate to 100 mcg
- Increased GnRH → increased adrenal cortical stimulation
- Lupron → large release of FSH and LH, then desensitization

Medical Treatment-Lupron

- Long term lupron downregulates GnRH receptor expression → decreased LH and FSH
- 1 month (100 ug/kg) and 4 month (220 ug/kg) repositories
- Tumor continues to grow
- May need higher doses after repeated injections due to resistance

Medical Treatment-Melatonin

- Pineal gland, light cycles influence secretion
- >8 hours light exposure → decreased melatonin → increased GnRH → increased FSH and LH → increased sex hormones
- Melatonin inhibits GnRH release → decreased sex hormones
- Increases hair growth, increased vigor, decreases vulva size, decreases prostate, decreases pruritis

Medical Treatment-Melatonin

- No deleterious effects
- Decreases estrogen levels (for 12 months)
- Other hormones unaffected
- Tumor continues to grow
- Rice sized silicone implant, 5.4 mg,
www.melatek.net, 1-877-Melatek
- 1 mg capsule daily 8-9 hours after sunrise
- Limit light to < 8 hours per day

Prostate Disease/BM Suppression

- Flutamide 10 mg/kg PO inhibits androgen uptake and binding in target tissues
- Casodex 5 mg/kg androgen receptor blocker
- Arimadex antiestrogen 0.1 mg SID
- Procrit 200 units/kg 3 times a week



Insulinoma

- Inappropriate insulin secretion secondary to beta cell tumors
- Etiology– Diet or Genetics?
- European polecat primarily eats rodents-55% protein, 38% fat, 1.2% COH
- Cat, kitten, many ferret foods 36% protein, 18-20% fat, 20-30% COH
- Low COH diets include Purina DM, Hills m/d, Pretty Pets Natural Gold for ferrets, Evo

- Chronic demand for insulin → hyperplasia → adenoma → adenocarcinoma

Signs

- Early weakness, lethargy, ataxia, posterior paresis, exercise intolerance
- Intermediate-star gazing, ptyalism, pawing at mouth
- Sever-stupor, seizures, coma
- Rate of decline important for signs
- Fasting and exercising may exacerbate signs

Differentials

- Lymphoma
- Gi foreign body
- Anemia
- Cardiac disease
- Spinal cord compression/organ disease

Diagnosis

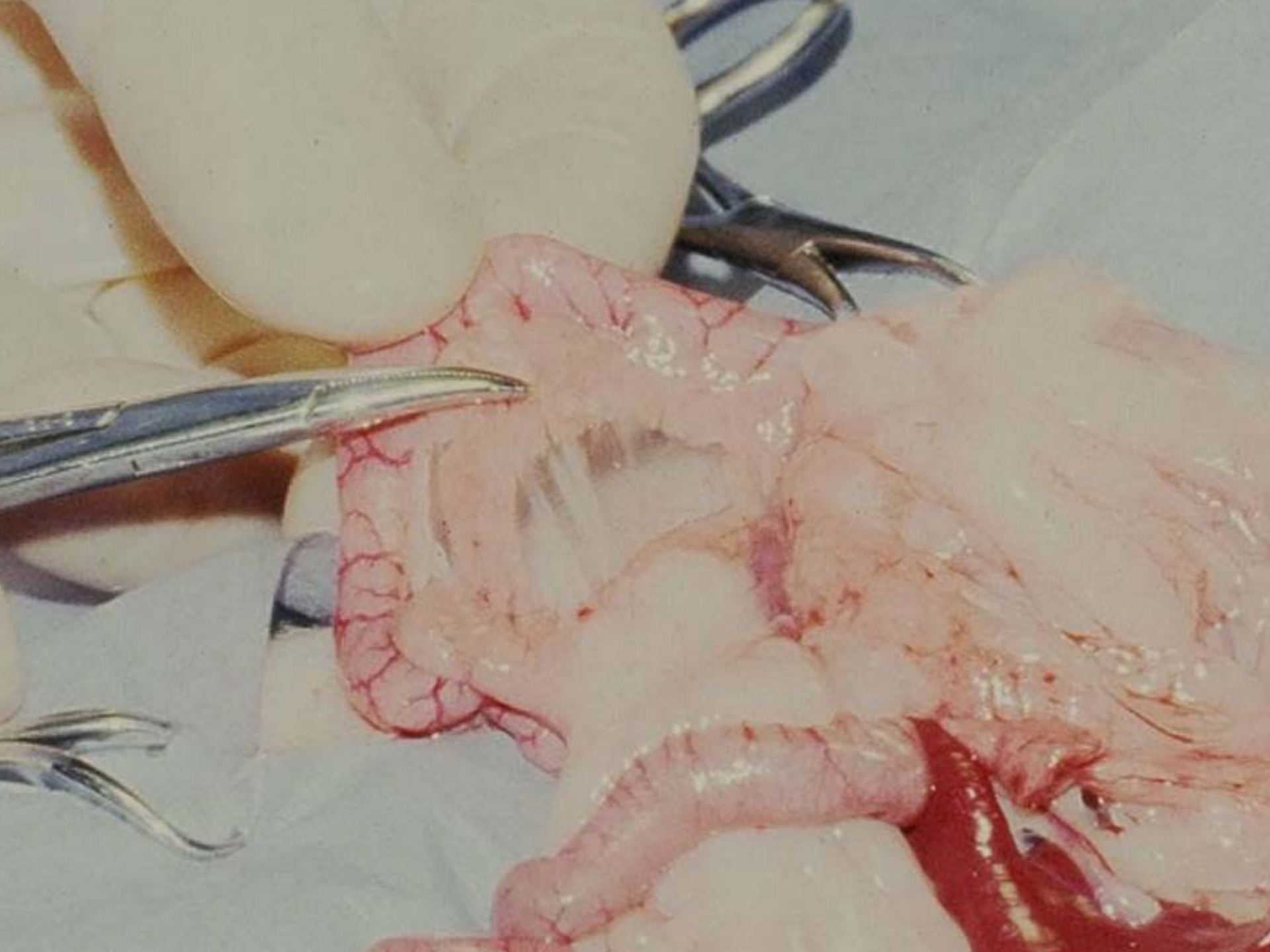
- ****Correct signs and fasting glucose < 75 mg/dl ***
- Single insulin levels are expensive and maybe misleading
- Can obtain insulin level when glucose <75 mg/dl
- Repeat fasting glucose every 1-2 hours
- Check carrier for food

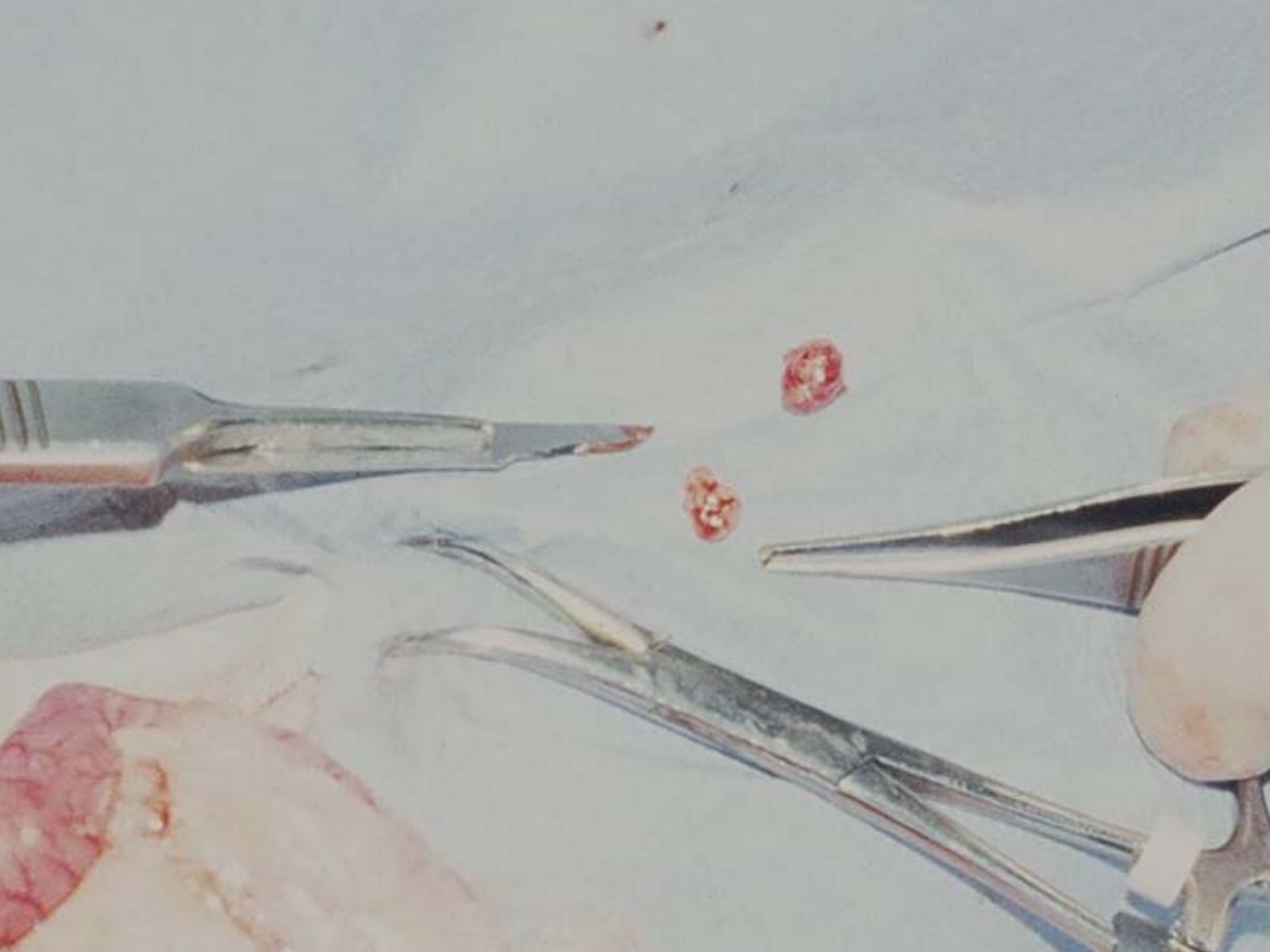
HYPOGLYCEMIA

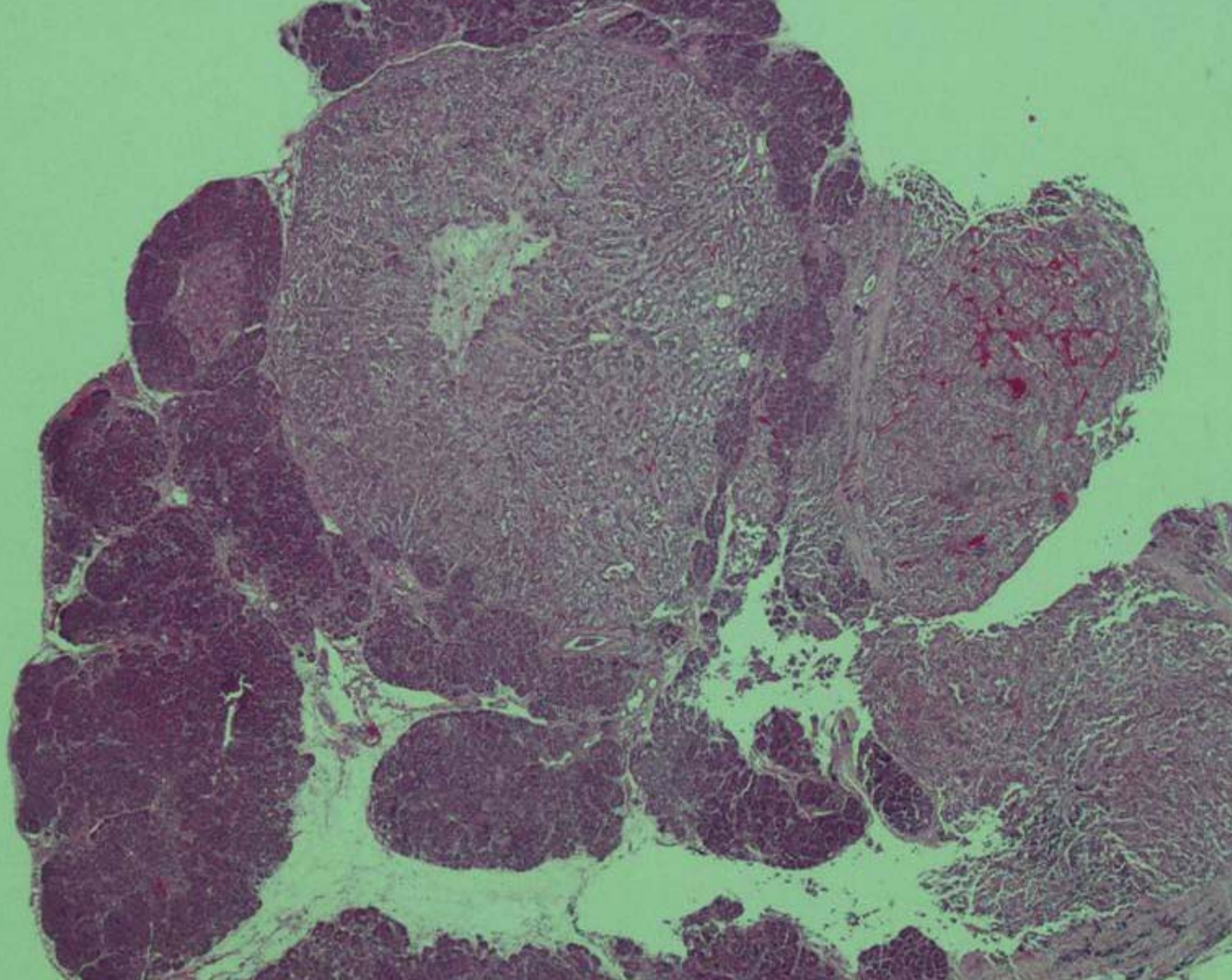
- common, intermittent
- symptoms - lethargy, weakness, disoriented, panicky, hypersalivation, pawing at mouth;
if severe - seizures/coma
- diagnosis
 - symptoms and glucose < 75 mg/dl
 - symptoms, concomitant insulin and glucose levels, fasting
 - AIGR insulin x 100, normal < 350 pmol/liter
glucose - 30
7.75 x micro units/ml = pmol/l
 - perform serum chemistries - liver (40% hepatitis cases hypoglycemic) glucose < 10-74 mg/dl

Treatment-Surgical

- Much preferred if patient is under 7 years
- Technically easy
- Partial pancreatectomy if 2 or less nodules
- Measure glucose 24 hours and 10 days post op, then every 4 months
- Diabetes-use .1 U nit Ultralente SID, PZI, most resolve in 1-2 weeks







Treatment-Medical

- Glucocorticoids-.5-2.0 mg/kg up to BID
- Diazoxide 5-20 mg SID to TID; side effects uncommon include gi irritation, possible cataracts, bm suppression, aplastic anemia
- Diet continuously available, high protein, avoid sugars



FIP Type Cases

- New emerging disease
- Lethargy, pyrexia, weight loss
- Globulins >8.0 mg/dl
- Aleutians negative
- IHC positive for FIP, Dr Kuipel 517-432-2670
- Similar to the dry form-little fluid
- Twelve cases as of Jan 1st: ECE offshoot?

Disseminated Idiopathic Myositis

- First seen in 1999
- 100 cases as of Jan 2007
- <18 months of age
- Likely an acquired immunomediated disease, perhaps with a genetic predisposition
- Myositis caused by a Dutch vaccine

Signs

- Pyrexia(104-108 F)
- Lethargy
- Paresis
- Lymphadenopathy
- Diarrhea
- Partial anorexia
- Hyperesthesia
- Heart murmurs

Diagnosis

- Mature neutrophilia
- Toxic neutrophils
- Mild to moderate anemia
- Mild increase in ALT
- CK NOT increased
- No bacteria found

Pathology

- Red and white mottling of esophagus
- White streaks in diaphragm, lumbar muscles, leg muscles
- All muscle groups affected; also brain, liver, lung, trachea, spleen, bone marrow, fat

- Myofibers widely seperated by sheets of inflammatory cells
- Esophagus best to biopsy, quadriciceps group
- Multifocal so can miss it
- Dr Katrina Ramsell 503-643-2137